

**Role of Vitamin E in Ameliorating Aluminum Chloride Effects on Prenatal Liver of Full Term Rat Fetuses**Samar M Alsaggaf<sup>1</sup>, Ghada A Abdel-Hamid<sup>1\*</sup>, Magda M Hagra<sup>3</sup>, Hamid A Saleh<sup>1</sup> and Mohamed E Selim<sup>2</sup><sup>1</sup>Anatomy Department, Faculty of Medicine, King Abdulaziz University, Saudi Arabia<sup>2</sup>Faculty of Medicine in Rabigh, King Abdulaziz University, Saudi Arabia<sup>3</sup>Pharmacology Department, Faculty of Medicine, Suez Canal University, EgyptE-mails: [ghada169@hotmail.com](mailto:ghada169@hotmail.com), [gmohamed@kau.edu.sa](mailto:gmohamed@kau.edu.sa)

**Abstract:** To investigate the histological and biochemical changes of fetal liver induced by aluminum chloride and the role of vitamin E in alleviating the harmful effects of aluminum. Eighty pregnant female rats were divided into two main groups control (C) and experimental. Each main group was subdivided into two subgroups (20 dams in each). Control was subdivided into: negative untreated (C) and positive control (C + VE, 100 mg VE/kg BW/day). Experimental group was subdivided into: (AL) (150 mg /kg BW/ day) and (AL) + VE (100 mg VE/kg BW/day). All test drugs were administered through intragastric tube from first day of gestation to the 20<sup>th</sup> day. Fetal liver weight and all growth parameters were measured. Sections of paraffin-embedded rat fetal liver were prepared and stained with hematoxylin and eosin, PAS, and Masson trichrome. Another part of rat fetal liver was assayed for lipid peroxidation enzymes, thiobarbituric acid-reactive substances and glutathione S-transferase. Oral aluminum chloride administration during pregnancy resulted in significant decrease in all growth parameters of rat fetuses, reduced fetal liver weight, a significant decrease in glutathione S-transferase and an increase in thiobarbituric acid-reactive substances. A disruption, vacuolation and degeneration of hepatocytes were observed with an increase in collagen and reduction in glycogen content. Vitamin E was able to reduce histological and biochemical changes induced by aluminum chloride. In conclusion, oral aluminum chloride induced harmful effects on rat fetal liver whereas; vitamin E was able to ameliorate these effects.

[Samar M Alsaggaf, Ghada A Abdel-Hamid, Magda M Hagra, Hamid A Saleh and Mohamed E Selim. **Role of Vitamin E in Ameliorating Aluminium Chloride Effects on Prenatal Liver of Full Term Rat Fetuses.** *Life Sci J* 2016;13(9):1-8]. ISSN: 1097-8135 (Print) / ISSN: 2372-613X (Online). <http://www.lifesciencesite.com>. 1. doi:[10.7537/marslsj130916.01](https://doi.org/10.7537/marslsj130916.01).

**Key words:** Aluminum, Vitamin E, fetal, liver, teratogenicity

**1. Introduction:**

Aluminum is an essential element with a known toxicity to the human body, mostly in the central nervous system. It has been recognized as a neurotoxin that can cause certain diseases such as Alzheimer disease, dialysis dementia, parkinsonism [1]. Aluminum exposure affected several organs and resulted in changes in skeletal, hemopoietic and respiratory systems and the nervous system [2]. The lethal effects of chronic aluminum exposure may be mediated through changes in the intracellular calcium homeostasis, which resulted in impairment of neuronal function [3].

The gastrointestinal tract usually is a major barrier to aluminum absorption, under some situations this barrier can be broken. Therefore, individuals ingesting large amounts of aluminum compounds do absorb a definite amount of aluminum [4]. The liver is the largest gland of the body that breaks down nutrients and drugs into simple forms to use for the parts of the body. Oral ingestion of aluminium chloride in adult male rat leads to congestion of central vein and distortion of liver sinusoids [5].

Pregnant women frequently exposed to aluminum as they used antacid drugs, as well as food

additives, toothpaste, and some cosmetics, which contain aluminum [6]. Many toxic compounds are tolerable in definite concentrations in adults are damaging for fetuses [7]. Previous studies revealed the toxic effects of different concentrations of aluminum on fetus and document transplacental passages of aluminum from pregnant rat to fetuses [8]. So, disagreement on its toxic effects remains as some studies fail to document embryotoxic effects for aluminum [9].

Lately ingestion of antioxidants such as vitamins has increased day after day. Vitamin E is an antioxidant and is predicted to protect tissues from injury initiated by reactive oxygen metabolites [10]. Vitamin E has valuable properties and may be able to antagonize aluminum toxicity [11]. Previous studies investigated the toxic effects of aluminum -containing matters in adult animal models [9,11,12], little attention to prenatal effect of aluminum on rat's fetuses. So, this study was aimed to investigate the efficacy of Vitamin E in improving the aluminum - induced toxicity on liver of full term rat fetuses.

## 2. Material and Methods:

### Animals and study design

Eighty virgin albino rats weighing between 150-200 g were obtained from animal house in King Fahd Medical Research Center, Jeddah, Saudi Arabia. The experiment was directed in accordance with the ethical rules and guidelines of the Canadian Council on Animal Care. The animals were kept in stainless steel cages and kept on a 12-hour light-dark cycle and room temperature of  $27^{\circ}\text{C} \pm 1^{\circ}\text{C}$  under hygienic environments. Food and water were provided *ad libitum*. Rats were randomly distributed into two groups: Control (n=40) and experimental (n=40) groups. Control group was further divided into negative control group which received distilled water, and positive control group that received VE (100 mg/kg/day) for three months through intragastric tube [13]. This study was permitted by the biomedical research ethics committee, Faculty of Medicine, King Abdulaziz University, Jeddah, Saudi Arabia.

The experimental group was further divided into two subgroups: the first group received orally aluminium chloride ( $\text{AlCl}_3$ ) (150mg/kg BW/day) [9] for three months through intragastric tube and the second one received the same dose of  $\text{AlCl}_3$  plus VE (100 mg/kg/day) for three months.  $\text{AlCl}_3$  and VE used in this study were purchased from Aldrich Chemical Company (Milwaukee, MN, USA).

### Induction of pregnancy

Two females from each group are put with one fertile male albino rat into a cage and left overnight. Pregnancy was confirmed by the presence of spermatozoa in the vaginal smear next morning and this was the first day of gestation [14].  $\text{AlCl}_3$  and VE were given at the same doses as before pregnancy to the pregnant rats through intragastric tube during the whole duration of the pregnancy. Negative control group was given saline at the same time through intragastric tube during the whole duration of the pregnancy.

### Histological methods

At the time of gestational day 20 pregnant rats were sacrificed. The abdomen was opened to dissect the uterine horns to extract fetuses which weighted and their liver were extracted, weighted then part of it was fixed in 10% formalin and proceeded for paraffin blocks. Paraffin sections 5  $\mu\text{m}$  thick were stained with hematoxyline and eosin (H&E) for routine histological examination, Masson trichrome method for visualization of connective tissue and periodic acid Schiff (PAS) [15].

### Biochemical methods

The other part of fetal liver was stored at  $-80^{\circ}\text{C}$  until time of evaluation of lipid peroxidation, enzyme activities and biochemical parameters such as free radicals (thiobarbituric acid-reactive substances)

according to Tappel, Zalkin [16], and glutathione S-transferase (GST) according to Habig *et al.* [17]. Fetal liver was minced and homogenized (10% w/v) separately in ice-cold 1.15% KCl—0.01mol/l sodium, potassium phosphate buffer (pH 7.4) in a Potter-Elvehjem type homogenizer. The homogenate was centrifuged at 10,000 g for 20 min at  $4^{\circ}\text{C}$ , and the resultant supernatant was used for different enzyme assays.

### Statistical analysis

The values of fetal weight, liver weight, crown rump length, biparietal diameter and head length were measured for each rat, and calculate the mean and standard deviation for all rats in each group. Differences between groups was analyzed using one way ANOVA ( $P < 0.05$  considered significant).

## 3. Results:

### I. Morphological findings:

No growth congenital anomalies were found in rats fetuses in all groups. Prenatal oral ingestion of aluminum chloride resulted in significant decrease in fetal body weight, crown rump length, biparietal diameters and head length in comparison with all groups. Vitamin E restore this reduction in all growth parameters (Table.1). Regarding fetal rat weight, in aluminum treated rats were significantly decreased in comparison with all groups. Supplementation of vitamin E to aluminum treated rats restore both body and liver weight in rats' fetuses which are decreased due to oral aluminum ingestion (Fig.1).

### II. Biochemical findings:

Prenatal oral ingestion of  $\text{AlCl}_3$  (150 mg /kg BW/ day) induced significant increase in Thiobarbituric acid-reactive substances (TBARS), while glutathione S-transferase (GST) activity was significantly decreased in fetal livers. Supplementation of VE to  $\text{AlCl}_3$  treated rats during pregnancy preserved the levels of (TBARS) and (GST) nearer to the normal values of both negative and positive control (Table.2).

### III. Histological findings:

In hematoxylin and eosin stained sections, fetal rat liver in both negative and positive control groups (C, C+VE) showing normal hepatocytes with dark stained cytoplasm radiating from the central vein while, in aluminum chloride treated group (Al) congestion of central vein with perivascular fibrous thickening, disruption of normal architecture of hepatocytes, with vacuolated cells and degenerated cells within sinusoids. Vitamin E supplementation to aluminum treated group (AL+VE) hepatocytes restore its staining characters and be similar to control groups (Fig.2).

Regarding PAS staining, both control groups showed PAS-positive reaction for glycogen which

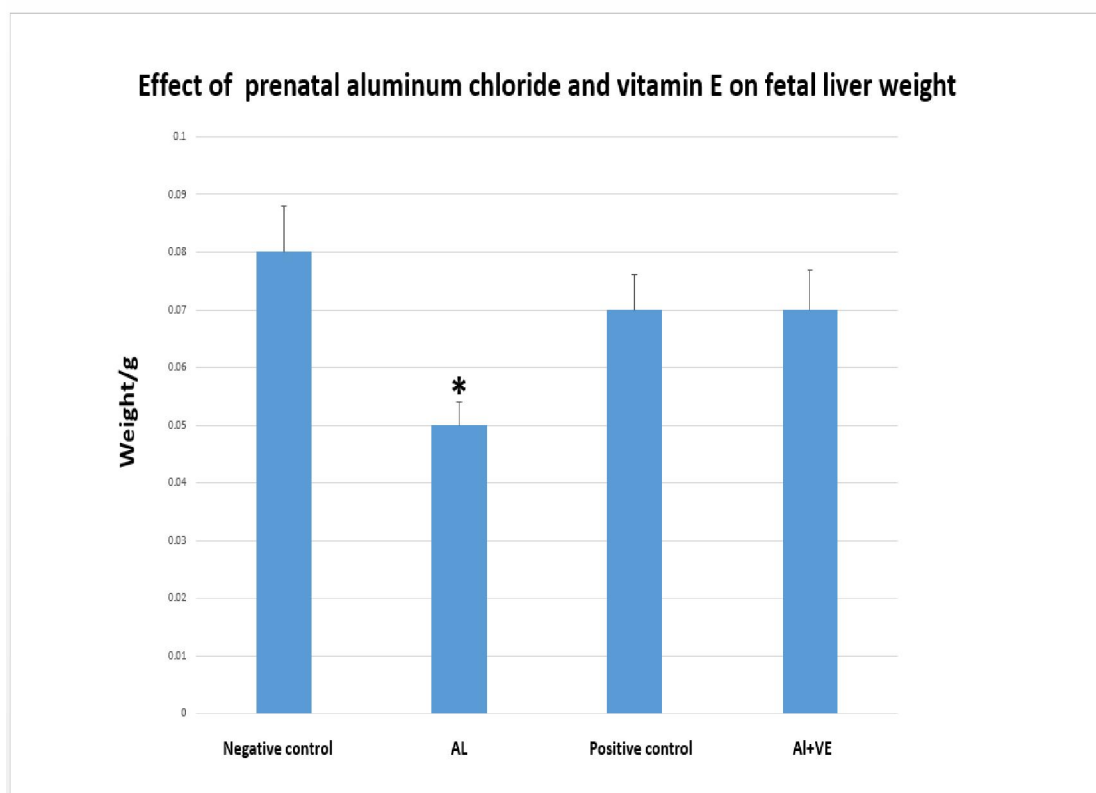
presented by large areas of hepatic cells around the central vein, while in aluminum chloride group PAS-positive cells were reduced, with only dispersed,

irregular purple liver cells surrounding the central vein. In aluminum treated group with vitamin E (AL+VE) PAS- positive reaction is restored (Fig.3).

**Table 1: Effects of Aluminum chloride and vitamin E on full term rat fetuses**

Groups	Fetal weight(gm)	Crown rump length(cm)	Head length(cm)	Biparietal diameter(cm)
Negative C	2.9 ± 0.29	3.2 ± 0.4	1.4 ± 1.16	0.69 ± 0.11
AL	2.5 ± 0.22*	2.5 ± 0.1*	1.1 ± 0.08 *	0.61 ± 0.04 *
Positive C	2.86 ± 0.12	3 ± 0.26	1.3 ± 0.08	0.65 ± 0.06
Al + VE	2.84 ± 0.1	2.9 ± 0.35	1.29 ± 0.1	0.64 ± 0.07

ANOVA test, \*Data were considered significant at  $P < 0.05$  compared to all groups . Values are represented as means  $\pm$  standard deviation.



**Fig.1: Histogram showed that prenatal aluminum chloride (AL) decreased fetal liver weight significantly (\*) in comparison to all groups.**

**Table 2. Prenatal effect of aluminum chloride and vitamin E on lipid peroxidation enzyme in fetal rats liver.**

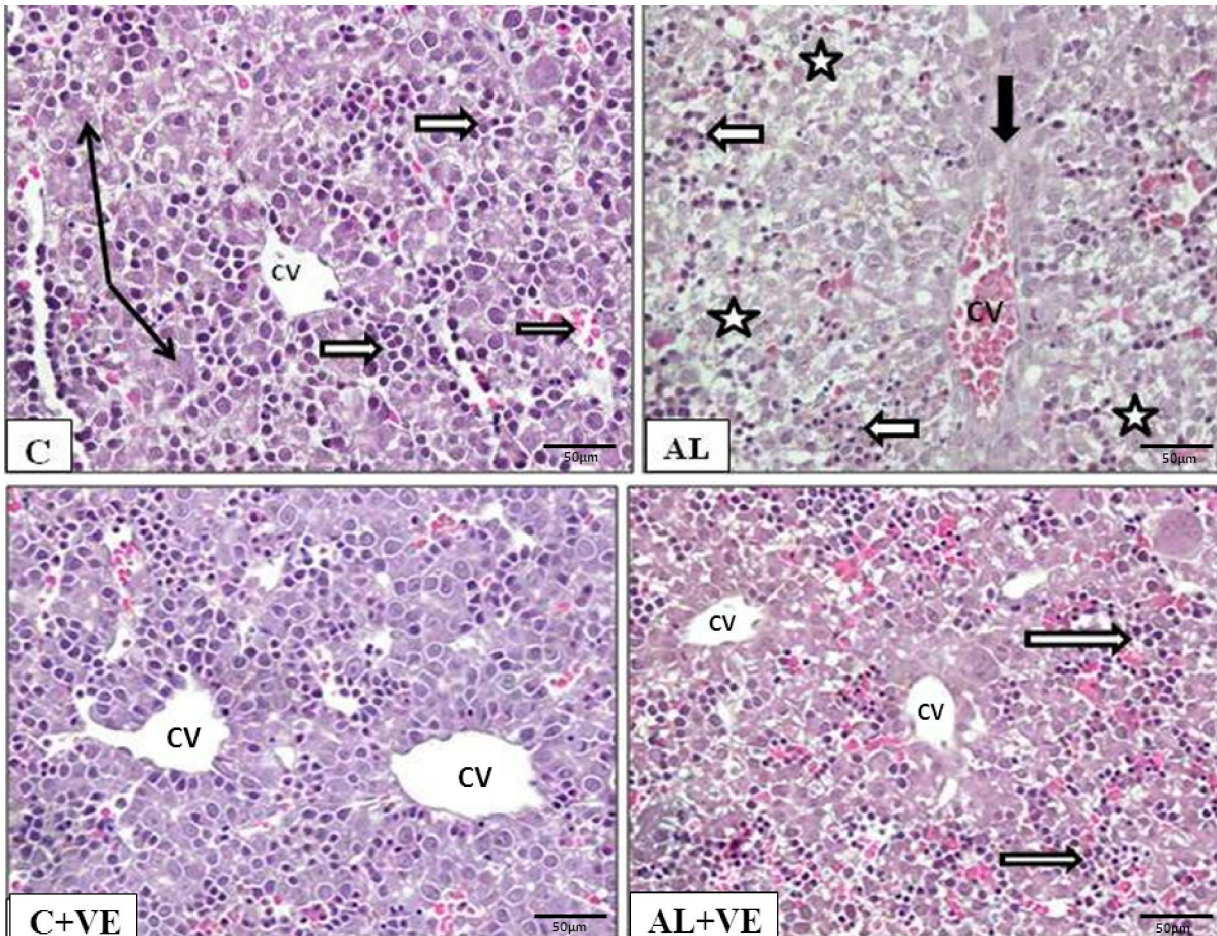
Groups	GST $\mu\text{mol/h/mg protein}$	TBARS $\text{nmol/g tissue}$
Negative C	0.03 $\pm$ 0/0008	0.4 $\pm$ 0.005
AL	0.01 $\pm$ 0.001*	0.6 $\pm$ 0.008*
Positive C	0.029 $\pm$ 0.0007	0.39 $\pm$ 0.004
Al + VE	0.027 $\pm$ 0.0006	0.43 $\pm$ 0.005

ANOVA test, \*Data were considered significant ( $P < 0.05$ ) compared to all groups .

Values are represented as means  $\pm$  standard deviation.

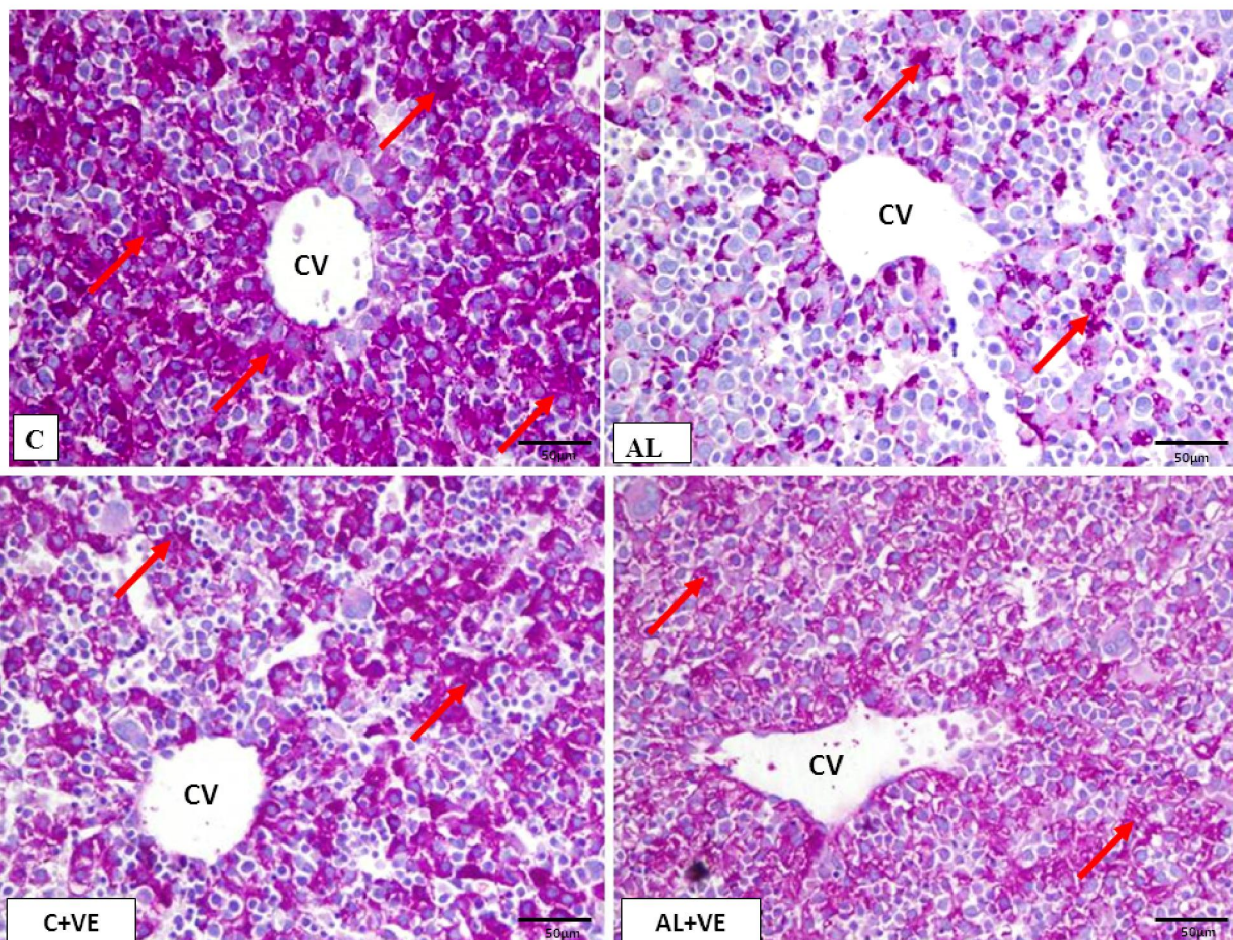
Thiobarbituric acid-reactive substances (TBARS), glutathione S- transferase (GST).





**Fig.2:** Section in fetal liver from negative control (C) showing hepatocytes with dark stained cytoplasm (black arrows) radiating from the central vein (CV). Blood sinusoids were seen, some are full of mononuclear cells (white arrows). Positive control group (C+VE) has a similar description as negative control group. In aluminum treated group (AL) congestion of central vein (CV) with perivascular fibrous thickening (black arrow), disruption of normal architecture of hepatocytes, the cells looked vacuolated due to loss of cytoplasmic staining (stars) and cells within sinusoids appeared smaller and degenerated (white arrow). In aluminum treated group with vitamin E supplementation (AL+VE) hepatocytes restore its staining characters and hematopoietic cells in blood sinusoids appeared normal (white arrow). Scale bar = 50 μm, H&E stain



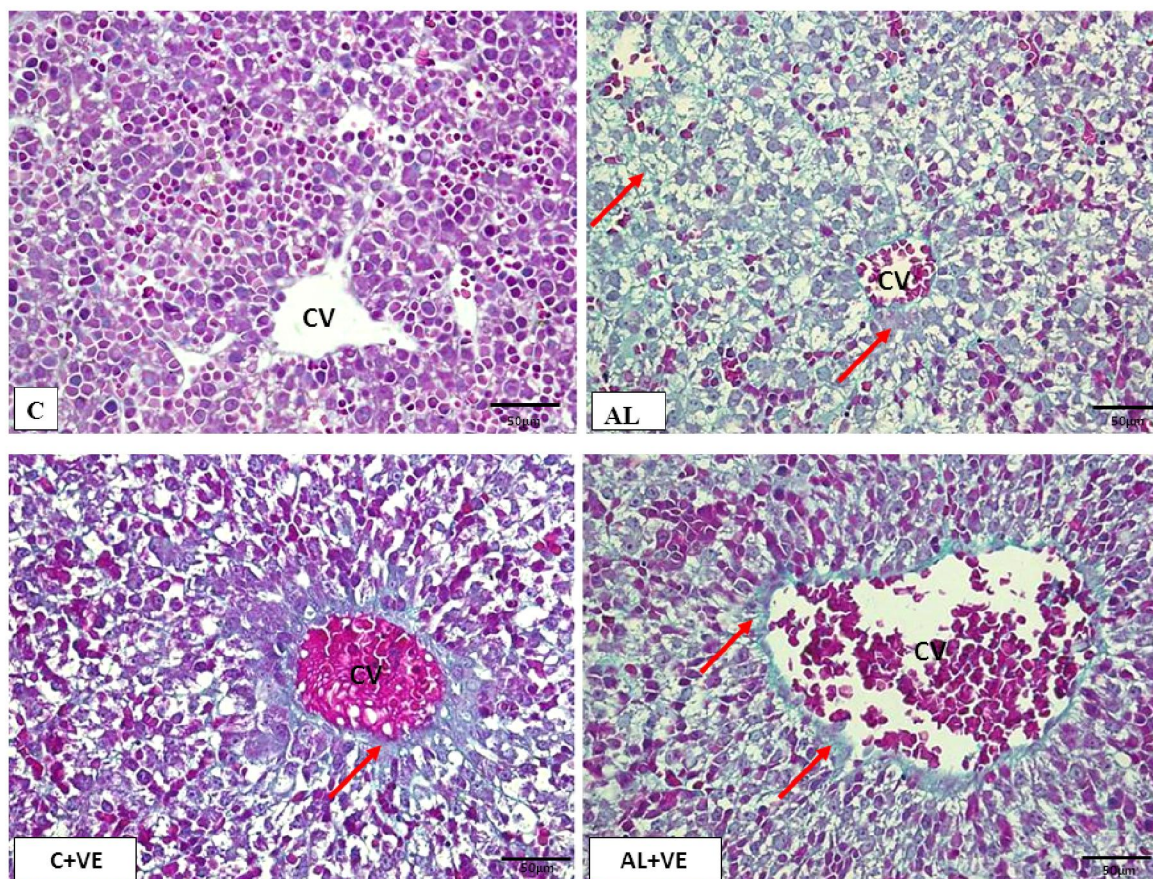


**Fig. 3:** both negative and positive control groups (C), (C+ VE) showed PAS positive reaction for glycogen which presented by large areas of hepatic cells around the central vein with positive PAS staining (red arrows) while, in Aluminum group (AL), PAS-positive cells were significantly reduced, with only dispersed, irregular purple liver cells surrounding the central vein. In aluminum treated group with vitamin E supplementation (AL+VE) PAS positive reaction is restored (red arrows). Scale bar = 50 µm, PAS stain

In Masson trichrome stain, collagen and elastic fibers is increased in aluminum chloride treated group in comparison to both negative and positive control groups. Oral ingestion of VE (150 mg/kg/day) during

pregnancy to aluminum chloride treated group (AL+VE) resulted in, decrease in collagen and elastic fibers (Fig.4).





**Fig. 4:** Collagen and elastic fibers (red arrows) is increased in aluminum treated group in comparison to Both control groups (C), (C+ VE). In aluminum treated with VE (AL+VE), collagen is decreased. Scale bar = 50 µm, Masson trichrome stain

#### 4. Discussion:

Aluminum produced reactive oxygen species which induced the oxidative deterioration of cellular lipids, proteins, and DNA. Previous researches recommend decreasing exposure to aluminum and diet supplementation with vitamin E which is valuable in the improvement of aluminum toxicity [18]. Vitamin E had a vital role as an antioxidant that protect tissues from injury produced by reactive oxygen species which antagonize Al toxicity [11].

In the present study, rats received  $\text{AlCl}_3$  (150mg/kg/day) through intragastric tube for three months before pregnancy to imitate chronic toxicity of aluminum in humans. This high dose of  $\text{AlCl}_3$  was chosen as the intestine had a protective barrier and only a small portion (0.1 to 0.5%) of swallowed aluminum is absorbed [19].

In this study, Oral  $\text{AlCl}_3$  (150mg/kg/day) three months before pregnancy and during the whole duration of pregnancy resulted in significant decrease in all growth parameters included, body weight, liver weight, biparietal diameters, crown rump length and head length. Moreover fetal liver weight also was

significantly decreased due to aluminum chloride. These findings were in accordance to previous study which revealed that in pregnant mice intraperitoneal injection of  $\text{AlCl}_3$  (150 mg/kg) significantly decreased the crown rump length and fetal body weight [20]. Our previous study on teratogenic effects of aluminum on cerebral cortex revealed that oral ingestion of aluminum resulted in significant decrease in all growth parameters in rats' fetuses [21]. It has been suggested that aluminum favorably interacts with phosphate groups, as phosphorylated proteins and nucleic acids so, Al significantly reduced DNA and RNA synthesis and prevents protein synthesis and embryonic cell proliferation. This mechanism could explain the lethal effects of aluminum on fetal growth during pregnancy. [22].

Aluminum produces reactive oxygen species that induced the oxidative damage to cellular lipids through lipid peroxidation [11]. Cellular membranes contain polyunsaturated fatty acids susceptible to the action of free oxygen radicals that initiate membrane lipid peroxidation, thus leading to disturbances in the structure and function of cells [23, 24]. The increase

in lipid peroxidation in fetal liver in the current study, was caused by aluminum chloride metabolism in the liver which significantly increased Thiobarbituric acid-reactive substances (TBARS) in fetal livers which are products of lipid peroxidation. The increased concentration of TBARS due to free radical which induced oxidative cell injury that mediate the toxicity of aluminum [25,26].

On the other hand, prenatal oral ingestion of  $AlCl_3$  (150 mg /kg BW/ day) reduced DNA and RNA which prevents protein synthesis so reduced level of glutathione S- transferase (GST). Glutathione S-transferase (GST) involved to cell survival by detoxification of harmful compounds found in the cytosol. GST enzymes play a crucial role in phase II of drug-metabolism. They have isomerase and peroxidase activities, so, protecting cells from  $H_2O_2$  which induced cell death [27]. Other cellular mechanisms to exert aluminum toxicity, that to increase the permeability of the blood-brain barrier, intervention with phosphorylation-dephosphorylation reactions, changed iron metabolism with consequent free-radical production, and disturbance of second messenger systems [28].

The biochemical finding are consistent with the histological changes in this study as, aluminum chloride induced lipid peroxidation which resulted in hepatocytes disruption, vacuolation and degeneration within sinusoids which resulted in, derangement of normal architecture of hepatocytes, increased collagen and elastic fibers between hepatocytes. Moreover, reduced glycogen content as PAS-positive cells were reduced due to decrease in the activity of enzymes responsible for glycogen storage.

Previous studies reported aluminum induced histological changes in the liver which were in agreement with our findings [29,30]. Recent study, reported that prenatal different doses of aluminum chloride (50, 100 and 200 mg/Kg/day) taken in days 9-13 of gestation induced inflammatory foci, hepatocyte injury and deposition of connective tissue around centrilobular vein [31]. On the other hand, other studies investigated liver histopathological changes did not find significant changes in rats received aluminum nitrate in drinking water (284 mg/kg/day) as for 100 days [32], and mice exposed to 49 mg Al/kg/day as, mice exposed to 979 mg Al/kg/day as aluminum sulfate in the diet for 20 months [33].

Antioxidants are recognized to decrease oxidative radical-induced responses. Vitamin E ( $\alpha$ -Tocopherol) is a vital antioxidant which prevents peroxidation of membrane lipids by converting lipid peroxyl radicals into a tocopheroxyl radical [10]. The present results revealed that oral supplementation of vitamin E (100 mg VE/kg BW/day) to aluminum chloride treated pregnant rats resulted in restore

decrease in all growth parameters for rats fetuses and increase fetal liver weight, improve histopathological changes in fetal liver in comparison with aluminum chloride treated rats fetuses. Moreover Vitamin E increase level of Glutathione S- transferase (GST) and lower level of Thiobarbituric acid-reactive substances (TBARS) in fetal livers. In accordance to our findings, previous study confirmed that vitamin E increased the activity of GST and reduced the formation of TBARS in rats' liver [11].

## Conclusion

Prenatal oral ingestion of aluminum chloride resulted in morphological, histological and biochemical changes in rat fetal liver. Vitamin E has beneficial effects which be able to antagonize aluminum chloride toxicity during pregnancy. It is suggested to enrich pregnant diet with vitamin E.

## Acknowledgements

This project was funded by the Deanship of Scientific Research (DSR), King Abdulaziz University, Jeddah, under grant No. (24/428). The authors therefore acknowledge with thanks DSR technical and financial support.

## Corresponding author:

Ghada A Abdel-Hamid,  
Anatomy Department,  
King Abdulaziz University, Saudi Arabia,  
E-mails: [gmohamed@kau.edu.sa](mailto:gmohamed@kau.edu.sa)  
[ghada169@hotmail.com](mailto:ghada169@hotmail.com)

## References

1. Scott M (2000) Aluminum compounds. Review of Toxicological Literatures Abridged Final Report. National Institute Integrated Laboratory System, Research Triangle Park, North Carolina, USA.
2. Chen J, Wang M, Run D, She J (2002) Early chronic aluminum exposure impairs long-term potentiation and depression in the rat dentate gyrus in vivo. *Neuroscience* 112 (4): 879.
3. Amarpreet K, Kiran DG (2005) Disruption of Neuronal Calcium Homeostasis after Chronic Aluminum Toxicity in Rats. *Basic & Clinical Pharmacology & Toxicology* 96 (2): 118-122.
4. Suwalsky M, Ungerer B, Villena F, Norris B, Cardenas H, Zatta P (2001) Effects of  $AlCl_3$  on toad skin, human erythrocytes, and model cell membranes. *Brain Research Bulletin*, 55: 203-210.
5. Buraimoh AA, Ojo S A, Hambolu J O, Adebisi SS (2012) Effects of aluminium chloride exposure on the histology of the liver of adult wistar rats. *IOSR Journal of Pharmacy* 2 (3): 525-533.
6. Colomina MT, Roig JL, Torrente M, Vicens P, Domingo JL (2005) Concurrent exposure to aluminum and stress during pregnancy in rats: Effects



- on postnatal development and behavior of the offspring. *Neurotoxicology Teratology*, 27:565-574.
7. Yumoto S, Nagai H, Matsuzaki H, et al. (2001) Aluminium incorporation into the brain of rat fetuses and sucklings. *Brain Research Bulletin*, 55: 229-234.
  8. Yumoto S, Ngai H, Matsuzaki H, Kobayashi T, Tada W, Ohki Y (2000) Transplacental passage of Aluminum from pregnant rats to fetus and aluminum transfer through maternal milk to milk suckling rats. *Nucl Instrum Methods Phys Res B* 172:925-929.
  9. Colomina MT, Esparza JL, Corbella J, Domingo JL (1998) The effect of maternal restraint on developmental toxicity of aluminium in mice. *Neurotoxicology Teratology* 20:651-656.
  10. Al-Attar AM (2011) Antioxidant effect of vitamin E treatment on some heavy metals-induced renal and testicular injuries in male mice. *Saudi Journal Biological Science* 8: 63-72.
  11. El-Demerdash FM (2004) Antioxidant effect of vitamin E and selenium on lipid peroxidation, enzyme activities and biochemical parameters in rats exposed to aluminum. *Journal of Trace Elements and Medical Biology* 18(1):113-121.
  12. Platt B, Fiddler G, Riedel G, Henderson Z (2001) Aluminium toxicity in the rat brain: histochemical and immunocytochemical evidence. *Brain Research Bulletin* 55:257-267.
  13. Viana M, Castro M, Barbas C, Herrera E, Bonet B (2003) Effect of Different Doses of Vitamin E on the Incidence of Malformations in Pregnant Diabetic Rats. *Ann Nutr Metab*. 47:6-10.
  14. Suckow MA, Weisbroth SH, Franklin CL (2006) *Embryology and teratology*, In: *The Laboratory Rat*, 2nd ed. Elsevier Inc: 837.
  15. Bancroft JD and Gamble M. Hematoxylin and eosin, connective tissue and stain, carbohydrates, Ch. 9,10,11, In *Theory and practice in histological techniques*, 6<sup>th</sup> ed. Churchill livingstone Elsevier. Philadelphia, PA, USA ;2008:121-186.
  16. Tappel AL, Zalkin H. Inhibition of lipid peroxidation in mitochondria by vitamin E. *Arch Biochem Biophys* 1959;80:333-6.
  17. Habig WH, Pabst MJ, Jakoby WB. Glutathione Stransferases (1974) The first enzymatic step in mercapturic acid formation. *J Biol Chem* 249:7130-7139.
  18. Kutlubay R, Oguz EO, Guven, C, Can B, Sinik Z and Tuncay OL (2007) Histological and ultrastructural evidence for protective effects on aluminum-induced kidney damage by intraperitoneal administration of alpha-tocopherol. *Int J Toxicol* 26(2):95-101.
  19. Drueke TB (2002) Intestinal absorption of aluminum in renal failure. *Nephrol Dial. Transplant*. 17:13-16.
  20. Abbasali KM, Zhila T and Farshad N (2005) Developmental Toxicity of aluminum from High Doses of AlCl<sub>3</sub> in Mice. *J App Res* 5: 575-579.
  21. Samar M Al-Saggaf, Ghada A. Abdel-Hamid, Magda Hagra and Hamid A. Saleh (2012) Does selenium ameliorate toxic effects of prenatal aluminium on brain of full term rat fetuses?. *Journal of animal and veterinary advances*. 11 (19): 3588-3592.
  22. Yumoto S, Nagai H, Matsuzaki H, et al. (2001). Aluminium incorporation into the brain of rat fetuses and sucklings. *Brain Res Bull* 55:229-234.
  23. Akhgari M, Abdollahi M, Kebryaezadeh A, Hosseini R, Sabzevari O (2003) Biochemical evidence for free radical induced lipid peroxidation as a mechanism for subchronic toxicity of malathion in blood and liver of rats. *Hum. Exp. Toxicol*. 22: 205.
  24. Droge W (2002) Free radicals in the physiological control of cell function. *Physiol. Rev* 82: 47.
  25. Anane R, Creppy EE (2001) Lipid peroxidation as pathway of aluminium cytotoxicity in human skin fibroblast cultures: prevention by superoxide dismutase+catalase and vitamins E and C. *Hum Exp Toxicol* 20:477-81.
  26. Dua R, Gill KD (2001) Aluminum phosphide exposure: implications on rat brain lipid peroxidation and antioxidant defence system. *Pharmacol Toxicol* 89:315-9.
  27. Sheehan D, Meade G, Vivienne M. Foley, Catriona A. Dowd. Structure, function and evolution of glutathione transferases (2001) implications for classification of non-mammalian members of an ancient enzyme superfamily *Biochem. J*. 360: 1-16.
  28. Agrawal SK, Ayyash L, Gourley CS, Levy J, Faber K, Hughes CL (1996) Evaluation of the developmental neuroendocrine and reproductive toxicology of aluminium. *Food Chem Toxicol* 34:49-53.
  29. Abubakar MG, Taylor A, Ferns GA (2003) Aluminium administration is associated with enhanced hepatic oxidant stress that may be offset by dietary vitamin E in the rat. *Int J Exp Pathol* 84:49-54.
  30. Bogdanovi M, Janeva AB, Bulat P (2008) Histopathological changes in rat liver after a single high dose of aluminium. *Arh Hig Rada Toksikol* 59: 97-101.
  31. Mestaghanmi H, El Amrani S, M 'Tougy I, Saile R (2011) Study of effects of aluminium chloride on histological structure of liver and spleen in pregnant rats and their offspring *Technologies de Laboratoire*. 6 (23):42-51.
  32. Domingo JL, Paternain JL, Llobet JM, Corbella J (1987b) Effects of oral aluminum administration on perinatal and postnatal development in rats. *Research Communications in Chemical Pathology and Pharmacology*, 57:129-132.
  33. Oneda S, Takasaki T, Kuriwaki K, et al (1994) Chronic toxicity and tumorigenicity study of aluminum potassium sulfate in B6C3F<sub>1</sub> mice. *In Vivo* 8(3):271-278.
  34. Robinson D, Rainer RO, Washburn SA, Clarkson TB (1996) Effects of estrogen and progestin replacement on the urogenital tract of the ovariectomized cynomolgus monkey. *Neurourol Urodyn* 15(3): 215-221.