Left Atrial Appendage Aneurysm in a Two Month Old Infant: A Case report

[1.] Ayed A. Shati[1], Ali M. Alsuheel, [2.] Mohammed A. Al-Gathradi, [3.] Khaled S. Alshaibari, [3.] Dhafer B. Al-Shehri and [1.] Eman A. Sharaf

[1.] Department of Child Health, College of Medicine, King Khalid University, Abha, Kingdom of Saudi Arabia,
[2.] Medical Radiology Department, Aseer Central Hospital[2], Abha, Kingdom of Saudi Arabia
[3.] Pediatrics Department, Aseer Central Hospital, Abha, Kingdom of Saudi Arabia
ayedshati@gmail.com; ayed33@hotmail.com

Abstract: Congenital aneurysm of the left atrial appendage is a rare anomaly caused by congenital dysplasia of the atrial muscles. The major manifestations of these aneurysms are cardiomegaly in the x-ray, supraventricular tachycardia, and systemic embolism. The case reported is a two month old infant who was evaluated because of respiratory symptoms and signs of cardiomegaly in Chest X-Ray. A large cystic mass communicating with the left atrium was seen on echocardiography. The diagnosis was based on echocardiography and was confirmed by computed tomography angiocardiography. Pathological examination after surgical excision confirmed its nature as an aneurysm of the left atrial appendage. Up to our knowledge, this case is so far the first case reported in Saudi Arabia having this presentation in infancy.

[Ayed A. Shati, Ali M. Alsuheel, Mohammed A. Al-Gathradi, Khaled S. Alshaibari, Dhafer B. Al-Shehri and Eman A. Sharaf. **Left Atrial Appendage Aneurysm in a Two Month Old Infant: A Case report.** *Life Sci J* 2014;11(10):421-423] (ISSN:1097-8135). http://www.lifesciencesite.com. 57

Key words: *Left Atrial Appendage Aneurysm, Infant – Case Report – KSA.*

1. Introduction

Isolated aneurysm of the left or right atrium is a rare congenital abnormality, first described by Semans and Taussig (1939). It represents a diagnostic dilemma in patients with cardiomegaly. Patients affected by aneurysm of the left atrial appendage are at risk of significant morbidity and mortality, but with surgical resection, prognosis is excellent. Few cases reported in the literature worldwide. As it has the potential for serious sequelae that include various arrhythmias and systemic emboli, surgical removal is indicated even in asymptomatic cases (Morales, et al., 2001).

Congenital left atrial appendage aneurysms (LAAA) are caused by congenital dysplasia of the atrial muscle (Victor S and Nayak V, 2001) and (Pomerantzeff et al., 2002). This entity is different from acquired enlargement of the left atrium (LA) secondary to rheumatic heart disease or severe mitral regurgitation.[5,6] Patients with congenital LAAA may be asymptomatic or present with chest pain, palpitations, dyspnea, systemic thromboembolism, or cardiac failure (Victor and Nayak, 2001) and (De Feyter, 1980). Non-invasive imaging of the chest, such as trans-esophageal echocardiography, computed tomography, magnetic resonance imaging (MRI), and radionuclide angiocardiography are thought to be able to detect this condition, which needs to be diagnosed early and surgically excised (Morales et al., 2001) and (Parmley Jr, 1962). We report a patient who presented with dyspnea and found to have a large left atrial appendage aneurysm. The extreme rarity of the disease entity, the usage of echocardiography and computerized tomographic angiography for diagnosis, and a brief literature review of the outcome after surgical repair forms the basis of the present study.

2. Case Report

A two month old boy infant of unconsanguineous parents, born as pre-term with gestational age of 34 weeks. He was delivered by normal vertex delivery with uneventful pregnancy. The baby cried immediately after birth with weight of 2 kg and he was discharged home in a good condition on the 2nd day of life without Neonatal Intensive Care Unit admission.

This infant was will without previous illnesses or hospitalizations till three days prior to his admission, then he presented to our hospital with history of fever, cough, shortness of breath and cyanosis. Fever started gradually, low-grade, intermittent, relieved with antipyretic, cough was productive, evoked vomiting and was associated with shortness of breath. During current illness, there was a history of interrupted feeding and sweating during feeding associated with bluish discoloration of lips. Other systemic review was unremarkable. No family history of cardiac diseases or any chronic illnesses. The patient has two healthy brothers and there was no history of abortion. Physical examination revealed that baby was sick, in severe respiratory distress,

dehydrated and no apparent dysmorphic features. There was no lymphadenopathy. Vital signs: HR was 160 beats/min, BP 89/56 mmHg, RR 65 breaths/min, O_2 Saturation 68 % on room air. Growth parameter: Weight was 3.5 Kg (below 3rd percentile), Length 55 cm (on 25th percentile), Head circumference 37 cm (on 10th percentile). Chest examination showed subcostal and intercostal retractions and the air-entry was diminished on left side with bilateral Crackles. CVS: palpable peripheral pulses, active pericardium, with normal first and second heart sounds, with no added sounds or murmur. Abdomen: soft, lax, no tenderness or organomegaly, CNS: Anterior fontanel was flat, normal cranial nerves examination, normal tone, power and reflexes. Musculoskeletal system was normal. Investigation: Complete blood count was normal. Serum glucose, renal function and liver function tests were normal. Blood gases showed mild metabolic acidosis and all results of blood and urine cultures were negative. Chest X-Ray: Showed large lobulated mass lesion occupying the posterior and middle mediastinum, silhouette the left cardiac border and left hilum. This is associated with atelectasis of the left lower lobe with collapse and with mass effect on the cardiac slightly shifted to the right side (Fig.1).

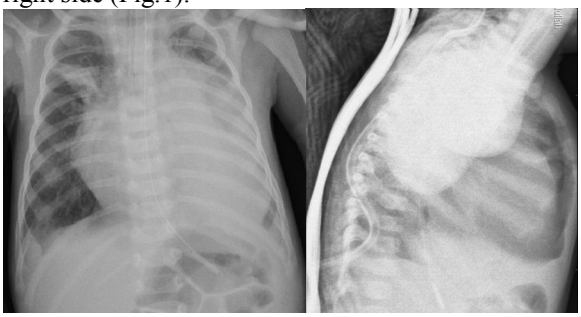

Fig 1: Frontal and lateral decubitus chest X-Rays; demonstrate large lobulated mass lesion occupying the posterior and middle mediastinum, silhouette the left cardiac border, left hilum and associated with atelectasis with collapse of the left lower lobe and with mass effect on the cardiac shifted to the right side.

Echocardiogram showed sinus rhythm with normal axis and no atrial or ventricular hypertrophy. Echocardiography showed Situs solitus, Levocardia, Normal systemic and pulmonary venous connections. No Atrial septal defect or ventricular septal defect. No right ventricular or Left ventricular outflow tracts obstruction. The left ventricle was moderately dilated with inter-ventricular septum bulging towards the right ventricle and grade 4 mitral regurgitation. A large, cystic mass measuring around 6.14 X 4.12 cm was seen adjacent to left atrium, and communicating with it. The left ventricular function was normal, no thrombi or vegetations were seen (Fig.2).

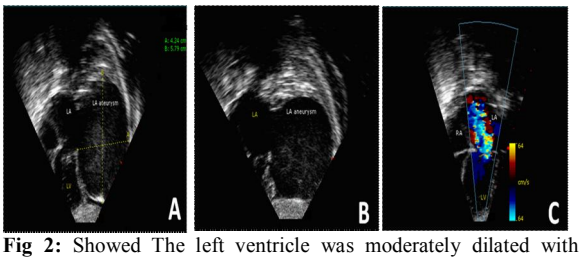

Fig 2: Showed The left ventricle was moderately dilated with inter-ventricular septum bulging towards the right ventricle and grade 4 mitral regurgitation (**C**). A large, cystic mass measuring around 6.14 X 4.12 cm was seen adjacent to left atrium (**A & B**), and communicating with it. The left ventricular function was normal, no thrombi or vegetations were seen.

Computed tomograph angiocardiography (C.T. Cardiac Angiography): Showed a large left atrial appendage aneurysm measuring 7.2 x 4.2 x 4.3 cm^3 with a wide neck measuring 1.7 cm that communicating with hyperatrophic left atrium. This is associated with mild hypoplasia of the left main pulmonary artery and mass effect on the cardiac shifted to the right side. Normal variant of Bovine aortic arch is noted and no evidence of thrombosis and there is left lung collapse (Fig.3).

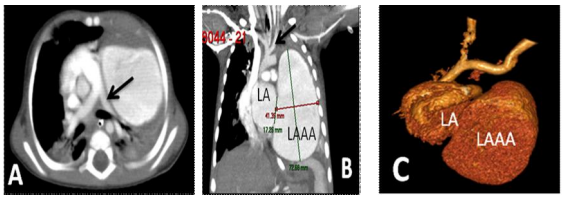

Fig 3: CT cardiac angiography ,(**A**) axial , (**B**) coronal reformate and (**C**) volume rendering (**B & C**) showed large left Atrial Appendage Aneurysm measuring 7.2 x 4.1 x 4.3 cm^3 with a wide neck measuring 1.7 that communicating with hyperatrophic left atrium. This is associated with mild hypoplasia of the left main pulmonary artery (Small arrow in **A**) and mass effect on the cardiac shifted to the right side. Normal variant of Bovine aortic arch is noted (Small arrow in **B**).

The patient stayed in the pediatric ICU for eight days to control his lung infection. Because of lacking of cardio-thoracic surgery at our center, the patient was referred to King Faisal Specialized hospital for surgical excision of the aneurysm. After surgery, the left lung showed mild improvement, and pathology report confirmed the diagnosis.

3. Discussion

Isolated aneurysm of the left or right atrium (first described by Semans and Taussig, 1939) is a rare congenital anomaly that may go undetected or misdiagnosed. Victor and Nayak (2001) postulated that the cause of the aneurysm may be due to congenital dysplasia of the musculi pectirati and of the left atrial muscle bundles related to them. Such dysplasia would impair contractions of the appendage during atrial systole (Victor and Nayak, 2001) and

(Hammad, 2004). Most cases of this rare lesion are recognized between the 2nd and 4th decades of life. It represents a diagnostic dilemma in patients with cardiomegaly (Pomerantzeff, 2002). The condition is not benign, and operation with aneurysmectomy, which is curative, is recommended for all patients with a true aneurysm (Behrendt and Aberdeen, 1972).

This reported case is of a two month old boy infant who presented with severe respiratory distress due to severe pneumonia and heart failure. The infant was admitted to pediatric intensive care unit, intubated, and received the needed therapy. On chest x-ray: Cardiomegaly was observed and echocardiography could reveal the nature of this cardiomegaly to be due to the left atrial aneurysm with severe mitral regurgitation. C.T. with angiography added more information regarding his lungs, as left one was found to be collapsed and inflamed. Surgical excision of the aneurysm was carried out, and was followed by improvement of the general condition and partial re-ariation of the collapsed lung.

Yoshihisa Tanoue et al., reported the surgical excision of a left atrial appendage aneurysm in a one year old infant (Yoshihisa, 2004). This makes our patient the youngest one reported with his anomaly.

The usual modes of presentation of this anomaly are an abnormal chest x-ray, systemic embolisation, or supraventricular arrhythmia, either alone or in combination (Bramlet and Edwards, 1981). Our patient is an exception to this statement, as he presented with lung collapse, severe pneumonia and heart failure. These findings can be due to the large size of the aneurysm that caused severe mitral regurgitation and heart failure as well as left lung collapse. Although echocardiography was highly diagnostic in our case, C.T. angiography was very helpful in two aspects: the first one is to measure the actual size of the aneurysm; the second is to document the condition of both lungs. These findings went with that stated by Samalha et al. (2005) in recent years, C.T. angiography and MRI proved to be useful for detection and diagnosis of the anomaly.

4. Conclusion

In summary, this case is of a two month old infant with left atrial aneurysmal mass who presented with severe pneumonia and heart failure. We believe that the size of left atrial appendage aneurysm in our case is the largest ever been reported in the literature, especially in infants who are less than six months of life. Echocardiography was diagnostic, but CT angiography was mandatory to reveal the associated pulmonary abnormalities. Resection was curative with improvement of the pulmonary and general condition of the patient.

Corresponding Author:
Dr. Ayed A. Shati
Child Health Department
College of Medicine,
King Khalid University,
Abha, Kingdom of Saudi Arabia
Mobile: 00966555752063
Email: ayedshati@gmail.com; ayed33@hotmail.com

References

1. Semans JH, Taussig HB. Congenital 'aneurysmal' dilation of the left auricle. Bull Johns Hopkins Hosp 1939;63:404-14.
2. Morales JM, Patel SG, Jackson JH, Duff JA, Simpson JW. Left atrial aneurysm. Ann Thorac Surg 2001; 71:719-2.
3. Victor S, Nayak V. Aneurysm of the left atrial appendage. Tex Heart Inst J 2001; 28(2): 111–8.
4. Pomerantzeff P M, Freyre HM, de Almeida Brand CM, Pereira Barreto AC, Almeida de Oliveira S. Aneurysm of the left atrial appendage. Ann Thorac Surg 2002; 73:1981–3.
5. Behrendt DM, Aberdeen E**.** Congenital Aneurysm of the Left Atrium**.** Ann Thorac Surg 1972; 13:54-9.
6. Bramlet DA, Edwards JE. Congenital aneurysm of left atrial appendage. Br Heart J 1981; 45: 97-100.
7. De Feyter PJ, Zienkowicz BS, Heidendal GAK, Majid PA, Roos JP. Radionuclide angiography in the diagnosis of congenital intrapericardial aneurysm of the left atrial appendage Thorax, 1980; 35: 154-5.
8. Parmley Jr LF. Congenital Atriomegaly. Circulation, 1962; XXV: 553-8.
9. Hammad A, Abdel-Aziz O, Alsheikh R, Wahby EA. Idiopathic giant aneurysm of left atrial appendage. *IJTCVS* 2004; 20: 186–8.
10. Yoshihisa Tanoue, Hideaki Kado, Yuichi Shiokawa and Koichi Sagawa. Left atrial appendage aneurysm in a child. Ann Thorac Surg 2004;77:721-3.
11. Samalha W, Badaneih Y, Samara Y. Giant atrial appendage aneurysm: a case report. JRMS 2005; 12(1): 41-4.