

## Hepatotoxic Effects of Titanium Dioxide Nanoparticles & the Possible Protective Role of N-acetylcysteine in Adult Male Albino Rats (Histological & Biochemical Study)

Eman S. El-Zahed; Hoda R. El-Sayed, Osama Y. Ibraheem\* and Bothina H. F. Omran.

Forensic Medicine and Clinical Toxicology and Histology\* Departments, Faculty of Medicine, Zagazig University, Egypt.

[Usay2003@yahoo.com](mailto:Usay2003@yahoo.com)

**Abstract: Background:** Titanium dioxide nanoparticles (TiO<sub>2</sub>NPs) nanoparticles are among the most commonly used metal oxide nanoparticles in industrial products, such as cosmetics, sunscreens, food products, paints and drugs. They have been reported to elicit various adverse cellular effects including oxidative stress and DNA damage. **Aim:** The aim of this work was to study the toxic effects of oral TiO<sub>2</sub>NPs and the possible antioxidant protective role of N-acetylcysteine (NAC) on the liver of adult albino rats. **Material and methods:** Fifty adult male albino rats were classified into five equal groups. **Group I:** Negative control received regular diet and water. **Group II:** Positive control administered 1ml of 5% gum acacia solution (solvent of TiO<sub>2</sub>) once daily. **Group III:** Each rat gavaged orally with 100 mg/kg b.w. NAC once daily. **Group IV:** Each rat received 1200 mg/kg b.w. TiO<sub>2</sub>NPs in 1ml of 5% gum acacia once daily. **Group V:** Each rat gavaged orally with 100 mg/kg b.w. NAC then 1200 mg/kg b.w. TiO<sub>2</sub>NPs once daily. After 12 weeks the rats of all groups were subjected to blood sample for estimating aspartate transaminase (AST), alanine transaminase (ALT), Total bilirubin (TBIL), reduced glutathione (GSH) and serum malondialdehyde (MDA) level. Then the liver was dissected and subjected to histological and ultrastructural examination and immunohistochemical detection of TNF- $\alpha$ . Cell suspension from the liver was examined to determine the extent of DNA damage by the Comet assay. **Results:** The results revealed that TiO<sub>2</sub>NPs induced histological and ultrastructural changes in the liver in the form of congestion and lymphocytic aggregation. The hepatocytes were vacuolated with pyknotic nuclei and positive for TNF- $\alpha$  immunoreaction. Also, the oxidative toxic effects of TiO<sub>2</sub>NPs on liver function were demonstrated through the detection of increased AST, ALT and serum MDA level with decreased in TBIL and GSH level in comparison to controls. Also, comet assay result showed that TiO<sub>2</sub>NPs exposure produced DNA damage in liver cells. On the other hand administration of NAC with TiO<sub>2</sub>NPs produced partial to complete protection of hepatic histological changes, TNF- $\alpha$  immunoreactivity, liver function tests and oxidative stress markers with moderate protective effects against DNA damage. **Conclusion:** TiO<sub>2</sub>NPs exposure causes toxic effects on the liver that may be attributable to oxidative stress and administration of NAC offers protection against its damaging effects. **Recommendations:** It is recommended to limit ingestion of TiO<sub>2</sub> nanoparticles through nonessential drug additives, food colors, etc. and to decrease the risk of TiO<sub>2</sub>NPs toxicity, NAC can be used as supplement to occupationally exposed workers.

[Eman S. El-Zahed; Hoda R. El-Sayed, Osama Y. Ibraheem and Bothina H. F. Omran. **Hepatotoxic Effects of Titanium Dioxide Nanoparticles & the Possible Protective Role of N-acetylcysteine in Adult Male Albino Rats (Histological & Biochemical Study).** *J Am Sci* 2015;11(7):79-91]. (ISSN: 1545-1003). <http://www.jofamericanscience.org>. 10

**Key words:** Titanium dioxide nanoparticles, N-acetylcysteine, Hepatotoxicity, oxidative stress.

### 1. Introduction

Titanium dioxide (TiO<sub>2</sub>), known as titanium oxide or titania is naturally occurring oxide of titanium which exists in three forms: rutile, anatase and brookite. There are some differences in physical (crystal structure, stability, hardness and density) and optical (color, luster, brightness and refractive index) properties between them (Markowska-Szczupack *et al.*, 2011).

TiO<sub>2</sub> is widely used to provide whiteness in products such as paints, plastic and paper and is also a permitted color in foodstuffs. It is also used in cosmetic and skin care products, particularly in sunscreen, where it helps to protect the skin from

ultraviolet (UV) light due to its effective ability to block long-wave UV (Zhang *et al.*, 2009).

Moreover, TiO<sub>2</sub> has been proved to be highly efficient in killing antibiotic resistant bacteria by destroying bacterial spores. It was found that the bacterial spore destruction was attributed to the highly oxidizing radicals generated by it (Brunet *et al.*, 2009).

Titanium either pure or in alloys is extensively used for a wide range of implanted medical devices, such as dental implants, joint replacements, cardiovascular stents, and spinal fixation devices, due to its advantageous combination of physico-chemical and biological properties. However, under mechanical stress or altered physiological conditions such as low pH, Titanium-based implants can release large

amounts of particle debris, both in the micrometer and nanometer size range (Vamanu *et al.*, 2008).

The use of nanotechnology has seen an exponential growth in the areas of its use. This is due to the unique properties of nanomaterials (chemical, mechanical, optical, magnetic, and biological) which make them desirable for commercial and medical applications (Shukla *et al.*, 2011). The increased use of nanoparticles is a matter of a great concern among health and environmental scientists due to their potential human and environmental risk. The toxic effects of nanoparticles can be attributed to the small size and hence large surface area, thereby increasing chemical reactivity and penetration in the living cells interfering with several subcellular mechanisms (Hu and Gao, 2010).

In various studies Titanium dioxide nanoparticles have been reported to elicit various adverse cellular effects including oxidative stress and DNA damage (Wang *et al.*, 2009). Some studies showed that some nanoparticles can penetrate into cell nuclei and hence may directly interfere with the structure and function of genomic DNA. Moreover, TiO<sub>2</sub>NPs have also been shown to produce reactive oxygen species (ROS) leading to the toxicity (Barnard, 2010).

Different toxic effects on the liver functions were reported with various routes of exposure, such as the intragastric, intraperitoneal and intratracheal; dermal, or intraarticular that was used by to simulate the release of NPs into joint cavities from the nanocoated surface of prostheses considering the good prospects for application of nanomaterials in prosthetic implants. (Cui *et al.*, 2011),

Interestingly, TiO<sub>2</sub>NPs were able to penetrate the skin to accumulate in the liver inducing oxidative stress, and focal necrosis in the parenchyma. The potential role of an oxidative attack in causing liver damage was recently demonstrated in intragastrically and intraperitoneally exposure to nanoparticulate TiO<sub>2</sub>. ROS accumulation, lipid peroxidation, and altered expression of genes involved in antioxidative or detoxification processes were triggered by NPs exposure (Iavicoli *et al.*, 2012).

On the other hand, N-acetylcysteine (NAC) is an antioxidant and free radical scavenger. It acts as a cysteine donor and maintains or even increases the intracellular levels of glutathione, a tripeptide which protects cells from toxins such as free radicals. NAC has been used to combat oxidative stress-induced damage in various tissues (Jain *et al.*, 2011). Therefore, the present study was carried out to investigate the toxic effects of orally administered TiO<sub>2</sub> on the liver of albino rats through histological immunohistochemical detection of TNF- $\alpha$ , oxidative stress markers and comet assay. Additionally to

evaluate the possible protective role of co-administration of NAC.

## 2. Material and Methods

### Chemicals

**Titanium dioxide nanoparticles (TiO<sub>2</sub>NPs):** It is a white odorless nanopowder of 21 nm particle size, 35-65 m<sup>2</sup>/g surface area and purity  $\geq 99.5\%$  trace metals basis. Its CAS No is 13463-67-7 manufactured by Sigma-aldrich Chemical Company, Germany and purchased from Sigma-Egypt.

**Gu:m acacia** It is presented in a powder form and prepared by dissolving 10 gm in 100 ml boiled distilled water. It was obtained from El-Nasr Pharmaceutical Chemicals Company, Egypt.

**N-Acetylcysteine (NAC):** It was obtained from SEDICO Company, Egypt in the form of effervescent instant sachets, 200 mg each. It is soluble in distilled water.

### Animals:

The study was carried out on 50 adult male albino rats with average weight of 150 - 200 gm that obtained from the Animal House, Faculty of Medicine, Zagazig University.

### Experimental design

The experiment was performed in accordance with the guidance of ethical committee for research on laboratory animals (Institute of Laboratory Animal Resources, 1996). The rats were divided into 5 equal groups each of 10 rats .Group I (negative control) received regular diet and water. Group II (positive control) received 1 ml of 5% gum acacia solution (solvent of titanium dioxide) by oral gavage once daily. Group III (NAC treated) gavaged with 100 mg/kg body weight N-acetylcysteine once daily (Jain *et al.*, 2011). Group IV (TiO<sub>2</sub>NPs treated) gavaged with 1200 mg/kg body weight titanium dioxide nanoparticles (1/10 LD<sub>50</sub>) dissolved in 1ml of 5% gum acacia solution once daily. Group V (TiO<sub>2</sub>NPs and NAC treated) each rat gavaged with 100 mg/kg body weight NAC then 1200 mg/kg body weight TiO<sub>2</sub>NP once daily.

### Sampling

After 12 weeks, Blood samples were collected from orbital venous plexus, centrifuged and blood sera were stored at 4°C. Then, the animals were anaesthetized with ether and sacrificed by transcatheter perfusion with cold 1% paraformaldehyde in 0.1 M phosphate buffered saline (PBS) of pH 7.4 for 1min, followed by cold 4% paraformaldehyde in the same buffer for 10 min.

From one lobe, liver specimens were taken for light and electron microscope examination. Specimens for light microscopy were fixed in 10 % neutral formol saline for 24 hours. Specimens for electron microscopy were immediately fixed in 2.5% phosphate-buffered

glutaraldehyde (pH 7.4). Then, they were postfixed in 1% osmium tetroxide in the same buffer at 4°C, dehydrated, and embedded in epoxy resin (**Glauert and Lewis, 1998**). The other lobe of the liver of each rat was immediately kept in physiological saline (0.9% NaCl) at -20°C for the comet assay.

## Methods:

### 1. Histological study:

The fixed samples were embedded in paraffin blocks and processed for the preparation of 5µ thick sections that stained with haematoxylin and eosin (**Bancroft, and Gamble, 2008**).

### 2. Immunohistochemistry study:

Immunohistochemistry was carried out with labeled streptavidin-biotin (LSAB) technique (a modification of the Dako protocol). The deparaffinized sections were incubated in hydrogen peroxide to block endogenous peroxidase. Then sections were incubated with the rabbit polyclonal primary antibodies for TNF- $\alpha$ . The sections were incubated with the secondary antirabbit antibodies and peroxidase labeled streptavidin. Staining was completed by incubation with substrate chromogen which resulted in brown-colored precipitate at the antigen sites. Mayer's Hematoxylin was used as a counter stain (**Bancroft & Cook, 1994 and Bhan, 1995**).

### 3. Ultrastructural study:

Ultrathin sections were stained with uranyl acetate and lead citrate (**Glauert and Lewis, 1998**), examined and photographed using a JEOL 1010 EM (Jeol Ltd, Tokyo, Japan) in EM Research Laboratory of the Histology and Cell Biology Department, Faculty of Medicine, Zagazig University, Egypt.

### 4. Biochemical studies:

#### A- Liver function tests:

**AST (Murray, 1984a):** AST catalyses an amino group from aspartate to  $\alpha$ -ketoglutarate forming glutamate and oxalacetate. The oxalacetate produced is reduced to malate and NADH by malate dehydrogenase.

**ALT (Murray, 1984b):** ALT catalyses an amino group from alanine to  $\alpha$ -ketoglutarate forming glutamate and pyruvate. Pyruvate produced is reduced to lactate and NADH by lactate dehydrogenase.

The rate of decrease in concentration of NADH is proportional to the catalytic concentration of AST or ALT present in the sample, that were measured photometrically.

**TBIL (Kaplan *et al.*, 1984):** Bilirubin is converted by diazotized sulfanilic acid to colored azobilirubin that its intensity is proportional to the bilirubin concentration (measured photometrically).

#### B- Oxidative stress markers:

**MDA (Yoshioka *et al.*, 1979):** MDA reacts with Thiobarbituric acid (TBA) and gives pink colored trimethine complex that measured by absorbance on Erba Chem7 spectrophotometer at 532 nm.

**GSH (Moron *et al.*, 1979):** Reduced GSH on reaction with 5,5'-dithiobis nitro benzoic acid (DTNB) produces a yellow colored product that measured at 412 nm.

### 5. Comet assay:

The comet assay was performed in Animal Reproductive Research Institute (ARRI) of Agricultural Research Centre of Ministry of Agriculture and Land Reclamation, Cairo, Egypt, according to the method of **Singh *et al.*, (1988)** as follows:

#### A. Preparation of base slides

Low Melting Point Agarose (LMPA 0.5%) and Normal Melting Agarose (NMA 1.0%) were prepared. While NMA is hot, clean dry slides were dipped up to one-third of frosted area, removed and laid to dry.

#### B. Liver cell isolation

A small piece of the liver was placed in 1 ml cold Hank's Balanced Salt Solution "HBSS" containing 20 mM EDTA/10% Dimethylsulfoxide "DMSO", minced into fine pieces, let settle, removed and 5 - 10 ul mixed with 75 ul LMPA, and processed accordingly.

#### C. Electrophoresis of microgel slides

Slides were placed side by side on the horizontal gel box close together as possible. The buffer reservoirs were filled with freshly made Electrophoresis Buffer until completely covers the slides for 20 minutes to allow for unwinding of the DNA and the expression of alkali-labile damage.

The power was turned on and the current was adjusted to 300 milliamperes to electrophorese the slides for 30 minutes. Then the power was turned off and the slides were gently lift from the buffer and placed on a drain tray.

Slides were stained with 80ul IX Ethidium Bromide "EtBr", leaved for 5 min and then dipped in chilled distilled water to remove excess stain. The slides were covered by cover slip and scored immediately.

#### D. Evaluation of DNA Damage

For visualization of DNA damage, observations are made of EtBr-stained DNA using a 40x objective on a fluorescent microscope. A Komet 5 image analysis software developed by Kinetic Imaging, Ltd. (Liverpool, UK) linked to a CCD camera that was used to assess the quantitative and qualitative extent of DNA damage in the cells by measuring the length of DNA migration (tail length) and the percentage of migrated DNA in the tail (tail DNA%). Finally, the program calculates tail moment (correlation between tail length and tail DNA%). Generally, images of 100 (50 X 2) randomly selected cells are analyzed per sample. The mean value (for 100 cells) was calculated.

### 8. Statistical analysis

Data collected throughout laboratory investigations and outcome measures coded, entered

and analyzed using SPSS version 20.0. Differences between multiple means (quantitative variables) were compared by ANOVA test, followed by LSD. *P* value was set at <0.05 for significant results, <0.01 for high significant result and <0.001 for very high significant result.

## Results

### A-Examination of H&E stained sections:

The light microscope findings for rats of group I (negative control) were shown in **Fig.1**. Classic hepatic lobule consisting of hepatocyte plates separated by blood sinusoids radiated from the central vein. Individual hepatocytes have one or two large, round and pale-stained nuclei with dark nucleoli. Group II (positive control) and group III (NAC treated) showed the same histological features without any observable changed findings.

**Group IV** (TiO<sub>2</sub>NPs treated): After 12 weeks of treating animals with titanium dioxide nanoparticles, several histological alterations were detected. Some lobules showed disorganization and congestion. Hepatocytes appeared vacuolated and some of them contained pyknotic nuclei. Also lymphocytic infiltration and aggregation (nodule) were detected (**Figs 2&3**).

**Group V** (TiO<sub>2</sub>NPs and NAC treated): Administration of NAC with TiO<sub>2</sub>NPs lead to obvious improvement of hepatic lobules, preservation of normal hepatic lobular architecture. Hepatocytes were slightly vacuolated with some pyknotic nuclei, the sinusoidal spaces were moderately congested (**Fig. 4**).

### B-Immunohistochemical detection of TNF- $\alpha$ :

Immunohistochemical examination of the liver sections of group I (negative control), showed weak TNF- $\alpha$  immuno-reactivity in the hepatocytes (**Fig. 5**). Group II (positive control) and group III (NAC treated) showed the same immuno-reactivity.

**Group IV** (TiO<sub>2</sub>NPs treated): Compared to control groups, TNF- $\alpha$  was up-regulated 12 weeks after TiO<sub>2</sub>NPs treatment, where positive TNF- $\alpha$  immunoreaction was detected in the hepatocytes (**Fig. 6**). **Group V** (TiO<sub>2</sub>NPs and NAC treated): Administration of NAC with TiO<sub>2</sub>NPs to animals of group (V) revealed decreased TNF- $\alpha$  immuno-reactivity in the hepatocytes (**Fig.7**).

### C-Ultrastructural results:

Examination of liver ultrathin sections of the negative control group (group I) showed hepatocytes with euchromatic nuclei containing prominent nucleoli. The cytoplasm contained numerous mitochondria, rough endoplasmic reticulum and small electron dense glycogen granules and the hepatocytes were adjacent to each other with blood sinusoids in between (**Fig. 8**). Positive control (group II) and NAC group (group III) showed the same ultrastructural findings.

**Group (IV):** Examination of liver ultrathin sections of TiO<sub>2</sub>NPs group revealed different degrees of affection. Some cells showed marked rarefaction of the cytoplasm with appearance of numerous fat droplets of different sizes, the most affected cells appeared with pyknotic nuclei, numerous fat droplets and vacuoles. The intercellular spaces show congestion (**Figs. 9&10**).

**Group (V):** Administration of NAC with TiO<sub>2</sub>NPs to animals of group (V) revealed partial improvement of hepatocytes. The hepatocytes appeared with euchromatic nuclei containing prominent nucleoli. The cytoplasm contained numerous mitochondria, rough endoplasmic reticulum, smooth endoplasmic reticulum, few vacuoles and lipid droplets (**Fig. 11**).

### D-Biochemical results (Table 1)

As comparing the laboratory results of biochemical tests (liver function tests and oxidative stress markers) of the negative and positive control groups there was no statistically significant difference between them all over the study ( $p>0.05$ ).

**Serum transaminases (AST & ALT):** There was a non significant difference ( $p>0.05$ ) in AST & ALT mean values between NAC treated group and control groups. However there was a significant increase ( $p<0.05$ ) in AST & ALT mean values of TiO<sub>2</sub>NPs treated group when compared with both control groups and NAC treated group. Also there was a non significant difference ( $p>0.05$ ) in AST & ALT mean values between NAC+TiO<sub>2</sub> treated group and both control groups and NAC treated group. At the same time there was a significant decrease ( $p<0.05$ ) in AST & ALT mean values of NAC+TiO<sub>2</sub> treated group as compared with those of TiO<sub>2</sub>NPs treated group.

**Total bilirubin levels (TBIL):** There was a non significant difference ( $p>0.05$ ) in TBIL mean values between NAC treated group and control groups. However there was a significant decrease ( $p<0.05$ ) in TBIL mean values of TiO<sub>2</sub>NPs treated group when compared with both control groups and NAC treated group. But there was a non significant difference ( $p>0.05$ ) between NAC+TiO<sub>2</sub> treated group and both control groups and NAC treated group. Moreover there was a significant increase ( $p<0.05$ ) in TBIL mean values of NAC+TiO<sub>2</sub> treated group as compared with TiO<sub>2</sub>NPs treated group.

**Serum reduced Glutathion (GSH):** There was a non significant difference ( $p>0.05$ ) in GSH mean values between NAC treated group and control groups. Yet there was a significant decrease ( $p<0.05$ ) in GSH mean values of TiO<sub>2</sub>NPs treated group when compared with both control groups and NAC treated group. There was a significant increase ( $p<0.05$ ) in GSH mean values of NAC+TiO<sub>2</sub> treated group as compared with both control groups and NAC treated group. While there was a significant increase ( $p<0.05$ ) in GSH mean



values of NAC+TiO<sub>2</sub> treated group as compared with those of TiO<sub>2</sub>NPs treated group.

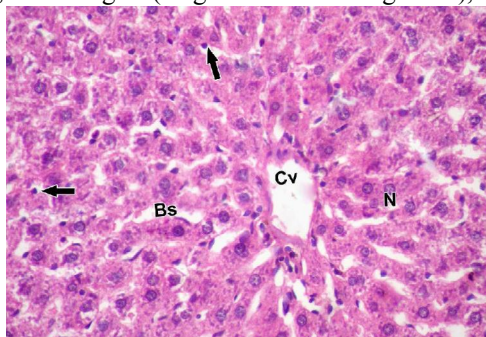
**Serum malondialdehyde (MDA):** There was a non significant difference ( $p>0.05$ ) in MDA mean values between NAC treated group and control groups. However there was a significant increase ( $p<0.05$ ) in MDA mean values of TiO<sub>2</sub>NPs treated group when compared with both control groups and NAC treated group. Also a significant increase ( $p<0.05$ ) was recorded in NAC+TiO<sub>2</sub> treated group when compared with both control groups and NAC treated group. While there was a significant decrease ( $p<0.05$ ) in MDA mean values of NAC+TiO<sub>2</sub> treated group as compared with those of TiO<sub>2</sub>NPs treated group.

#### Comet assay results

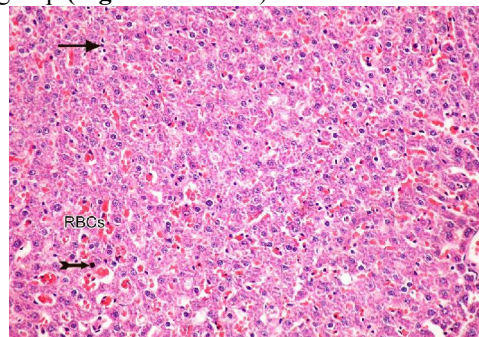
Regarding the oxidative DNA damage caused by TiO<sub>2</sub>NPs, the present study tested the *in vivo* genotoxic potential of TiO<sub>2</sub>NPs in rats using the single cell gel electrophoresis (comet assay). The result revealed that oral administration of TiO<sub>2</sub>NPs caused an increase in DNA damage in liver of albino rats. The parameters used to measure DNA damage in the cells were the percentage of tailed nuclei, percentage of untailed nuclei, tail length (length of DNA migration), tail

DNA percentage (percentage of migrated DNA in the tail) and unit tail moment (correlation between tail length and tail DNA percentage).

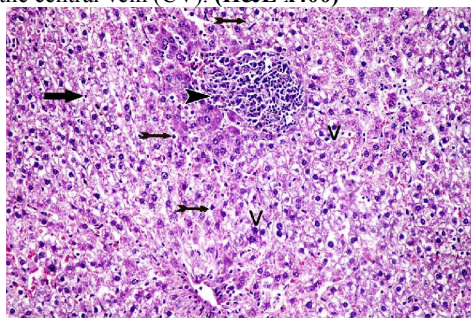
As comparing the comet results of liver specimen of the negative control group and the positive control group, there was no statistically significant difference between them in all parameters ( $p>0.05$ ). As well as liver specimens of NAC treated group revealed a non significant difference ( $p>0.05$ ) in all parameters compared with those of the control groups. **Group IV** (TiO<sub>2</sub>NPs treated) showed a significant increase ( $p<0.05$ ) in percentage of tailed nuclei, tail length, tail DNA percentage and unit tail moment of hepatic nuclei compared with the nuclei of both control groups and NAC treated group. Administration of NAC with TiO<sub>2</sub>NPs to animals of **group V** revealed significant decrease ( $p<0.05$ ) of DNA damage parameters in nuclei of liver specimens compared with TiO<sub>2</sub>NPs treated group. However, there was a significant increase ( $p<0.05$ ) in percentage of tailed nuclei, tail length, tail DNA percentage and unit tail moment ( $p<0.001$ ) of NAC+TiO<sub>2</sub> treated group as compared with those of the control groups and NAC treated group (**Fig. 12&Table 2**).



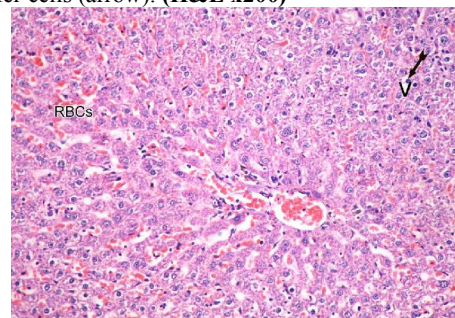
**Figure (1):** A photomicrograph of a section in the hepatic lobule obtained from an adult male albino rat of the group I (negative control) showing hepatocytes with large pale nuclei (N) and separated by blood sinusoids (Bs) radiating from the central vein (CV). (H&E x400)



**Figure (2):** A photomicrograph of a section in the hepatic lobule of adult male albino rat of the group IV (TiO<sub>2</sub>NPs treated) showing sever congestion (RBCs), hepatocytes with darkly stained pyknotic nuclei (tailed arrow) and numerous Kupffer cells (arrow). (H&E x200)

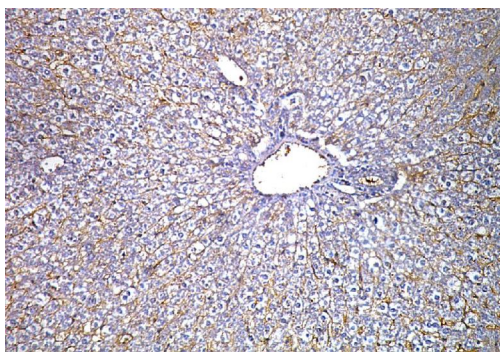


**Figure (2):** A photomicrograph of a section in hepatic lobules obtained from a rat of group IV (TiO<sub>2</sub>NPs treated) showing disorganization, marked vacuolation (V), shrunken hepatocytes with darkly stained pyknotic nuclei (tailed arrow), aggregation of lymphocytes (arrow head) and numerous Kupffer cells (arrow). (H&E x200).

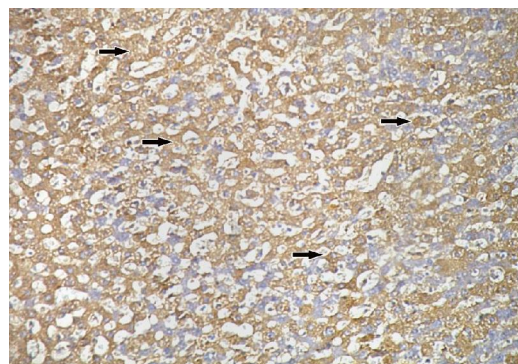


**Figure (4):** A photomicrograph of a section in hepatic lobules obtained from an adult male albino rat of the group V (TiO<sub>2</sub>NPs and NAC treated) showing mild disorganization, moderate congestion (RBCs), vacuolation (V) and few hepatocytes with darkly stained pyknotic nuclei (tailed arrow). (H&E x200).

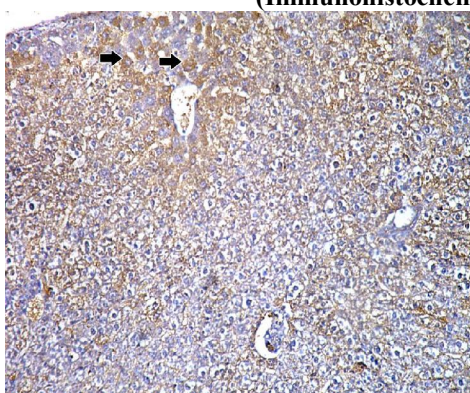




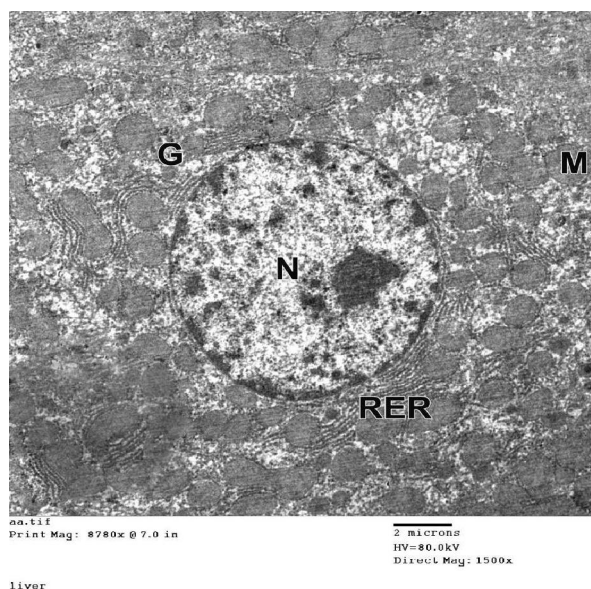
**Figure (5):** A photomicrograph of a section in hepatic lobule obtained from an adult male albino rat of the control group, showing weak TNF- $\alpha$  immunoreactivity in the hepatocytes. (Immunohistochemical x200)



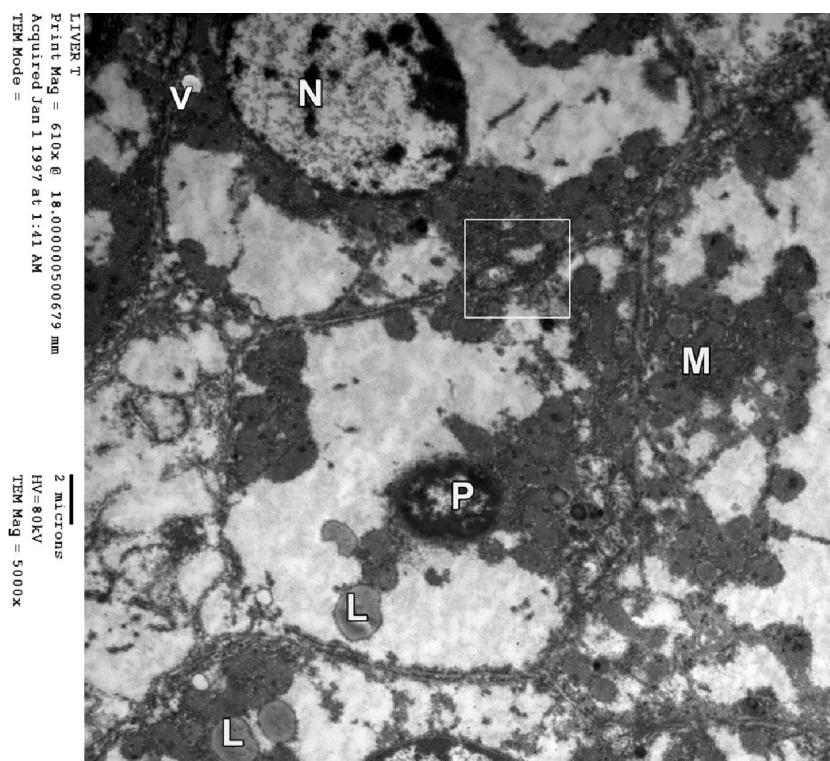
**Figure (6):** A photomicrograph of a section in hepatic lobules obtained from an adult male albino rat of the group IV (TiO<sub>2</sub>NPs treated) showing strong positive TNF- $\alpha$  immunoreaction (arrow). (Immunohistochemical x200).



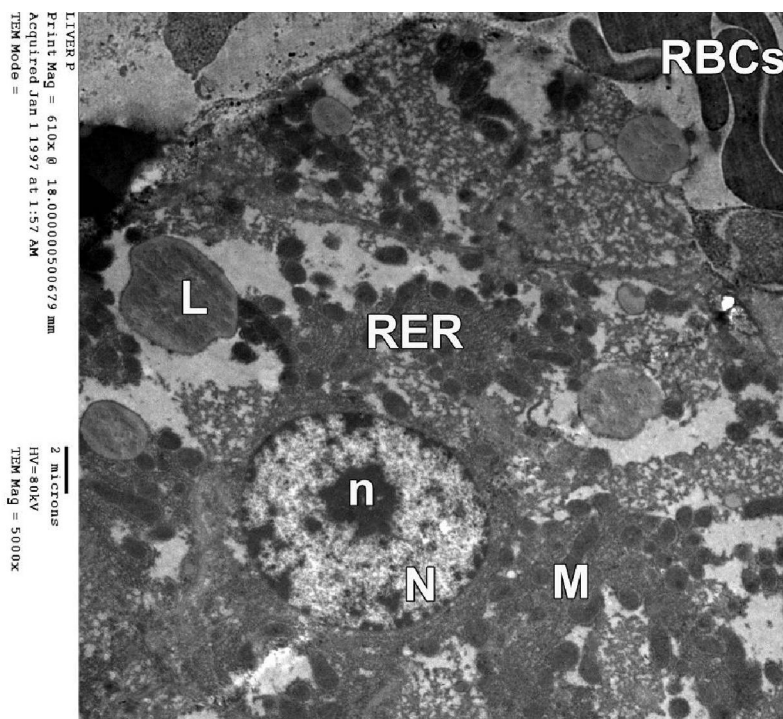
**Figure (7):** A section of hepatic lobules obtained from an adult male albino rat of the group IV (TiO<sub>2</sub>NPs treated) showing decreased TNF- $\alpha$  immuno-reactivity in the hepatocytes (arrow). (Immunohistochemical x200).



**Figure (8):** Ultrastructure of hepatocyte of an ultrathin section of the liver obtained from an adult male albino rat of the control group showing euchromatic nucleus (N). The cytoplasm contains numerous mitochondria (M), rough endoplasmic reticulum (RER) and glycogen granules (G). (TEM. Mic. X 1500)

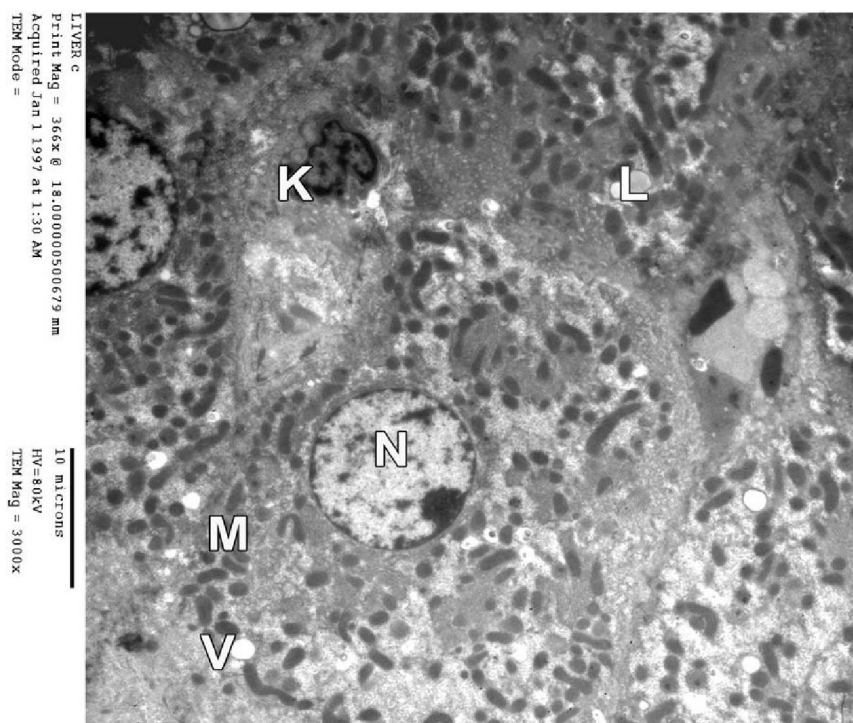


**Figure (9):** Ultrastructure of hepatocyte of an ultrathin section of the liver obtained from an adult male albino rat of the group IV (TiO<sub>2</sub>NPs treated) showing hepatocyte with pyknotic nucleus (P) and marked rarefaction of the cytoplasm (electrolucent areas). The cytoplasm contains numerous lipid droplets (L) and vacuoles (V). The intracellular space shows dilated bile canaliculi (in the square) (TEM. Mic. X 5000)

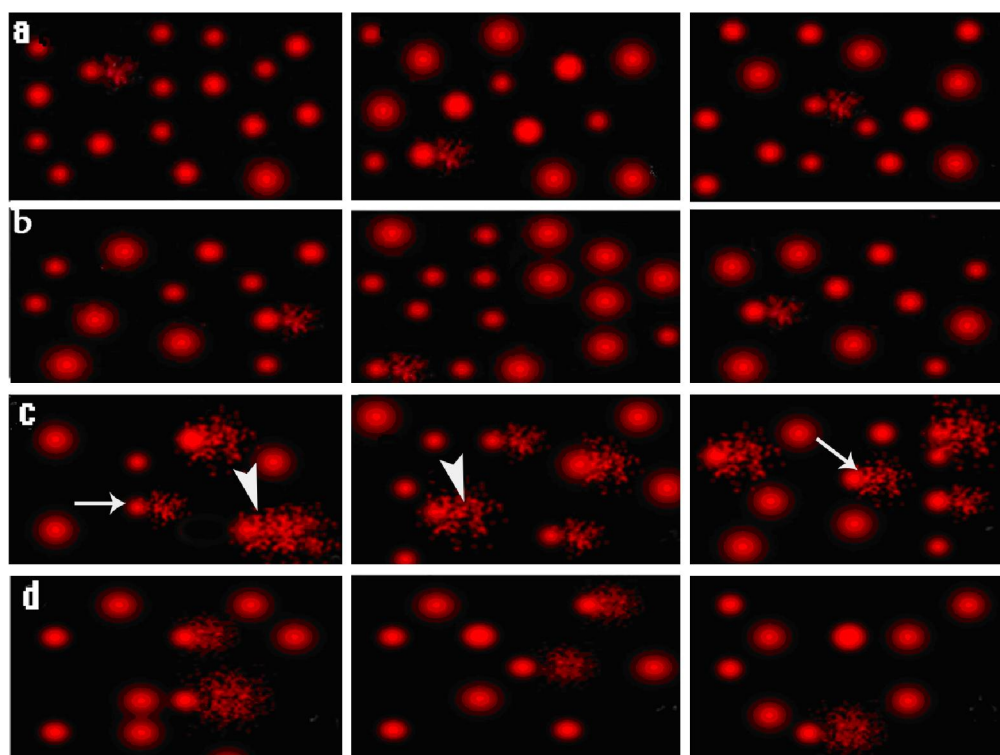


**Figure (10):** Ultrastructure of hepatocyte of an ultrathin section of the liver obtained from an adult male albino rat of the group IV (TiO<sub>2</sub>NPs treated) showing hepatocytes with euchromatic nuclei (N) with prominent nucleolus (n). The cytoplasm contains mitochondria (M) and numerous lipid droplets (L). The blood sinusoid shows congestion (RBCs). (TEM. Mic. X 3000)





**Figure (11):** Ultrastructure of hepatocyte of an ultrathin section of the liver obtained from an adult male albino rat of the group V (TiO<sub>2</sub>NPs and NAC treated) showing euchromatic nucleus (N). The cytoplasm contains mitochondria (M), lipid droplets (L), vacuoles (V) and Kupffer cell (K). (TEM. Mic. X 3000)



**Figure (12):** Comet test showing nuclei of liver cells of male rats of the control groups (a). Group III (NAC treated) shows normal condensed type nuclei & undamaged cells (b). Group IV (TiO<sub>2</sub>NPs treated) shows abnormal tailed nuclei (arrow) & damaged cells (arrow head) (c). Group V (TiO<sub>2</sub>NPs and NAC treated) shows less number of abnormal tailed nuclei & damaged cells (d).



**Table (1):** Statistical comparison of AST, ALT, TBIL, GSH and MDA mean values in different studied groups (ANOVA test & LSD test).

N= 10 rats Parameters	Group I (negative control) Mean $\pm$ SD	Group III (NAC treated) Mean $\pm$ SD	Group III (NAC treated) Mean $\pm$ SD	Group IV (TiO <sub>2</sub> NPs treated) Mean $\pm$ SD	Group V (TiO <sub>2</sub> NPs and NAC treated) Mean $\pm$ SD	F	P
AST (U/L)	11.2 $\pm$ 2.3 <sup>C</sup>	11.7 $\pm$ 2.9 <sup>C</sup>	12.4 $\pm$ 1.9 <sup>C</sup>	23.5 $\pm$ 5.1 <sup>ABD</sup>	13.5 $\pm$ 4.1 <sup>C</sup>	25.8	< 0.001 ***
ALT (U/L)	10.3 $\pm$ 2.2 <sup>C</sup>	10.4 $\pm$ 2.5 <sup>C</sup>	11.7 $\pm$ 2.0 <sup>C</sup>	19.8 $\pm$ 3.9 <sup>ABD</sup>	13.3 $\pm$ 2.0 <sup>C</sup>	28.5	< 0.001 ***
TBIL (mg/dl)	0.89 $\pm$ 0.1 <sup>C</sup>	0.89 $\pm$ 0.1 <sup>C</sup>	0.87 $\pm$ 0.1 <sup>C</sup>	0.72 $\pm$ 0.1 <sup>ABD</sup>	0.91 $\pm$ 0.1 <sup>C</sup>	9.3	< 0.001 ***
GSH (nmol/L)	50.2 $\pm$ 4.0 <sup>CD</sup>	49.1 $\pm$ 3.9 <sup>CD</sup>	52.8 $\pm$ 4.7 <sup>CD</sup>	38.2 $\pm$ 2.9 <sup>ABD</sup>	61.9 $\pm$ 3.5 <sup>ABC</sup>	81.4	< 0.001 ***
MDA (nmol/L)	74.9 $\pm$ 3.5 <sup>CD</sup>	75.0 $\pm$ 3.9 <sup>CD</sup>	73.9 $\pm$ 3.4 <sup>CD</sup>	136.3 $\pm$ 21.6 <sup>ABD</sup>	85.7 $\pm$ 6.6 <sup>ABC</sup>	65.3	< 0.001 ***

**Table (2):** Statistical comparison of Comet assay results in liver of different studied groups (ANOVA test & LSD test).

N= 10 rats Parameters	Group I (negative control) Mean $\pm$ SD	Group III (NAC treated) Mean $\pm$ SD	Group III (NAC treated) Mean $\pm$ SD	Group IV (TiO <sub>2</sub> NPs treated) Mean $\pm$ SD	Group V (TiO <sub>2</sub> NPs and NAC treated) Mean $\pm$ SD	F	P
Tailed	4.9 $\pm$ 0.9 <sup>CD</sup>	5.1 $\pm$ 0.9 <sup>CD</sup>	4.3 $\pm$ 0.5 <sup>CD</sup>	16.0 $\pm$ 0.8 <sup>ABD</sup>	7.3 $\pm$ 0.5 <sup>ABC</sup>	445.5	< 0.001 ***
Untailed %	95.1 $\pm$ 0.9 <sup>CD</sup>	94.9 $\pm$ 0.9 <sup>CD</sup>	95.7 $\pm$ 0.5 <sup>CD</sup>	84.0 $\pm$ 0.8 <sup>ABD</sup>	92.7 $\pm$ 0.5 <sup>ABC</sup>	445.5	< 0.001 ***
Tail length $\mu$ m	0.89 $\pm$ 0.02 <sup>CD</sup>	0.88 $\pm$ 0.02 <sup>CD</sup>	0.86 $\pm$ 0.03 <sup>CD</sup>	5.2 $\pm$ 0.5 <sup>ABD</sup>	2.9 $\pm$ 0.3 <sup>ABC</sup>	1490.3	< 0.001 ***
Tail DNA %	0.74 $\pm$ 0.02 <sup>CD</sup>	0.74 $\pm$ 0.02 <sup>CD</sup>	0.73 $\pm$ 0.02 <sup>CD</sup>	4.6 $\pm$ 0.7 <sup>ABD</sup>	3.4 $\pm$ 0.2 <sup>ABC</sup>	1985.3	< 0.001 ***
Unit tail moment	0.66 $\pm$ 0.04 <sup>CD</sup>	0.65 $\pm$ 0.03 <sup>CD</sup>	0.63 $\pm$ 0.03 <sup>CD</sup>	23.9 $\pm$ 3.8 <sup>ABD</sup>	10.0 $\pm$ 0.42 <sup>ABC</sup>	1529.3	< 0.001 ***

N = Number of rats for each group.

SD = Standard Deviation

U/L: Units per liter - mg/dl: milligrams per deciliter - nmol/L: nanomoles per liter - %: percent -  $\mu$ m: micrometer\*\*\*: Very Highly Significant ( $P < 0.001$ ).

A sig with group I or II, B sig with group III, C sig with group IV and D sig with group V.

#### 4. Discussion

Widespread application of nanomaterials confers enormous potential for human exposure and environmental release. While the small size of particles is what makes nanotechnology so useful in medicine and industry. It is also one of the main factors that might make them potentially dangerous to human health (Attia *et al.*, 2013). The nanosized-TiO<sub>2</sub> is used in widespread applications such as cosmetics, food colorant and white pigment as well as in the environmental decontamination of air, soil and water. (Medina *et al.*, 2007). TiO<sub>2</sub>NPs exposure can migrate through different routes and accumulate in body tissues which, in turn, can cause inflammation and apoptosis, ultimately resulting in organ injury and failure. Moreover, it has been suggested that there is also potential for TiO<sub>2</sub>NPs to induce reactive oxygen species (ROS) thus causing oxidative DNA damage (Gao *et al.*, 2013).

The results of the present work showed that TiO<sub>2</sub>NPs induced several histological alterations in the liver. Hepatic lobules architecture was disorganized with sever congestion in the sinusoidal spaces and numerous Kupffer cells as well as, lymphocytic aggregation (nodule). Hepatocytes showed marked vacuolation and pyknotic nuclei.

According to Linglan *et al.* (2009), TiO<sub>2</sub> induced liver toxicity and hepatic inflammatory responses that are complicated multifactorial disease processes. The inflammatory cytokines cascade may cause inflammatory cell chemotaxis and apoptosis, resulting in serious liver injury. Moreover, nanoparticles that enter the rat liver induced oxidative stress locally. Hence, the cellular damage and oxidative stress of nanoparticles in the liver cells were related to the particle size and chemical compositions of nanoparticles (Hoet *et al.*, 2004). Nemmar *et al.* (2011) also found that hepatic damage induced by

TiO<sub>2</sub>NP in forms of histological changes particularly, hepatic fibrosis, hydropic and fatty degeneration of hepatocytes, prominent vasodilatation, and focal ischemia could lead to impaired liver function and infiltration of inflammatory cells. The inflammatory reaction in response to NPs insult was also confirmed by significant increase of both mRNA and protein expression levels of several inflammatory cytokines and mediators in the liver (**Ma et al., 2009** and **Cui et al., 2011**).

Moreover, degeneration of hepatocytes, lymphocyte clusters, neutrophils and monocytes concentrated at portal area with hepatic sinusoid dilation were detected in this work. **Li et al. (2010)** have reported that TiO<sub>2</sub>NPs possess pro-inflammatory properties similar to those exhibited by other nanomaterials. While **Ma et al. (2009)** have revealed that TiO<sub>2</sub>NPs induced the apoptosis of the hepatocytes and speculated that the apoptosis induction may be through the mitochondrion-mediated pathway. Mitochondrial pathway can be activated by a diverse range of stimuli, including reactive oxygen species (**Guo et al., 2009b**).

In the present work examination of liver ultrathin sections of TiO<sub>2</sub>NPs treated group revealed different degrees of affection. The most affected hepatocytes appeared with pyknotic nuclei, numerous fat droplets and many vacuoles. The intercellular space shows dilated bile canaliculi and congestion. These results supported with the electron microscopic findings of **Cui et al. (2010)** who suggested that TiO<sub>2</sub>NPs could induce hepatocyte damage and oxidative stress of the liver as evidenced by hepatocyte apoptosis in the form of mitochondria swelling and chromatin condensation and alteration of expression levels of the genes involved in antioxidative enzymes or detoxification.

Interestingly, **Ma et al. (2010)** stated that TiO<sub>2</sub>NPs is no longer freely distributed in the cytoplasm after internalized by cells but is preferentially located in the mitochondria. When the mitochondria are invaded by the TiO<sub>2</sub>NPs, the antioxidant defense ability could be altered. The apoptosis induced by nano-TiO<sub>2</sub> possibly resulted from ROS, which was caused by the TiO<sub>2</sub>NPs, also reduction of antioxidative defenses (such as GSH reduction) (**Cui et al., 2010**).

The tumor necrosis factor-alpha (TNF- $\alpha$ ) is a cytokine produced mainly by activated macrophages, and in minor quantities by several other types of cells. It is capable of inducing different biological responses and it plays a role in inflammation, stress response and apoptosis (**Klarić et al., 2009**). Accordingly, in the present study immunohistochemical staining for TNF- $\alpha$  was used and examination of the liver sections of TiO<sub>2</sub>NPs treated group showed positive TNF- $\alpha$  immunoreaction in the hepatocytes. However

administration of NAC with TiO<sub>2</sub>NPs revealed decreased TNF- $\alpha$  immuno-reactivity in the hepatocytes.

These findings were supported with the results of **Shin et al. (2010)** who stated that TiO<sub>2</sub> significantly elevated proinflammatory cytokine interleukin-1 $\beta$  and TNF- $\alpha$ . TNF- $\alpha$  can induce ROS and stimulate the induction of various genes involved in inflammation including interleukin-8 (IL-8). TNF- $\alpha$  also depletes cellular GSH which is a cellular antioxidant (**Mater et al., 2010**). Moreover, **Palomäki et al. (2010)** found that exposure of macrophages to TiO<sub>2</sub>NPs strongly enhanced the expression of IL-6 and TNF- $\alpha$ . In addition, **Park et al. (2009)** found that treatment with TiO<sub>2</sub>NPs lead to significant induction of the proinflammatory cytokine, TNF- $\alpha$  in a dose-dependent manner. In an *in vitro* study, they demonstrated that TiO<sub>2</sub>NPs enhanced the expressions of inflammation-related genes, such as TNF- $\alpha$ .

Also, AST is a mitochondrial and cytoplasmic enzyme in the liver and is also present in high concentration in other tissues while ALT is a cytoplasmic enzyme in the liver, where it presents in a higher concentration than in other tissues. It is considered more specific for liver damage. Transaminases are most useful in the diagnosis and monitoring of hepatocellular disease (**Alfahdawi, 2011**).

In the present study, there was a significant increase in AST and ALT mean values in TiO<sub>2</sub>NPs treated group as compared to their corresponding values in control groups and NAC treated group.

Most nanoparticles tend to accumulate in the liver (**Sadauskas et al., 2007**) and lead to liver damage or injury. The damages of liver function occurred by nanosized-TiO<sub>2</sub>, evidenced by the increased activities of AST and ALT. Hence liver enzymes increase during liver dysfunction indicating severe inflammation or liver injury (**Chen et al., 2009**). On the contrary, **Fabian et al. (2008)** failed to show any hepatic toxicity in rats treated with injection of TiO<sub>2</sub>NPs. Also, negative results in terms of alteration in liver parameters were reported by **Liang et al. (2009)** in rats treated with a single intratracheal instillation of TiO<sub>2</sub>NPs. Interestingly, in this study, even if functional and histological liver lesions could not be demonstrated, hepatic superoxide dismutase activity (SOD) activity was reduced, and MDA levels were increased suggesting a possible role of oxidative stress and lipid peroxidation generated by nanoparticles exposure.

The quantification of bilirubin in combination with liver enzyme tests may allow a differentiation between different types of jaundice. Despite its limitations, bilirubin is still widely used for clinical routine assessment of liver function (**Sakka, 2007**). In

the present study, there was a significant decrease in TBIL mean values in TiO<sub>2</sub>NPs treated group as compared to their corresponding values in control groups and

The results of the present work are supported by the work of **Liu *et al.* (2009)** and **Duan *et al.* (2010)**. On the other hand, there was no alteration in TBIL detected by **Fabian *et al.* (2008)** in rats treated with injection of a mixture of anatase and rutile TiO<sub>2</sub>NPs.

**Tomaro & Batlle (2002)** reported that although bilirubin is generally regarded as a potentially cytotoxic, lipid-soluble waste product that needs to be excreted. However, many *in vitro* and *in vivo* studies, have demonstrated that bilirubin exhibits potent antioxidant properties preventing the oxidative damage triggered by a wide range of oxidant-related stimuli. Therefore, the idea of a beneficial and physiological role for bilirubin in cytoprotection against short and long-lasting oxidant-mediated cell injury is highlighted here. Additionally, **Fouad *et al.* (2009)** reported that bilirubin has a higher free radical-scavenging activity than other physiological antioxidants as vitamin C and  $\alpha$ -tocopherol. Also, it was revealed that bilirubin depletion markedly augments tissue levels of reactive oxygen species and causes apoptotic cell death (**Baranano *et al.*, 2002**). Such antioxidant activity can be explained by the fact that bilirubin oxidized into biliverdin is recycled back by biliverdin reductase deriving a powerful redox cycle that allows for continuous cytoprotection against oxidative stress (**Florczyk *et al.*, 2008**).

In the present study, there was a significant decrease in GSH mean values in TiO<sub>2</sub>NPs treated group as compared to their corresponding values in controls. The results of the present study revealed time dependent depletion in GSH level in TiO<sub>2</sub>NP treated rats. These findings were coincided with **Shukla *et al.* (2011)** who observed glutathione depletion and an increase in the lipid peroxidation levels after exposure to TiO<sub>2</sub>NPs which indicates oxidative stress.

Reactive oxygen species generation has been proposed as a possible mechanism involved in the toxicity of NPs findings and showed a good correlation between ROS and oxidative stress markers (**Shukla *et al.* 2011**). **Jeon *et al.* (2013)** speculated that part of the ROS generation might be due to the catalytic properties of nanosized-TiO<sub>2</sub>. The overproduction of ROS would break down the balance of the oxidative/antioxidative system in the tissues, resulting in the lipid peroxidation via ROS and MDA production, which may be closely related to the reduction of antioxidative enzymes as well as non-enzymatic antioxidants like ascorbate and GSH.

In the present study, there was a significant increase in MDA mean values in TiO<sub>2</sub>NPs treated group as compared to their corresponding values in

controls. Combined administration of NAC with TiO<sub>2</sub>NPs caused a significant increase in mean values of MDA.

Corresponding to the significant changes of MDA levels suggest that the histological changes are likely to be mediated through the oxidative stress induced by the deposited nanoparticles. These results were consistent with **Attia *et al.* (2013)** study that showed time dependent significant generation of oxidative stress in the liver. This was evident by an increased MDA and decreased GSH.

The comet assay is a widely used assay in fundamental research for DNA damage and repair, genotoxicity testing of novel chemicals and pharmaceuticals, environmental biomonitoring and human population monitoring. (**Arora *et al.*, 2012**).

In the present study comet assay performed on the liver specimens revealed a significant increase in DNA damage of TiO<sub>2</sub>NPs treated group nuclei as compared to controls. These results are in agreement with **Shukla *et al.* (2011)** who found that TiO<sub>2</sub>NPs generate ROS and oxidative stress leading to DNA damage and genotoxicity in mammalian cells. The direct correlation between ROS generation and oxidative DNA damage further suggests that oxidative stress could act as an important route by which TiO<sub>2</sub>NPs induce DNA damage. The possible mechanisms for TiO<sub>2</sub>NPs-induced genotoxicity involve DNA damage directly or indirectly via oxidative stress inflammatory responses, direct chemical interaction between TiO<sub>2</sub> nanoparticles and DNA, through the DNA phosphate group and/or generation of reactive oxygen species (**Singh *et al.*, 2009** and **Shi *et al.*, 2013**).

On the other, in the present work concomitant use of NAC along with TiO<sub>2</sub>, light microscopic examination as well as electron microscopic ultrathin sections examination- of liver sections revealed regression of the histological changes of the hepatic and tissues. Significantly restored the values of liver function tests and oxidative stress markers. Moreover, immunohistochemical examination showed diminished TNF- $\alpha$  immuno-reactivity. Also NAC administration significantly lowered the level of DNA damage in nuclei of liver.

NAC had promoted the cell growth and survival in response to ROS-induced injuries which normally lead to growth arrest and apoptosis. **Sadowska *et al.* (2007)** stated that NAC is an antioxidant with free radical scavenging properties. Additionally, NAC is a source of cysteine, the precursor of de novo GSH synthesis. So, administration of NAC replenishes intracellular GSH levels. Furthermore, NAC inhibits the release of TNF- $\alpha$ , the activation of proinflammatory cytokines, and cellular apoptosis (**El-Sayed *et al.*, 2010**). These results are coincident with



**Attia et al. (2013)** study which stated that co-treatment with NAC together with TiO<sub>2</sub> normalized the increase in AST, ALT, MDA and decrease in GSH levels confirming the protective effect of NAC. Also histological examination of the liver showed disappearance most of the degenerative changes induced by TiO<sub>2</sub>. These findings were in accordance with **Zafarullah et al. (2003)**.

**Conclusion:** It was concluded that TiO<sub>2</sub>NPs oral administration induced toxic effects and DNA damage in the liver that may be attributable to oxidative stress, and administration of NAC with TiO<sub>2</sub>NPs offers protection against their damaging effect.

**Recommendations:** Further studies are needed to assess NAC antioxidant potentials and limitations. Also we need to explore novel thiol antioxidant that possess better pharmacokinetics properties.

#### Corresponding author:

Osama Yasein Ibrahim Mohamed  
Histology and cell Biology Department  
Faculty of Medicine, Zagazig Unversity  
Email: [Usay2003@yahoo.com](mailto:Usay2003@yahoo.com)

#### References

1. Alfahdawi HY (2011) Estimation of some haematological parameters and enzymes activity transaminase for some arthritis patients who used voltaren drug in AL-Ramadi city Tikrit J of Pure Science 16 (4): 28-30.
2. Arora S Rajwade JM and Paknikar KM (2012) Nanotoxicology and *in vitro* studies: the need of the hour Toxicology and Applied Pharmacology 258(2): 151-165.
3. Attia HF Soliman MM Abdel-Rahman GH Abdo Nassan M Ismail SA Farouk M and Solcan C (2013) Hepatoprotective effect of N-acetylcysteine on the toxic hazards of titanium dioxide nanoparticles American Journal of Pharmacology and Toxicology 8 (4): 141-147.
4. Bancroft ID and Cook HC (1994) Immunohistochemistry In: Manual of Histological Techniques and Their Diagnostic Applications, Churchill Living Stone, Edinburgh, London, Madrid, Melbourne, New York and Tokyo:263
5. Bancroft JD Gamble M (2008) Theory and practice of histological techniques. 6<sup>th</sup> ed. Philadelphia, PA: Churchill Livingstone.
6. Baranano DE Rao M Ferris CD Synder SH (2002) Biliverdin reductase: a major physiologic cytoprotectant Proc Natl Acad Sci USA 10,99 (25):16093-16098.
7. Barnard AS (2010) One-to-one comparison of sunscreen efficacy, aesthetics and potential nanotoxicity Nat Nanotechnol 5: 271-274.
8. Bhan A (1995): Immunoperoxidase In: Diagnostic immunopathology 2ed. ed. Raven Press Ltd, New York, pp: 711-715.
9. Brunet L Lyon DY Hotze EM Alvarez PJJ Wiesner MR (2009) Comparative photoactivity and antibacterial properties of C60 fullerenes and titanium dioxide nanoparticles Environ Sci Technol 43(12): 4355-4360.
10. Chen J Dong X Zhaoa J Tang G (2009) *In vivo* acute toxicity of titanium dioxide nanoparticles to mice after intraperitoneal injection J Appl Toxicol 29(4): 330-337.
11. Cui Y Gong X Duan Y Li N Hu R Liu H Hong M Zhou M Wang L Wang H Hong F (2010) Hepatocyte apoptosis and its molecular mechanisms in mice caused by titanium dioxide nanoparticles J of Hazardous Materials 183(1-3): 874-880.
12. Cui Y Liu H Zhou M Duan Y Li, N Gong X Hu R Hong M Hong F (2011) Signaling pathway of inflammatory responses in the mouse liver caused by TiO<sub>2</sub> nanoparticles J of Biomedical Materials Research A 96(1): 221-229.
13. Duan Y Liu J Ma L Li, N Liu H Wang J Zheng L Liu C Wang X Zhao X Yan J Wang S Wang H Zhang X Hong F (2010) Toxicological characteristics of nanoparticulate anatase titanium dioxide in mice Biomaterials 31(5): 894-899.
14. El-Sayed el-SM Abdel-Aziz AA Helal GK Saleh S. Saad AS (2010) Protective effect of N-acetylcysteine against carmustine-induced myelotoxicity in rats Food and Chemical Toxicology 48(6): 1576-1580.
15. Fabian E Landsiedel R Ma-Hock L Wiench K Wohlleben W and van Ravenzwaay B (2008) Tissue distribution and toxicity of intravenously administered titanium dioxide nanoparticles in rats Archives of Toxicology 82(3): 151-157.
16. Florczyk UM Jozkowicz A Dulka J (2008) Biliverdin reductase: new features of an old enzyme and its therapeutic significance Pharmacol. Rep 60(1): 38-48.
17. Fouad AA Qureshi HA Al-Sultan AI Yacoubin MT Ali AA (2009) Protective effect of hemin against cadmium-induced testicular damage in rats Toxicology 257(3): 153-160.
18. Gao G Ze Y Zhao X Sang X Zheng L Ze X Gui S Sheng L Sun Q Hong J Yu X Wang L Hong F Zhang X (2013) Titanium dioxide nanoparticle-induced testicular damage, spermatogenesis suppression, and gene expression alterations in male mice J of Hazardous Materials 15,258-259: 133-143.
19. Glauret AM Lewis PR (1998) An introduction to fixation and embedding procedures and their safe use in the laboratory. In: Biological specimen preparation for transmission electron microscopy. Vol.17. By: Glauret, A.M. (ed.) Portland press, London, pp: 15-20.
20. Guo X Li T Wang Y Shao, L Zhang Y Ma D Han W (2009b) CMTM5 induces apoptosis of pancreatic cancer cells and has synergistic effects with TNF- $\alpha$  Biochem and Biophys Res Commun 387(11): 139-142.
21. Hoet PH Brske-Hohlfeld I Salata OV (2004) Nanoparticles-known and unknown health risks J of Nanobiotechnol 2: 12.
22. Hu YL Gao JQ (2010) Potential neurotoxicity of nanoparticles Int J Pharm 394: 115-121.
23. Iavicoli I Leso V Bergamaschi A (2012) Toxicological Effects of Titanium Dioxide Nanoparticles: A Review of *In Vivo* Studies J of Nanomaterials ID 964381 36.
24. Jain S Kumar CH Suranagi UD Mediratta, PK (2011) Protective effect of N-acetylcysteine on bisphenol A-induced cognitive dysfunction and oxidative stress in rats Food and Chemical Toxicology 49(6): 1404-1409.
25. Jeon JM Kim WJ Lee MY (2013) Studies on liver damage induced by nanosized-titanium dioxide in mouse J Environ Biol 34: 283-287.
26. Kaplan A Rubaltelli FF.; Hammerman C Vilei MT Leiter C Abramov A (1984) Bilirubin. Clin Chem The C.V. Mosby Co. St Louis Toronto. Princeton. pp: 1238-1241.

27. Klarić M Tao S Stoka V Turk B. Turk V (2009) Cysteine cathepsins are not critical for TNF- $\alpha$ -induced cell death in T98G and U937 cells *Biochim Biophys Acta (BBA) - Proteins & Proteomics* 1794(9): 1372- 1377.
28. Li N Ma L Wang J Zheng L Liu J Duan Y Liu H Zhao X Wang S Wang H Hong F Xie Y (2010) Interaction between nano-anatase TiO<sub>2</sub> and liver DNA from mice *in vivo* *Nanoscale Res Lett* 5(1): 108–115.
29. Liang G Pu Y Yin L Liu R Ye B Su Y Li Y (2009) Influence of different sizes of titanium dioxide nanoparticles on hepatic and renal functions in rats with correlation to oxidative stress *J of Toxicology and Environ Health A* 72(11-12): 740–745.
30. Liu H Ma L Zhao J Liu J Yan J Ruan J Hong F (2009) Biochemical toxicity of nanoanatase TiO<sub>2</sub> particles in mice *Biol Trace Elem Res* 129(1–3): 170–180.
31. Ma L Zhao J Wang J Liu J Duan Y Liu H Li N Yan J Ruan J Wang Hong F (2009) The acute liver injury in mice caused by nanoanatase TiO<sub>2</sub> *Nanoscale Res Lett* 4(11): 1275-1285.
32. Ma L Liu J Li N Wang J Duan Y Yan J Liu H Wang H Hong F (2010) Oxidative stress in the brain of mice caused by translocated nanoparticulate TiO<sub>2</sub> delivered to the abdominal cavity *Biomaterials* 31(1): 99–105.
33. Markowska-Szczupak, A Ulfing K Morawska AW (2011) The application of titanium dioxide for deactivation of bioparticulates: an overview *Catalysis Today* 169(1): 249-257.
34. Mater MG Calzetta L Cazzola M (2010) TNF- $\alpha$  inhibitors in asthma and COPD: we must not throw the baby out with the bath water *Pulm Pharmacol Ther* 23(2): 121-128.
35. Medina C Santos-Martinez MJ Radomski A Corrigan OI Radomski MW (2007) Nanoparticles: pharmacological and toxicological significance *Br J Pharmacol* 150:552-558. PMID: 17245366.
36. Moron MS Depierre JW Manervik B (1979) Levels of glutathione, glutathione reductase and glutathione-S-transferase activities in rat lung and liver *Biochim Biophys Acta* 582(1): 67-68.
37. Murray R (1984a) Aspartate aminotransferase; In: *Clinical Chemistry*, Eds., Kaplan, A. and AL Peace, The C.V. Mosby Co., St Louis, Toronto, Princeton, pp:1112-1116.
38. Murray R. (1984b): Alanine aminotransferase; In *Clinical Chemistry*, Eds., Kaplan A, AL Peace, The C. V. Mosby Co., St Louis, Toronto, Princeton, pp:1088-1090.
39. Nemmar A Melghit K Al-Salam S Zia S Dhanasekaran S Attoub S Al-Amri I Ali BH (2011) Acute respiratory and systemic toxicity of pulmonary exposure to rutile Fedoped TiO<sub>2</sub> nanorods *Toxicology* 279(1–3): 167–175.
40. Palomäki J Karisola P Pylkkanen L Savolainen K Alenius H (2010) Engineered nanomaterials cause cytotoxicity and activation on mouse antigen presenting cells *Toxicology* 267(1-3):125-131.
41. Park EJ Yi J Chung KH Ryu DY Choi J Park K (2008) Oxidative stress and apoptosis induced by titanium dioxide nanoparticles in cultured BEAS-2B cells *Toxicol Lett* 180(3): 222-229.
42. Sadauskas E Wallin H Stoltenberg M Vogel U Doering P *et al* (2007): Kupffer cells are central in the removal of nanoparticles from the organism *Part Fibre Toxicol* 4: 10.
43. Sadowska AM Manuel-y-Keenoy B De Backer WA (2007) Antioxidant and anti-inflammatory efficacy of NAC in the treatment of COPD: discordant in vitro and in vivo dose-effects: a review *Pulm Pharmacol Ther* 20(1): 9–22.
44. Sakka SG (2007) Assessing liver function *Current Opinion in Critical Care* 13(2):207–214.
45. Shi H Magaye R Castranova V Zhao J (2013) Titanium dioxide nanoparticles: a review of current toxicological data *Particle and Fibre Toxicology* 10:15.
46. Shin JA Lee EJ Seo SM Kim HS Kang JL Park EM (2010) Nanosized titanium dioxide enhanced inflammatory responses in the septic brain of mouse *Neuroscience* 165(2): 445–454.
47. Shukla RK Sharma V Pandey AK Singh S Sultana S Dhawan A (2011) ROS-mediated genotoxicity induced by titanium dioxide nanoparticles in human epidermal cells *Toxicol In Vitro* 25(1): 231-241.
48. Singh NP McCoy MT Tice RR Schneider EL (1988) A simple technique for quantitation of low levels of DNA damage in individual cells *Exp Cell Res* 175(1): 184-191.
49. Singh N Manshian B Jenkins GJ Griffiths SM Williams PM Maffei TG Wright CJ Doak SH (2009) NanoGenotoxicology: the DNA damaging potential of engineered nanomaterials *Biomaterials* 30(23-24):3891-3914.
50. Tomaro ML Battle AM (2002) Bilirubin: its role in cytoprotection against oxidative stress *Int J Biochem Cell Biol* 34(3):216-220.
51. Vamanu CI Cimpan MR HØI PJ SØrnes S Lie SA Gjerdet NR (2008) Induction of cell death by TiO<sub>2</sub> nanoparticles: studies on a human monoblastoid cell line *Toxicol In Vitro* 22(7): 1689-1696.
52. Wang JX Fan YB Gao Y Hu QH. Wang TC (2009) TiO<sub>2</sub> nanoparticles translocation and potential toxicological effect in rats after intraarticular injection *Biomaterials* 30(27): 4590–4600.
53. Yoshioka T Kwada K Shimada T Mori M (1979) Lipid peroxidation in maternal and cord blood and protective mechanisms against elevated oxygen toxicity in the blood *Am J Obstet Gynecol* 135(3):372–376.
54. Zafarullah M Li WQ Sylvester J Ahmad M (2003): Molecular mechanisms of N-acetylcysteine actions *Cell Mol Life Sci* 60(1): 6-20.
55. Zhang Y Qi T Zhang Y (2009) A novel preparation of titanium dioxide from titanium slag *Hydrometallurgy* 96(1-2): 52- 56.

5/26/2015