

Multi-Imaging Modalities in Evaluation of Recipient's Non-Vascular Complications after Living Donors Liver Transplantation

Wafik Ebrahim¹; Mohammad A. Yusuf El-Shazely¹; Amr Ahmed Mostafa¹; Ahmad A. Fotouh Al-Daly¹; Mokhtar Ragab Ramadan¹; Mohamed A. Abdel-Razek¹; Gaber M Bakheet²

¹Radiology Department, Faculty of medicine Al-Azhar University Egypt

²Surgery Department, Faculty of medicine Al-Azhar University Egypt

Wafik7373@hotmail.com

Abstract: *Objective:* We evaluate the role of the different imaging modalities in postoperative assessment of recipients of living donor liver graft. *Methods:* 30 patients were included. They underwent routine laboratory and radiological investigations. Ultrasound and Doppler are the corner stone tools. CT scan was performed for suspected vascular abnormalities. MRCP, PTC and/ or ERCP were performed for biliary system abnormality. *Results:* we met the following non-vascular complications; significant abdominal collections and pleural effusion (33.3% for each), rejection (30%), and biliary tract complications (26.7%). The mortality rate was 30%. Ultrasound was sufficient for assessment of collections and helped in the suspicious of rejection (*P* value 0.014 for portal blood pulsatility and 0.000 for portal blood velocity). It was efficient in detecting dilated biliary radicles but MRCP had the upper hand in detecting level of obstruction. Doppler US was efficient in assessment of vascular channels and CTA was efficient in excluding vascular abnormalities when there is unexplained clinical or laboratory abnormality. *Conclusion:* An imaging algorithm should be put in mind in the postoperative follow up of patients. US and Doppler were able to detect most of complications. MRCP was accurate in assessment of biliary tract obstruction. ERCP and PTC are effective diagnostic and therapeutic tools.

[Wafik Ebrahim; Mohammad A. Yusuf El-Shazely; Amr Ahmed Mostafa; Ahmad A. Fotouh Al-Daly; Mokhtar Ragab Ramadan; Mohamed A. Abdel-Razek and Gaber M Bakheet. **Multi-Imaging Modalities in Evaluation of Recipient's Non-Vascular Complications after Living Donors Liver Transplantation.** *J Am Sci* 2014;10(5):73-83]. (ISSN: 1545-1003). <http://www.jofamericanscience.org>. 11

Key words: Rejection of liver graft. Living donor liver transplantation. Biliary complications of Living donor liver transplantation

Abbreviations and Acronyms: CT- Computed tomography, CTA- computed tomographic angiography, HCC- Hepatocellular carcinoma, LDLT- Living donor liver transplantation, MRCP- Magnetic resonance cholangiopancreatography, MPR- Multiplanar reformat, MIP- Maximum intensity projection. PTC- percutaneous transhepatic cholangiography, US- Ultrasound,

1. Introduction

In the 1960s and the 1970s, liver transplantation was slowly developed to become a feasible option in the treatment of end-stage liver disease and by 1984, it became accepted as curable treatment for these patients⁽¹⁾.

The regenerative power of the liver was first described by the Greeks more than 2,500 yr ago⁽²⁾. This process is central to the success of surgical resections and live donor transplantation⁽³⁾. The unique segmental anatomy of the liver allows it to be separated into independent anatomic units able to retain normal function⁽⁴⁾.

The use of a live donor for liver transplantation was first attempted in 1987, by Raia⁽⁵⁾ and the first successful live donor liver transplant was reported that same year in Australia by Strong⁽⁶⁾.

The principal advantages of LDLT are the optimal selection of donors, minimal graft preservation injury due to synchronous performance

of donor and recipient operations and electively scheduled operation before clinical deterioration of the patient ensues. The main disadvantage is that without any doubt, ethical issues have been derived from that fact that healthy donors are placed at potential risk of partial liver resection and general anaesthesia⁽⁷⁾.

Indications for liver transplantation:

The list of indications for liver transplantation includes all the causes of end stage liver disease which are irreversible and curable by the procedure.

Liver transplantation was contraindicated when there is uncontrolled active extra-hepatic sepsis, extra-hepatic malignancy, advanced cardiorespiratory disease, drug abuse, significant irreversible brain injury or medical non-compliance⁽⁷⁾.

Living donor liver transplantation, despite being the only curable treatment for end stage liver disease, may be associated with some complications. These range from mere postoperative pain or simple

postoperative collection to rejection of graft or death. The recipient complications after LDLT are classified into vascular, biliary, and other complications.

The role of imaging in the follow up after living donor liver transplantation (LDLT) is a corner stone in predicting and improving the outcome. The different imaging modalities have to detect any complication as early as possible to allow timed intervention, if needed, to prevent deterioration and alleviate bad outcome. Our project aimed to clarify this role and to detect the ideal tool for each complication.

2. Patients and methods:

2.1 Patients:

This prospective study was conducted on 30 patients submitted for living donor liver transplantation in Dar Al-Fouad hospital, 6th of October city Giza during the period from November 2011 to July 2013. Written informed consent was obtained from the patients included in this study. They were 29 males (96.6%) and 1 female (3.4%). Their ages ranged from 33 to 61 years with mean age of 52. All patients were followed up for 12 months and all data were calculated and tabulated.

2.2 Methods:

2.2.1 Laboratory assessment:

All patients were submitted for routine postoperative laboratory assessment including complete liver function and bilirubin level in fluids coming from the surgical drains.

2.2.2 Ultrasound:

Ultrasound and Doppler assessment were done using Seimens Sonoline G 60S and GE logic 3 PRO machines by curved abdominal probe 3.5-5MHz with colour and spectral Doppler facilities. The assessment was done twice daily during the stay in the ICU, once daily during the stay in the wards, once weekly for the first month after discharge from hospital and then twice monthly for 6 months. The assessment was directed to the hepatic parenchymal echogenecity (for areas of congestion), biliary tree (for dilatation) and detection of collection (with assessment of amount, turbidity and septations) using grey scale. Hepatic circulation was also assessed. The portal circulation is examined from the splenic vein and superior mesenteric veins up to the portal vein main trunk and its intrahepatic branches with attention to the site of anastomosis. These veins were first examined by grey scale for detection of intraluminal thrombi or stricture at anastomotic site. Then colour Doppler coding and spectral Doppler were recorded at the portal vein (preanastomotic site, anastomotic site and postanastomotic site for measurement of portal blood velocity (PBV) and detection of pulsatile flow. Hepatic artery is assessed at hepatic hilum and

intrahepatic branches (for anastomotic stenosis or thrombosis). The hepatic arterial peak systolic velocity, acceleration time (at the anastomotic site and preanastomosis) and resistive index (at hepatic hilum and intrahepatic branches) were measured. Hepatic veins patency and spectral waveform were also assessed.

Some difficulties were experienced with US assessment due to abdominal dressing, distended bowel loops at the examination field and patient respiratory movements.

These studies (laboratory and US) were sufficient for clinically stable patients and no more investigations are indicated. However, when there is any deviation from normal finding, further imaging and work up were done according to the detected abnormality. Also when there is discrepancy between the clinical data, laboratory data and imaging finding further assessment was performed. On detecting vascular abnormality or when there is unexplained laboratory abnormality CT scan and/or CTA was obtained.

Biliary tracts complications were the indication for imaging of the biliary system using specific algorithm. When there is hyperbilirubinemia or high bilirubin in surgical drains, T tube cholangiogram was done and when leakage was confirmed, ERCP and stenting were done. Conjugated hyperbilirubinaemia and / or US detectable dilatation of the biliary radicles was the indication for MRCP and when stricture was identified, ERCP or PTC and stenting were done.

Rejection of the graft was diagnosed by pathological assessment of liver biopsy or by clinical response to full dose of antirejection drugs after exclusion of other complication by the radiological imaging.

2.2.3 CT scan:

Fifteen patients were examined by multiphasic CT scan using 128-channel multi-detector row CT scanner (Seimens Definition Dual Source).

The patient's laboratory data were initially revised specially the renal function tests. Pre and post-contrast studies were obtained. The timing of imaging after contrast administration is determined by computer automated scanner technology (bolus tracking). The post-contrast series was done following the injection of contrast medium using an automatic pump with a volume ranging between 120 to 150ml according to the patient's weight (1.5-2ml/kg) at a flow rate of 4-5ml/sec. The contrast medium used was low osmolar non-ionic contrast medium (Ultravist 370mg). The CT scan was performed by using a 2.5mm nominal section thickness, a slice pitch of 6, a gantry rotation period 0.6 second, and a table speed of 15mm per rotation. X-ray tube voltage was 120 KV, and the

current was 280-300mA. The arterial phase starts about 18-20 sec post-injection till the end of the 20cm distance then after a delay of 8 sec the portal dominant phase is started similarly as the 1st one (about 40 sec post-injection). Then the 3rd and 4th phases (venous phase) are started after a delay of 10 sec from the end of the 2nd phase to end the whole examination. The whole examination took 68sec. The 1st phase of examination is designated to assess the celiac trunk, hepatic artery and superior mesenteric arteries. Then the second phase was designated to assess the portal venous system. The last phase is designated to visualize the IVC and the hepatic veins. Venous graft, if present, is also assessed for patency.

All images were transferred to the workstation for post processing. Reconstructions using 3D maximum intensity projections (MIP), volume rendering (VR) and curved planar reformations were created to obtain CT angiographies for the hepatic circulation. Multiplanar reconstruction (MPR) was also done in coronal and sagittal images.

2.2.4 Magnetic Resonance Cholangiography (MRC):

Five patients with biliary system dilatation (detected by ultrasound) underwent MR imaging using 1.5-T MR system (Intera Achieva; Philips Medical Systems).

In addition to undergoing MRC, the subjects underwent routine breath-hold transverse T1-weighted in and opposed phase gradient-echo MRI and T2-weighted TSE MRI with fat saturation for localization of the biliary ducts. Two methods of MRC for evaluation of the biliary anatomy were used. Sequence parameters of MRC were chosen according to the protocols optimized by the vendor. First, 2D breath-hold single-slice rapid acquisition with relaxation enhancement (RARE) was acquired by using the following parameters: repetition time in milliseconds/echo time in milliseconds, 9817/920; flip angle, 90-degree; number of signal averages, 1; matrix, 308-256; echo train length, 256; slice thickness, 4 mm; field of view, 35-35cm²; acquisition time, 9.8 seconds for each slice; and coronal and -15-degree oblique coronal orientation resulting in 9 slices. Second, respiratory-triggered 3-dimensional (3D) TSE using a respiratory belt placed on a patient's abdomen was acquired by using the following parameters: repetition time/echo time, 2500/740; flip angle, 90-degree; number of signal averages, 1; matrix, 256-512; echo train length, 100; slice thickness, 1 mm; field of view, 30-35cm²; SENSE factor, 2; acquisition time, 2 to 5min depending on respiratory frequency.

2.2.4 T tube cholangiogram:

Four patients underwent T tube cholangiogram (using Seimens Axiom Iconos R200 machine) through injection of 10-20ml telebrix

through the biliary T tube under screen and spot views are taken in antero-posterior and oblique views.

2.2.5 Percutaneous transhepatic cholangiogram (PTC):

Three patients underwent PTC (using Toshiba Infinix software version V3.52*R005 and Seimens Axiom Artis).

2.3 The statistical methodology:

Data were statistically described in terms of mean standard deviation (SD), median and range, or frequencies (number of patients) and percentages when appropriate. Comparison of numerical variables between the study groups was done using Student t test for independent samples. For comparing categorical data, Chi square (2) test was performed. Exact test was used instead when the expected frequency is less than 5. Within group comparison was done using Mc Nemar test while agreement was done using kappa statistic. *P* values less than 0.05 was considered statistically significant. All statistical calculations were done using computer programs SPSS (Statistical Package for the Social Science; SPSS Inc., Chicago, IL, USA) version 15 for Microsoft Windows.

3 Results:

3.1 Indications of LDLT:

Analysis of preoperative recipient data revealed that 90% of patients (27 patients) had HCV related cirrhosis, 6.7 % of patients (2 patients) had cryptogenic cirrhosis and 3.3 % of patients (1 case) had veno-occlusive disease related cirrhosis. In addition among the patients with HCV related cirrhosis 3 patients had co-infection with HBV and 4 patients had HCC.

3.2 postoperative complications:

The postoperative morbidity in our study was 66.6% while 33.4 % passed uncomplicated. We considered mild pleural effusion and mild ascites detected in the early postoperative days as accepted finding.

The incidence of different complications was presented in Fig 1. It should be clear that many patients may experience multiple complications. Significant pleural effusion and ascites were the most common complications in our study.

3.2.1 Significant pleural effusion:

Pleural effusion was considered significant when it was moderate to marked resulting in respiratory distress or necessitating thoracocentesis. It was reported in 33.3 % of patients (10 patients). Two patients underwent thoracocentesis to alleviate respiratory distress and eight patients improved spontaneously.

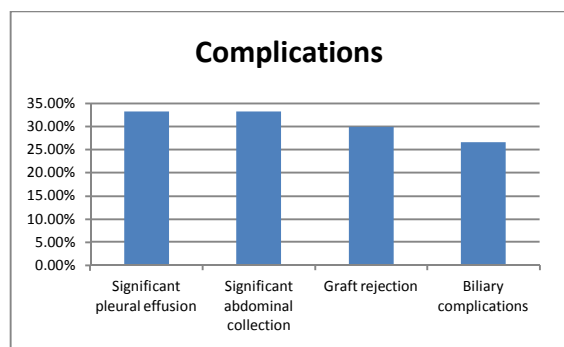


Fig. (1): Illustrates the incidence of variable complications plotted in percentage.

3.2.2 Significant abdominal collection:

Ascites was considered significant when it was moderate to marked or persistent after two weeks. Also persistent or progressive encysted collection was considered significant (Fig. 2).

3.2.3 Graft rejection (Fig 3 and 4):

The incidence of rejection in our study was 30 % (9patients). 7 patients developed rejection within the first two postoperative months and 2 patients developed rejection during 2-6 postoperative months.

Doppler US has a crucial rule is suspicion of graft rejection. The portal blood velocity (PBV) is usually fluctuating on the post-operative period.

Table 1 illustrates the PBV in patients with rejection compared to non rejected grafts.

The PBV significantly declined in rejected grafts to a mean velocity of 12.89cm/sec with 3.6 SD compared to non-rejected grafts that showed a mean PBV of 21.86 cm/sec with 4.1 SD (Table 1).

Fig 3 shows that $PBV \leq 15$ cm/sec is strongly associated with rejection and rejection is rare when $PBV > 20$ cm/sec.

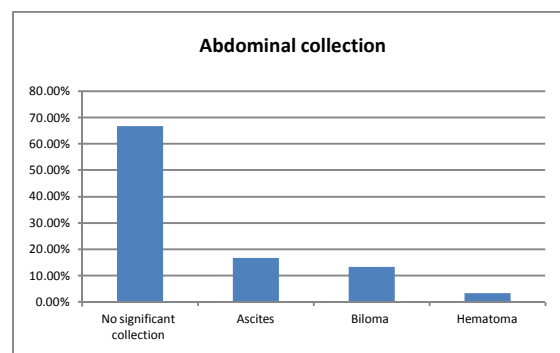


Fig. (2): Illustrates distribution of abdominal collection regarding its nature plotted in percentage.

Table (1): Illustrates the variation of PBV in rejected and non rejected grafts and its independent tests

Rejection	Mean	No. of patients	Std. deviation	Min. (cm/sec)	Max. (cm/sec)	Median
No rejection	21.86	21	4.102	16	30	20.00
rejection	12.89	9	3.621	7	18	14.00

NB: P value was 0.000 indicant significant relations.

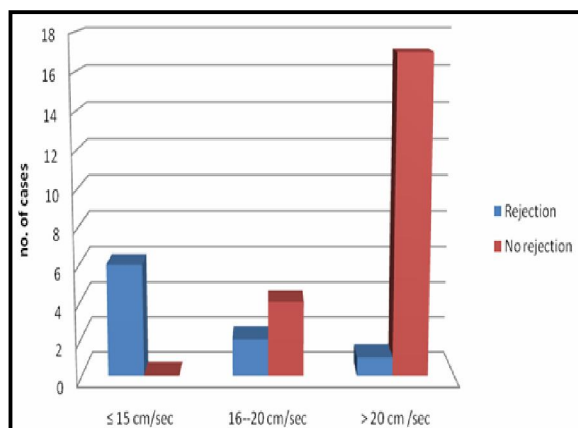


Fig. (3): Illustrates the relationship between rejected and non-rejected grafts regarding PBV.

Portal blood flow is usually non pulsatile. Pulsatility of portal blood flow was found in our study to be strongly correlated with rejection. It was detected in 7 patients (23.3%) five of them had

rejected grafts. Also pusatility was found to be rare in non-rejected grafts.

The table (2) shows the relation between portal vein pulsatility and rejection using cross tabulation by Chi Square test.

Table (2): Cross tabulation of portal vein pulsatility and rejection

PV pulsatility		Acute rejection		Total
		No	Yes	
No	Count	19	4	23
	% within Acute rejection	90.5%	44.4%	76.7%
Yes	Count	2	5	7
	% within Acute rejection	9.5%	55.6%	23.3%
Total	Count	21	9	30
	% within Acute rejection	100.0%	100.0%	100.0%

NB: P value in cross tabulation of portal vein flow pulsatility against rejection was 0.014 indicating significant relation.

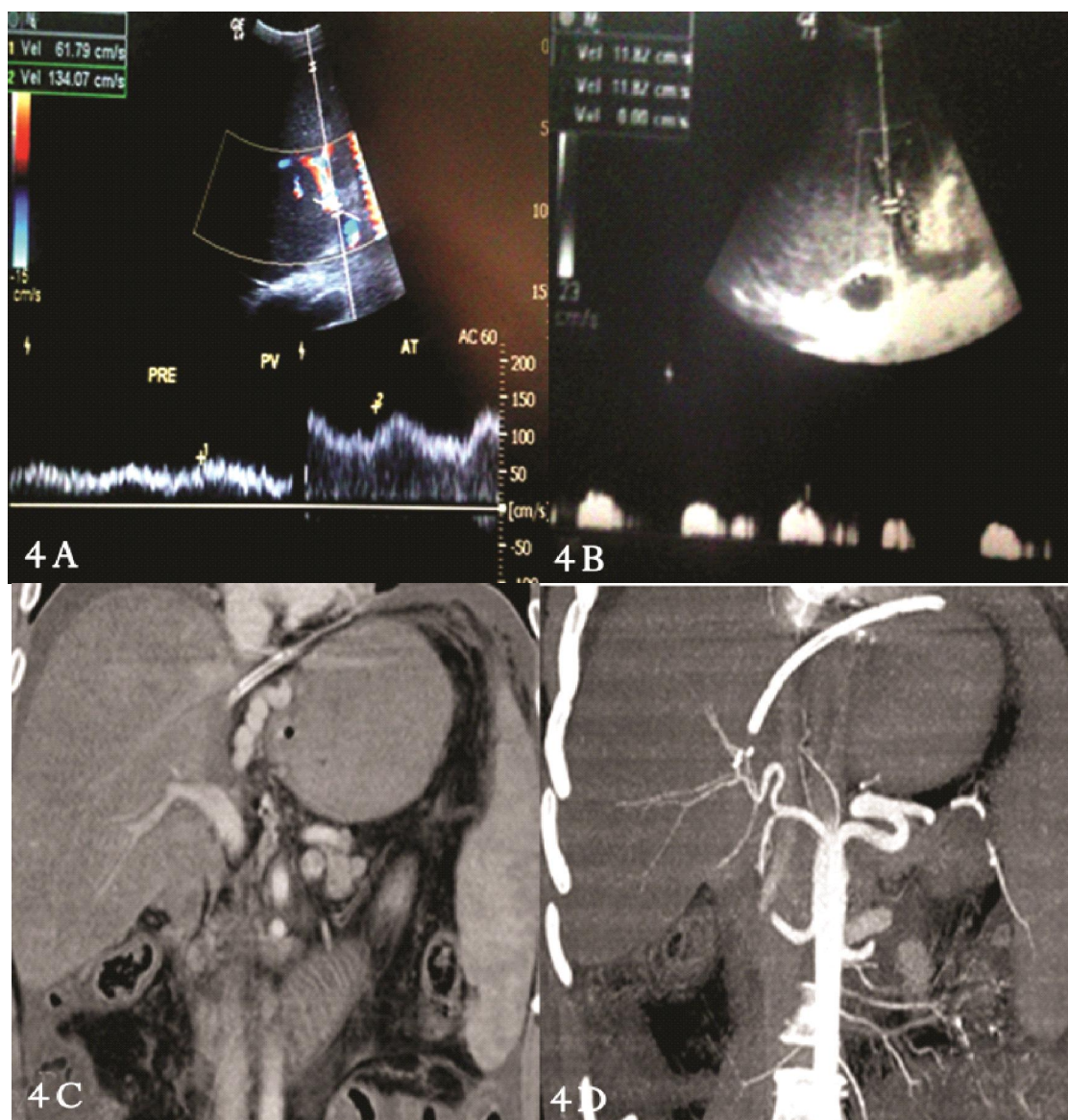


Fig. 4.(A~D) Male patient 52 years old presented after LDLT with abnormal liver functions and Doppler finding. Rejection was confirmed by biopsy. Spectral Doppler US images (A & B) show pulsatile portal blood flow and velocity doubling across the anastomosis 61/134 cm/sec.(A). 10 days later image shows periodic dampened portal flow with peak velocity of 11 cm/sec.(B). Reconstructed CT images (C&D) Coronal portal phase MPR (C) and Coronal MIP arterial phase (D) show patent portal vein and patent hepatic artery.

3.2.4 Biliary tract complications:

Biliary tract complications were seen in 8 patients (26.6%). Four patients had biliary leak and

five patients had bile duct stricture (one patient suffered from combined biliary leak and stricture).

Table 3 illustrates the date of onset of biliary stricture.

Table (3): Onset of biliary duct stricture.

Biliary stricture onset	No. of patients	Percentage
Early (3-6 months)	1	20
Late (6-12 months)	4	80
Total	5	100

The first imaging presentation of bile duct stricture is dilated proximal intrahepatic bile radicles (Fig 5). MRCP was then done in these 5 patients followed by ERCP/ PTC for therapeutic indications. We noticed that US and MRCP have excellent

diagnostic ability for the detection of dilated biliary radicles. There is was no false positive results where all patients with dilated biliary system submitted for golden standard PTC/ ERCP which confirmed the dilatation.

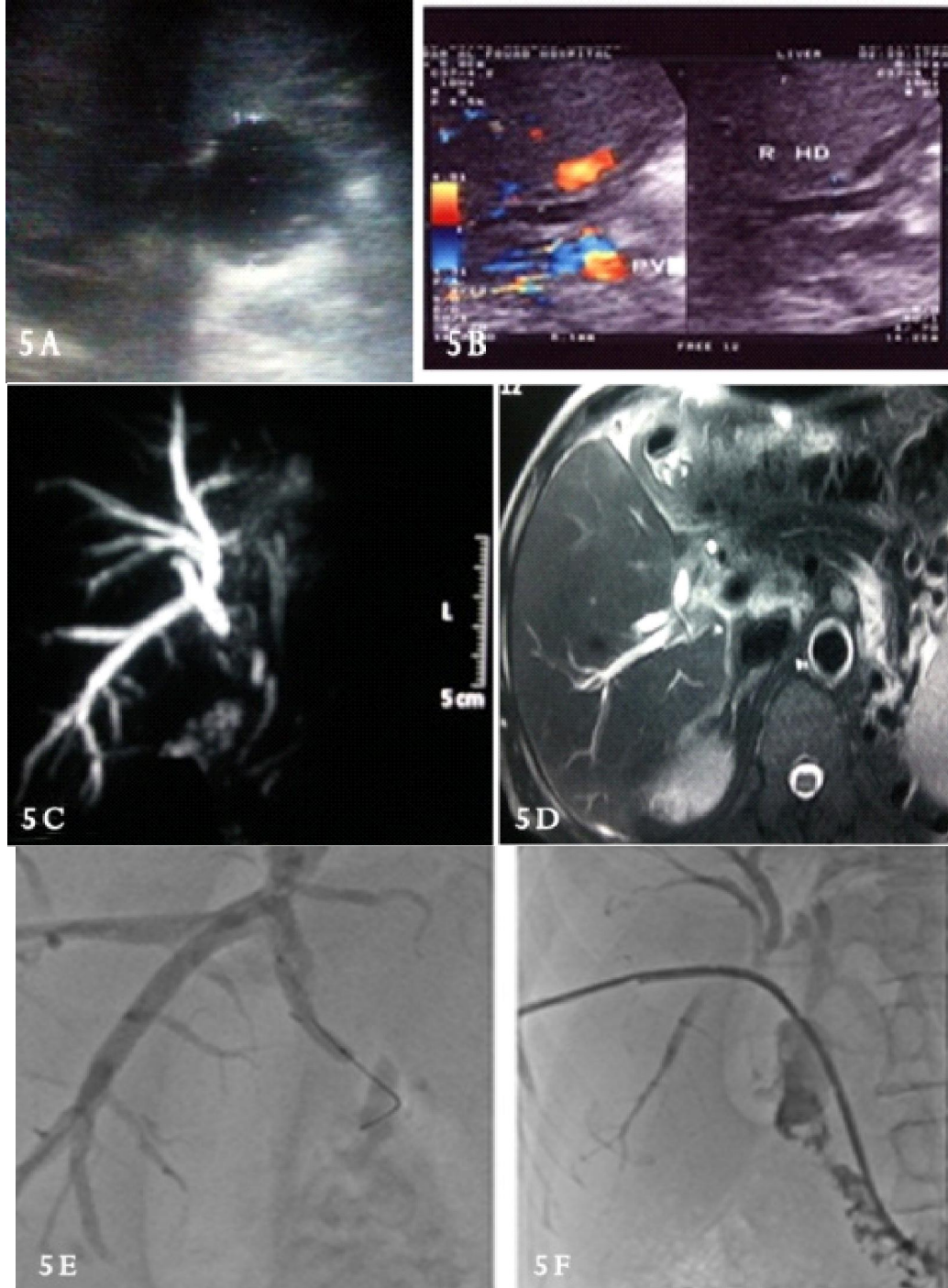


Fig. 5. (A~F): Male patient 52 years presented 7 months postoperative by high serum bilirubin level. (A&B) Axial ultrasound images showing small collection at portahepatis (A) and dilated posterior biliary radicles(B). MRC Volume rendering (C) and axial T2 WI (D) show anastomotic biliary stricture and dilated intrahepatic biliary system. (E&F); PTC images show anastomotic biliary stricture (E) and successful stent placement (F).

Table 4 presents time of detection of the biliary leak.

Table (4): Time of detection of biliary leak onset

Biliary leak date	No. of patients	Percentage
1 st month	3	75
2-6 month	1	25
Total	4	100

The biliary leak was suspected by high bilirubin in level in fluids coming from surgical drains and or encysted septated collection near portahepatis (Fig 6). It was noted in 4 patients. 3 of them had early onset

leak that confirmed by T tube cholangiogram and the last case had combined stricture and leak that were confirmed by ERCP done late postoperative period.

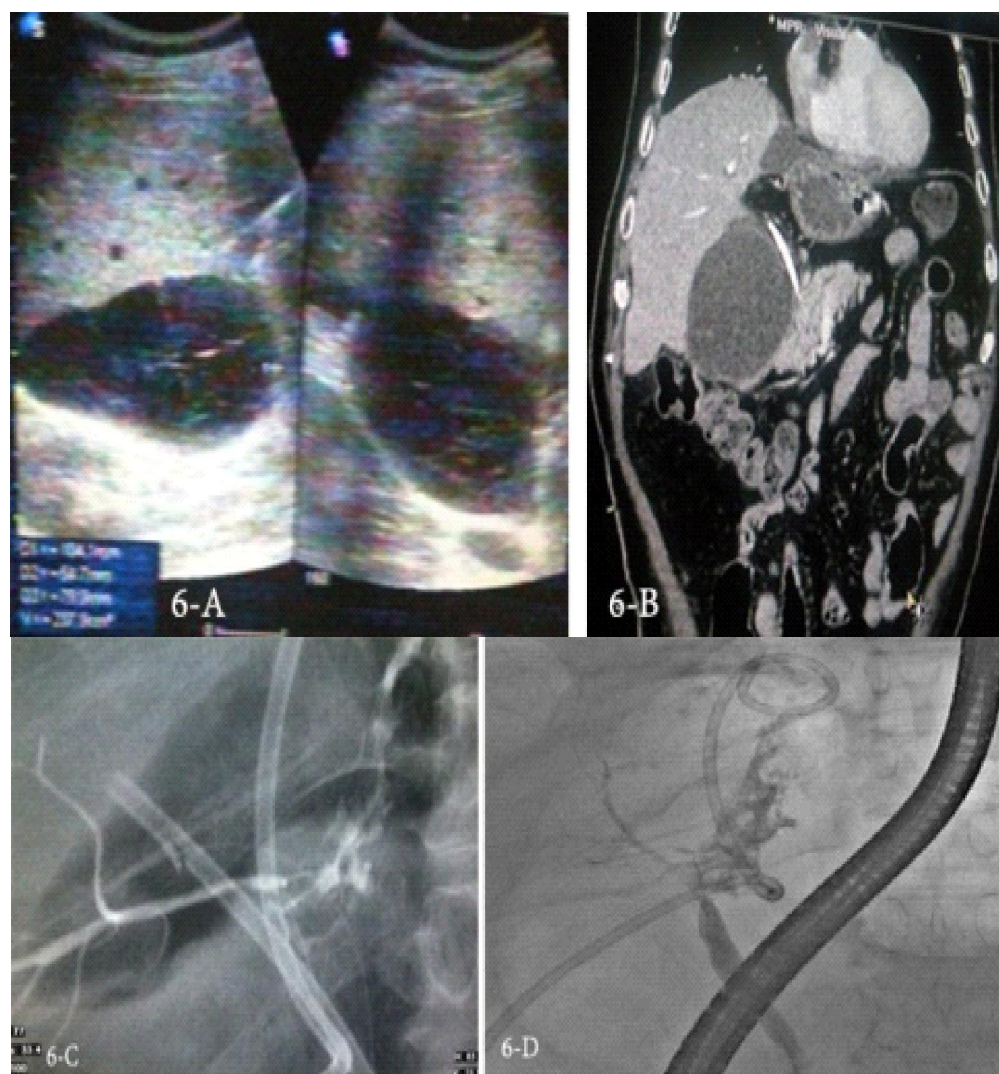


Fig. 6. (A~D): 45 Male patient presented 6 weeks after LDLT by hyperbilirubinemia and high bilirubin in fluid coming from surgical drains. B mode ultrasound (A) and coronal post contrast CT (B) show encysted collection close to portahepatis. The CT scan was obtained after placement of a stent at bile duct. T tube cholangiogram (C) and ERCP (D) show biliary leak at anastomotic site.

3.3 Mortality:

The overall mortality rate in our study was 30 % (9 patients). 4 patients died during the first month and 5 patients died 2-6 months after surgery. The cause of death was variable. Graft failure (5 patients), sepsis (3 patients) and unrelated cause (1 patient) were encountered.

4. Discussion:

Liver transplantation proved itself with time to be the only curable treatment for end stage liver disease. Living donor liver transplantation (LDLT) has also presented itself in comparison to cadaveric liver transplantation. The LDLT is the only accepted technique in Egypt because of religious and moral issues.

Although improved surgical techniques and immunosuppressive therapy have greatly increased the success rate of hepatic transplantation, there are still a number of significant, potentially life-threatening complications. Postoperative imaging has a major role in early depiction of these complications allowing timed intervention. This study aimed to assess the role of different modalities in detection and follow up of these complications to identify the best tool for every operative adverse effect.

Liver transplantation has many indications, which are variable in different areas of the world. HCV related cirrhosis was found in our study to be the most common indication accounting for 90%. Although the cause of end stage liver disease is variable in different countries, viral hepatitis remains an important cause all over the world. Nadalin and his colleagues⁽⁸⁾ found that liver cirrhosis, secondary to HCV, represents only 30-50% of indications for liver transplantation in European and American countries.

The reported non-vascular complications in this study were rejection of graft, biliary complications, significant pleural effusion and significant abdominal collection.

Significant abdominal collection and significant pleural effusion were the most common complications accounting for 33.3% for each of them. Most of patients were treated conservatively. One case (3.3%) with pleural effusion required insertion of pig tail under US guidance to reduce the associated respiratory distress. Biloma was seen in 4 patients (13.3%) with proved biliary leak. Only one case of bilomas necessitated US guided drainage (25% of bilomas). Haematoma was seen in one case (3.3%) at the site of hepatic vein anastomosis and managed by exploration and haemostasis. These complications were also documented in other research works. Shimul and his colleagues⁽⁹⁾ found that pleural collections requiring drainage was detected in 3%, abdominal collection in

7%, hematoma managed by relaparotomy and haemostasis in 4% and biloma 3% of patients. A possible explanation for the difference between the incidence of abdominal collection between our study and the study of Shimul and his colleagues,⁽⁹⁾ may be attributed to our restrict criteria that include persistent ascites or pleural effusion after two weeks post transplantation. Significant ascites and significant pleural effusion were regained to impaired graft functions either due to rejection or major vascular insult.

Graft rejection was the second most common complication (30%). Some patients responded well to modification of antirejection therapy and others suffered from severe rejection that ended in graft failure and death. Doppler US being a daily follow up tool can be investigated to assess its efficiency in early detection of rejection. We used portal vein pulsatility and portal blood velocity (PBV) in the study to be expectant for rejection. They usually reflect resistivity in liver parenchyma which is suspected to be increased in swollen rejected graft. The normal portal blood flow is of high velocity during early postoperative days then declines to normal values. Also the flow is usually continuous monophasic flow with slight respiratory modulation. We plotted the PBV against the condition of the graft whether it is rejected or not. We noticed that PBV is significantly lower among patients with rejected graft ranging from 7 to 18cm/sec (mean of 12.8cm/sec with 3.6 standard deviation) with estimated P-value 0.000 (significant relation). On the other hand rejection was rare when PBV exceeded 20cm/sec.

Pulsatility of blood flow was also more encountered among patients with rejection. It was detected in 7 patients 5 of them were found suffering from rejection. On the other hand 23 patients in this study showed non pulsatile monophasic flow 4 of them had rejection with estimated P value 0.014 indicating significant relation.

Leong⁽¹⁰⁾ said that acute rejection is the most common and most serious complication affecting graft survival. The incidence of acute rejection ranges from 17% to 40%.

Batts and his fellows,⁽¹¹⁾ and Klar and his colleagues,⁽¹²⁾ postulated that acute rejection is characterized by a number of histologic abnormalities, and most of them are potentially able to increase portal venous resistance and to obstruct portal blood flow. These abnormalities are related to inflammation with packing of the portal tract by inflammatory cells, supra-endothelial and subendothelial lymphocytic infiltration in either portal or central veins (i.e., endotheliitis), centrilobular hepatocyte necrosis, and central

hepatocellular ballooning (swelling)^(11, 12). The increase in intrahepatic resistance results in a decrease in both liver microperfusion⁽¹²⁾ and total hepatic blood flow⁽¹³⁾. As a consequence, changes in portal-hepatic Doppler US parameters might be expected during acute rejection⁽¹⁴⁾. The issues about whether these changes are sufficiently large to be detected with Doppler US and whether they are specific to acute rejection are not clear⁽¹⁴⁾.

On the contrary, Kok and his colleagues⁽¹⁵⁾ compared a group of nine patients with acute rejection and a group of 14 patients without acute rejection and did not find any significant difference in PBV behavior.

Lee and his colleagues⁽¹⁶⁾ did a study for Doppler finding in acute rejection, composed of 47 patients with biopsy proved rejection and 47 control group without rejection. They also reached to similar results to what we have noted. They noted that pulsatile venous flow was more encountered in patients with rejection than in patients without rejection with estimated *P* value of 0.001.

The Doppler findings in rejection are an aspect of controversy and we recommend detailed specific studies on large groups for further investigation. In our study we tried to do a correlation between PBV and rejection and we found a strong relation. However a strong conclusion that can use a cutoff point to diagnose rejection couldn't be drawn because of the low statistical power of this study regarding the number of patients with rejection.

The biliary tract complications in our study accounted for 26.7 %. These complications are noted also in many other research works at different incidences. Bak and his colleagues⁽¹⁷⁾ in a study composed of 41 patients found that biliary complication rate was 34%. Miller and his fellows⁽¹⁸⁾ in a study composed of 109 patients found that biliary complication rate was 25%. As such the variation in the incidence of complication was reported in many theses. Actually it is variable in the same center at different periods.

The biliary complications that reported in our study were biliary leak (13.3%) and biliary stricture (16.7%). The biliary leak was detected early in first postoperative month in 75% of patients and detected late in 25%. T-tube cholangiogram was done in the 3 patients with early onset biliary leak that revealed non anastomotic leak in 1 case and anastomotic leak in 2 patients. The case that developed delayed onset biliary leak was submitted for ERCP that showed coexisting leak and stricture at the anastomotic site. The case with non anastomotic leak underwent hepaticojejunostomy and partially improved but unfortunately died from sepsis. The other three patients with anastomotic leak underwent ERCP

where stenting was done that improved one case and failed in 2 patients. This failure was explained by concomitant non anastomotic leak which was indication for hepaticojejunostomy and unfortunately the 2 patients died later due to sepsis.

Biliary stenosis was seen in 16.7 % of patients and was a late onset complication with 80 % of patients developed the stricture 6-12 months after surgery. All patients with biliary stricture showed biliary system dilatation by US and MRCP but level of stricture was definitely detected by MRCP only. MRCP also was more accurate in detecting length of stenotic segment and was informative road map for therapeutic procedures. Patients with biliary stricture (n=5) were treated by stenting guided by either ERCP (n=2) or PTC (n=3). All patients of stricture are improved on stenting apart from one case with concomitant leak that underwent biliary reconstruction and died from sepsis. Qian and his colleagues⁽¹⁹⁾ studied 230 patients to evaluate postoperative biliary tract complication and its risk factors. The overall biliary complication rate was 20.7%. The biliary leak rate was 7.6% while the biliary stricture rate was 16.2%. In their study most of patients (7.1%) that developed biliary leak, developed it early (median, day 16). On the other hand most patients that developed stricture developed it lately (median, day 129). These results are comparable to our result.

The US was able to diagnose biliary tract obstruction in all patients with stricture which was also confirmed by other imaging modalities (MRCP, ERCP and PTC). In contrast to our results Zeopf and his colleagues⁽²⁰⁾ found a low sensitivity of US in detection of post-transplantation stricture (close to 50%).

Our results were comparable to Hussaini and his colleagues⁽²¹⁾ who reported a high negative predictive value (95%) of transabdominal US in the diagnosis of biliary tract complications. They assume that a normal ultrasonography makes the presence of biliary complications unlikely. Anyhow our study, with low number of biliary strictures, can't draw a strong conclusion of US sensitivity and specificity in diagnosis of post transplantation biliary stricture.

MRCP was accurate in diagnosis of biliary stricture after liver transplantation and these results were compatible with many authors. Zeopf and his colleagues⁽²⁰⁾ found that MRCP is the best non-invasive tool for detection of bile duct stricture and its level. Berrocai and his colleagues⁽²²⁾ reported a sensitivity of 93%, specificity of 92%, a positive predictive value of 86% and a negative predictive value of 96% for MRCP in detecting biliary complications after liver transplantation.

Nine of our patients died during the study period with estimated mortality rate of 30%. Graft failure and sepsis were the most common cause of death in this work.

Actually as we noticed the mortality rate is variable in many centers according to variation in surgical skills, medical causes and infection control. Even it is variable in the same center over variable time. In our center 316 patients underwent LDLT from 2001 to 2012. The mortality rate in the 1st five years from 2001 to 2005 was 38.9% (44 from 113 patients) where the mortality rate was 33.5% (56 from 164 patients) in the 2nd five years from 2006 to 2010.

Another important issue in patient survival is the availability of retransplantation which is usually not available in our country. The European liver transplant registry ⁽²³⁾ studied the mortality rate in different European transplantation centers and found that many patients are salvaged due to availability of retransplantation.

5. Conclusion:

Finally we conclude that an imaging algorithm should be put in mind in the postoperative follow up of patients. This algorithm includes a combination of US, CT scan, MRI, and interventional biliary imaging in conjugation with laboratory findings and under umbrella of clinical overview. Despite its limitation US Doppler is sensitive in detecting most of complications including vascular, biliary and parenchymal complication with special emphasis on its predicting role in rejection. CT and CTA are sensitive and specific in vascular and parenchymal abnormality. MRCP is sensitive and specific modality for diagnosis of biliary stricture specifically detecting the site of stricture. PTC and ERCP have excellent role in detecting biliary leak plus their effective therapeutic value.

In our study we met some drawbacks which limit the conclusion in some significant events due to low number of patients with some complications. So we recommend a dedicated research for rejection and the role of Doppler US in its diagnosis aiming to reach a strong conclusion about cutoff point for PBV as a predictive for rejection.

Corresponding author

Wafik Ebrahim Ali

Egypt. Cairo. New Cairo city. First assembly
Northern investors Area number 15 building 6 B flat
No 32.

El-Hussein university hospital. Egypt. Cairo. El-Darasa. Al-Azhar (Gawhar El-kaeed) Street.

Tel: 00201006608439

Email: Wafik7373@hotmail.com

References:

1. Starzl TE. NIH Consensus Development Conference Statement: (1984): Liver transplantation. *Hepatology*; 4:1075.
2. Pichlmayr R, Ringe B, Gubernatis G, Hauss J. and Bunzendahl H. (1988): Transplantation of a donor liver to 2 recipients (splitting transplantation): a new method in the further development of segmental liver transplantation. *Langenbecks Arch Chir*; 373(2):127-130.
3. Sander Florman and Charles M. Miller. (2006): Live donor liver transplantation. *Liver transplantation*; 12:499 – 510.
4. Pomfret E.A, Pomposelli J.J, Jenkins R.L. (2001): Live donor liver transplantation. *Journal of Hepatology*; 34: 613-624.
5. Raia S, Nery JR, Mies S (1989): Liver transplantation from live donors [letter]. *Lancet* 2 (8661):497
6. Strong RW, Lynch SV, Ong TH (1990). Successful liver transplantation from a living donor to her son. *N Engl J Med* 322:1505–1507.
7. Tanaka K, Ametani F, Itoh K, Shibata T, Maetani Y, and Konishi J (2001) Spectrum of CT findings in pediatric patients after partial liver transplantation. *Radiographics* 21:53–63.
8. Nadalin S., Bockhorn M., Malagó M., Valentin-Gamazo A., Frilling A. and Broelsch CE. (2006): Living donor liver transplantation. (HPB) (Oxford). 8 (1): 10–21
9. Shimul AS., Gary AL., Lesley DA., Gary G. and David RG. (2006): Adult-to-adult living donor liver transplantation. *Gastroenterol.* 20(5): 339-343.
10. Leong L. (2006). Ultrasound of living donor liver transplantation. *Biomed Imaging Interv*; 2(2):e17doi: 10.2349/bii.2.2.e17
11. Batts KP. (1999) Acute and chronic hepatic allograft rejection: pathology and classification. *Liver Transpl Surg* (4):S21-S29.
12. Klar E, Angelescu M, Zapletal C, Kraus T, and Herfarth C. (1999): Impairment of hepatic microcirculation as an early manifestation of acute rejection after clinical liver transplantation. *Transplant Proc*; 31:385-387.
13. Gadano A., Durand F., Degott C., Dosquet C., Moreau R., Hadengue A., Widmann JJ., Vachery F., Elman A., Sogni P., Yang S., Valla D., Bernuau J., Belghiti J., Erlinger S., and Lebrech D. (1997): Studies of portal hemodynamics and hepatic oxygen consumption during acute liver allograft rejection. *Transplantation* 64:1188-1192.
14. Mohr H., Gödderz W., Lohse AW., Gerken G., and Meyer zum Büschenfelde KH. (1995): Duplex ultrasound in diagnosis and monitoring

- of liver transplant rejection. *Lancet*; 346:315-316.
15. Kok T., Slooff MJ., Peeters PM., Zwaveling JH., Bijleveld CM., Gi-van Loon CE., Klompmaaker IJ. And Haagsma EB. (1996): Changes in portal hemodynamics and acute rejection in the first 2 weeks after orthotopic liver transplantation: a prospective Doppler ultrasound study. *Invest Radiol*; (12):774-780.
 16. L SJ., Kim KW., Kim JH., Kim SY., Lee JS., Kim HJ., Jung DH., Song GW., Hwang S., Yu ES., Lee J. and Lee SG. (2011): Doppler Sonography of Patients with and Without Acute Cellular Rejection After Right-Lobe Living Donor Liver Transplantation. *Journal of Ultrasound in Medicine*. (6): 845-851
 17. B., Wachs M., Trotter J., Everson G., Trouillot T., Kugelmas M., Steinberg T. and Kam I. (2001): Adult-to-adult living donor liver transplantation using right-lobe grafts: results and lessons learned from a single-center experience. *Liver Transpl* (8):680-686.
 18. M., Gondolesi GE., Florman S., Matsumoto C., Muñoz L., Yoshizumi T., Artis T., Fishbein TM., Sheiner PA., Kim-Schluger L., Schiano T., Shneider BL., Emre S. and Schwartz ME. (2001): One hundred nine living donor liver transplants in adults and children: a single-center experience. *Ann Surg*; 234(3):301-311.
 19. *QArch Surg*. 139(10): 1101-1105.
 20. Z., Maldonado-Lopez EJ., Hilgard P., Dechêne A., Malago M., Broelsch CE., Schlaak J. and Gerken G. (2005): Diagnosis of biliary stricture after liver transplantation: which is the best tool? *World J Gastroenterol*; 11(19)2945-2948.
 21. Hussaini SH, Sheridan MB, Davies M. (1999): The predictive value of transabdominal ultrasonography in the diagnosis of biliary tract complications after orthotopic liver transplantation. *Gut*; 45: 900-903.
 22. Berrocai T, Parron M, Alvarez-Luque A, (2006). Pediatric liver transplantation: a pictorial essay of early and late complications. *Radiographics* 26:1187-1209.
 23. The European transplantation registry: Liver transplantation in Europe mortality and retransplantation 01/1988- 12/2010. (<http://www.eltr.org/spip.php article188>).

4/8/2014