

A Model for the Study of Induced Skeletal Anomalies in Albino Rat Fetuses

Metwally A. Mansoor, Amal S. Sewelam, Maha M. Abdul Rahman and Mohamad A. Sabry

Department of Anatomy & Embryology, Faculty of Medicine, Zagazig University
abou_mo3az@yahoo.com

Abstract: Objective: This work aims at studying the phenytoin-induced skeletal anomalies in albino rat fetuses, using double stain for fetal rat skeleton with Alizarin red S and Alcian blue to be considered as a model for the study of induced skeletal anomalies. The study was done by a stereomicroscope. **Design:** In the present study stereomicroscope was used to study the double stained skeleton for rat albino rat fetuses in control and phenytoin-treated groups. **Material and Methods:** Fourteen adult albino female rats weighing about 170–250 g were used in this study. Three female rats were mated with one male overnight. The female rats were examined for sperms in the vaginal smear next morning, and sperm positive ones were considered as 0.5 day pregnant. The pregnant rats were divided into two equal groups (control and treated). In group-1 (control group), the rats were injected with an intraperitoneal (IP) dose of 0.3 ml physiological serum at 09:00 a.m. on the 8th, 9th, and 10th days of pregnancy. In group-2 (treated group), the rats were received an intraperitoneal (IP) dose of 25 mg/kg/day phenytoin diluted with physiological serum at 09:00 a.m. on the 8th, 9th, and 10th days of the pregnancy. On the 20th day of pregnancy, all rats were anaesthetized by ether inhalation and the fetuses were removed by transversal abdominal incision then dissected carefully. All the fetuses had been weighed using a scale and the crown-rump lengths were measured by a ruler. The fetuses were sacrificed with ether and examined for any gross external malformation. A number of 84 fetuses (44 from the group-1 and 40 from the group-2) were taken for the staining process, using Alizarin red S and Alcian blue stains. **Results:** Out of the 40 fetuses of phenytoin-treated group, no ossification signs appeared in some skull bones. Also, ossification was fine in other bones. Costal separation and costal angulation anomalies were observed in some fetuses of the treated group. No ossification was determined in the radius and the ulna of five fetuses. As for the metacarpal bones, no ossification was present in some of the metacarpal bones of four fetuses. Deficiency was also seen in the cartilage drafts of the metacarpal bones and phalanges in four fetuses. No ossification was determined in the coxal bones of four fetuses of this group. Tibia and fibula in 6 fetuses were completely cartilaginous in nature. No ossification was observed in the metatarsal bone drafts of one fetus. None of the phalanges of the foot of this fetus was ossified. Deficiency was also seen in the cartilage drafts of the phalanges. The mean value of the weights and lengths of the treated fetuses showed a highly significant difference as compared to control fetuses. **Conclusion:** Based on this study it can be concluded that phenytoin is a teratogenic substance, even with the lower doses, on the bone development of rats.

[Metwally A. Mansoor, Amal S. Swilam, Maha M. Abdul Rahman and Mohamad A. Sabry. **A Model for the Study of Induced Skeletal Anomalies in Albino Rat Fetuses.** *J Am Sci* 2014;10(2):181-190]. (ISSN: 1545-1003). <http://www.jofamericanscience.org>. 27

Key words: Teratogenicity, Phenytoin, Induced, Skeletal anomalies, Rat.

Introduction

Although, 40 agents are teratogenic for human fetuses, more agents are teratogenic in laboratory animals. Valporic acid, cyclophosphamide, methylnitrous urea and phenytoin are the best known teratogenic drugs in human and laboratory animals ⁽¹⁾. Development of the embryo is affected by teratogens mostly during the process of organogenesis, which is recognized as the time period from the occurrence of the neural plaque to closure of the plate. It begins usually on the 18th–21st days in human being, prolongs nearly 36 days. Likewise, it starts on the 6th day in rats, going on for 10 days ⁽²⁾. During this process, teratogenic agents can lead significant congenital anomalies. phenytoin has been documented to be a teratogenic agent in both mice and rats ⁽³⁾. Phenytoin administration has been documented to

increase vertical and slow wave discharges in rats and human beings. Morphologic and behavioral anomalies have been observed in both animals and human beings in the case of phenytoin usage in pregnancy. It also causes fetal hydantoin syndrome (FHS) in human being, which leads to prenatal and postnatal growth-development deterioration, congenital heart disease, and craniofacial defects comprising major malformations and mental retardation ⁽⁴⁾. Phenytoin has been reported to cause phalanx and digit hypoplasia and orofacial malformations in babies. Prenatal and postnatal growth deterioration, extremity defects (hypoplasia in distal phalanges and digits), major malformations, and mental retardation have also been documented ⁽⁵⁾. Double staining is labour-intensive and time-consuming, since it requires eviscerated and skinned foetus ⁽⁶⁾. However, it is the

only method for easy examination of the cartilage skeletal elements and is presently preferred ⁽⁷⁾.

2. Materials and Methods:

Chemical:

Phenytoin (diphenylhydantoin sodium salt-PHT).

Animals and Experimental design:

Fourteen adult albino female rats weighing about 170–250 g were obtained from animal house, Faculty of Medicine, Suez Canal University. Three female rats were mated with one male overnight. The female rats were examined for sperms in the vaginal smear next morning, and sperm positive ones were considered as 0.5 day pregnant. The pregnant rats were divided into two equal groups: (control and treated). The rats were kept under hygienic conditions, housed in metal cages and bedded with wood shavings, fed libitum and all had free access to water.

Group-1 (control group):

The rats were injected with an intraperitoneal (IP) dose of 0.3 ml serum physiologic at 09:00 a.m. on the 8th, 9th, and 10th days of the pregnancy.

Group-2 (phenytoin group):

The rats were received an intraperitoneal (IP) dose of 25 mg/kg/day phenytoin diluted with serum physiologic at 09:00 a.m. on the 8th, 9th, and 10th days of the pregnancy.

On the 20th day of pregnancy, all animals were anaesthetized by ether inhalation, uteruses with the fetuses and placentas were removed by transversal abdominal incision, and dissected carefully. All the fetuses were weighed using a scale and the crown-rump lengths were measured by a ruler. The fetuses were sacrificed with ether and examined for any gross external malformation. A number of 84 fetuses (44 from the group 1 and 40 from the group 2) were obtained for the staining process ⁽³⁾.

Microscopical examination:

They were firstly fixed in 95% ethyl alcohol for 7 days and subsequently put in pure acetone for degreasing for 3 days. Then, skin, eyes and internal organs were totally removed. The fetuses were later put in the staining solution for 7 days {alizarine red s (bone) and alcian blue(cartilage)}. They were then rinsed in tap water for 2 h. After that, they were undergone a transparency process to visualize the skeletal system for 14 days and observed and photographed by a stereomicroscope and a digital camera (optika) for determining possible malformations. Finally, they were transferred into pure glycerin for further usage ⁽³⁾.

Statistical analysis:

Statistical analyses were done using SPSS program. The results of lengths and weights of the fetuses were displayed as mean lengths and weights of the fetuses between two groups were measured by different unpaired t-test ($p < 0.05$).

3. Results:

1- Morphological examination

A- Control group

Maxilla, mandible, frontal and parietal bones were observed mostly complete ossification and stained red in all the fetuses. However, ossification was not completed in the occipital bone yet (Figs 1 and 2). The palatal closures of fetuses were normal as the palatine bones were stained red in all fetuses (Fig3). The cartilage of sternum showed 6 ossified parts (sternbrae) The distal one-third of the ribs through the costal cartilages were stained as blue. The cartilage-ossification ratio of the body of the ribs increased as descending caudally (Figs 4 and 5). The axial skeleton in rat fetuses is composed of a number of vertebral segments, subdivided, depending on their morphological characteristics, into cervical, thoracic, lumbar, sacral, and caudal vertebrae. Intervertebral discs, and caudal vertebrae were fully in cartilage nature and stained blue (Figs 1,6,9 and 10). Joints of the extremities were still cartilage in nature (Figs 7,8,9 and 10). Diaphysis ossification was seen in the long bones of the extremities with the presence of the epiphyseal cartilages on the bone edges. There were already red-stained areas in the distal phalanx and diaphyses of the three metacarpal bones, indicating the commencement of the ossification. Rest of the hand skeleton was still in the nature of a cartilage draft (Figs 7 and 8). The dorsal bone, the ilium forms the typical iliac crest and articulates with the sacral vertebrae, fused together forming the sacral bone. The most developed ossification area was in the diaphysis of the iliac bone (Fig 9). Femur, tibia, and fibula are partially ossified (diaphysis). The tarsal bones were stained blue. Ossification was determined to begin in the diaphyses of the four, but one, of the metatarsal bones.. There were red stained areas determined in the distal phalanx. It was also noted that all the three phalanges of the toe were completely cartilaginous in nature (Figs 9,10 and 11).

2-Treated group:

Of the 40 fetuses, there were no ossification signs yet in the nasal bones of 20 fetuses the frontal bones of 8 fetuses and the parietal bones of 26 fetuses. Ossification was fine in the the maxillae of 17 fetuses and the mandibles of 28 fetuses (Figs 12 and 13). There was no cleft palate in any fetus of the treated group as the palatine bones were stained red in all fetuses (Fig 14). Costal separation anomaly was observed in 8 fetuses of the treated group (Figs 15 and 16)). This anomaly in all of cases occurred between the 11th and the 12th ribs. Costal angulation anomaly was observed in 3 fetuses of the treated group (Figs 17 and 18).

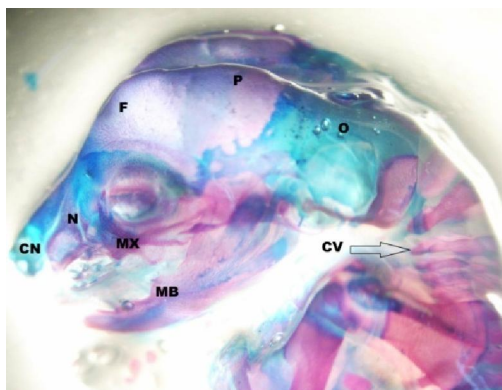


Fig. (1): A photograph for the skull and neck of double stained control rat fetus(lateral view) showing blue stained nasal cartilage(CN) and occipital bone (O) which are yet not ossified and red stained nasal bones(N), maxilla(MX), mandible(MB), frontal bone(F), parietal bone(p) and cervical vertebrae(CV) which are ossified by the age of 20 day gestation. [Alizarin red S(bone) & alcian blue(cartilage)]

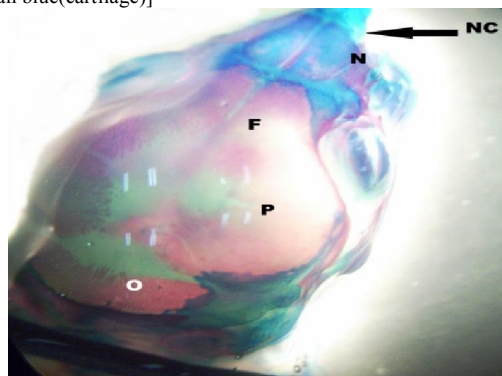


Fig. (2): A photograph for the skull of double stained control rat fetus (superior view) showing blue stained nasal cartilage(CN) is yet not ossified, red stained nasal bones(N), frontal bone(F), parietal bone(p), which are ossified by the age of 20 day gestation and also showing cartilaginous occipital bone with an ossification area near the parietal bones (O). [Alizarin red S(bone) & alcian blue(cartilage)]

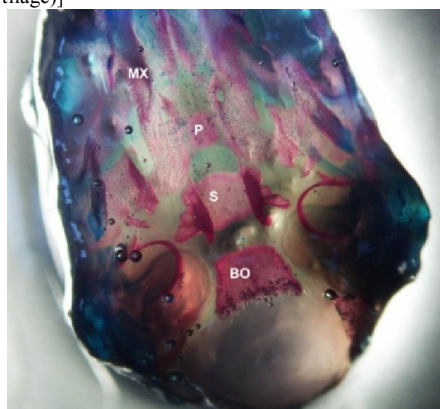


Fig. (3): A photograph for the skull base of double stained control rat fetus showing red stained maxilla(MX), palatine bones with no intervening cartilage (P), sphenoid bone (S) and basiocciput (BO) which are ossified by the age of 20 day gestation. [Alizarin red S(bone) & alcian blue(cartilage)]

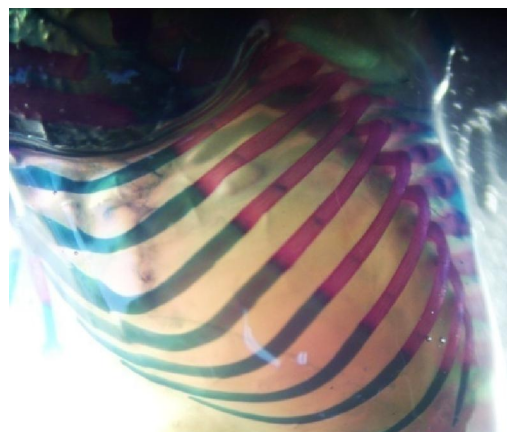


Fig. (4): A photograph for the ribs of double stained control rat fetus(lateral view) showing the normal anatomic position of ribs with blue stained costal cartilages and red stained ossified part and also showing that the cartilage-ossification ratio of the body of the ribs increased as descending caudally. [Alizarin red S(bone) & alcian blue(cartilage)]

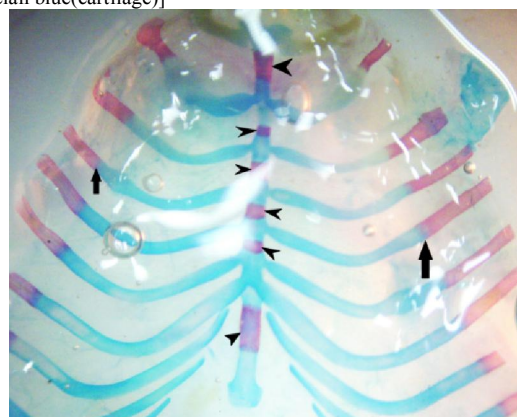


Fig. (5): A photograph for the ribs and sternum of double stained control rat fetus with costal cartilage (cut at both sides) stained blue, costochondral junction (black arrow) and 6 ossified part (sternum) (black arrow heads). and also showing that the cartilage ratio of the body of the ribs increased as descending caudally. [Alizarin red S(bone) & alcian blue(cartilage)]

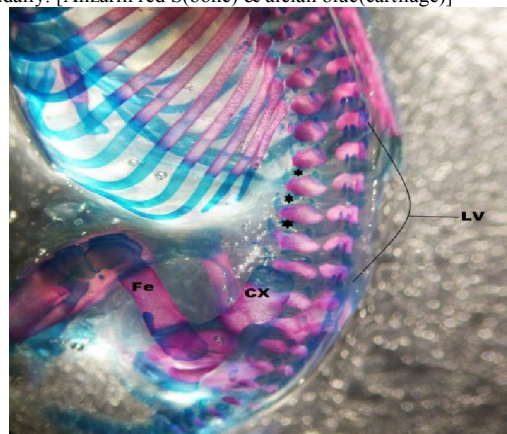


Fig. (6): An A photograph for vertebral column of double stained control rat fetus (lateral view) showing the 6 lumbar vertebrae and in between the blue stained inter vertebral cartilages ((black six-point star).), coxal bone (CX) and femur (Fe). [Alizarin red S(bone) & alcian blue(cartilage)]

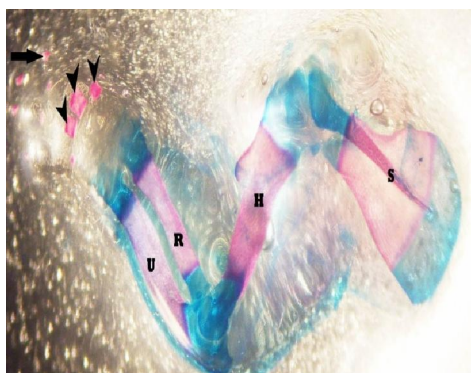


Fig. (7): A photograph for the left fore limb of double stained control rat fetus(dorsal view) scapula(S)with a red stained main body and blue stained ventral angle, glenoid cavity and dorsal margin, humerus(H), radius (R) and ulna (U) with red stained diaphysis and blue stained epiphysis and showing also ossified metacarpal bone(black arrow heads),and ossified distal phalanx (black arrow). [Alizarin red S(bone) & alcian blue(cartilage)]

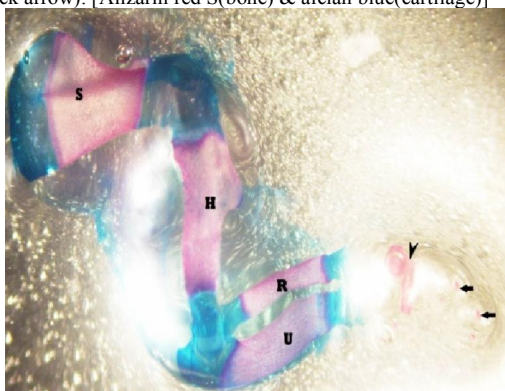


Fig. (8): A photograph for the left fore limb of double stained control rat fetus(ventral view) scapula(S) with a red stained main body and blue stained ventral angle, glenoid cavity and dorsal margin, humerus(H), radius (R) and ulna (U) with red stained diaphysis and blue stained epiphysis and showing also ossified metacarpal bone(black arrow heads),and ossified distal phalanx(black arrow). [Alizarin red S(bone) & alcian blue (cartilage)]

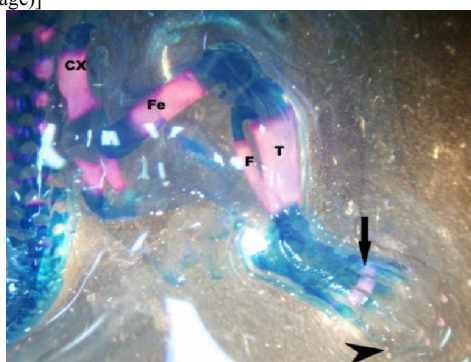


Fig. (9): A photograph for double stained control rat fetus showing the the hind limb formed of coxal bones which is formed of three bones the ilium, the pubis and the ischium fusing together to form the obturator foramen,femur (Fe),tibia (T), fibula (F) with red stain diaphysis and blue stained epiphysis and the bones of foot which is formed of tarsus stained blue, metatarsus stained red(black arrow) and phalanges which are cartilaginous except the distal phalanges are ossified (black arrow head). [Alizarin red S(bone) & alcian blue(cartilage)]

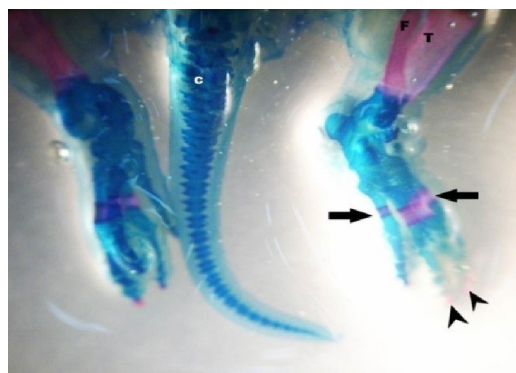


Fig. (10): A photograph for double stained control rat fetus showing the caudal vertebrae stained blue (C), tibia(T), fibula(F)and the bones of foot which is formed of tarsus stained blue, metatarsus stained red(black arrow) and phalanges which are cartilaginous except the distal phalanges are ossified (black arrow heads). [Alizarin red S(bone) & alcian blue(cartilage)]

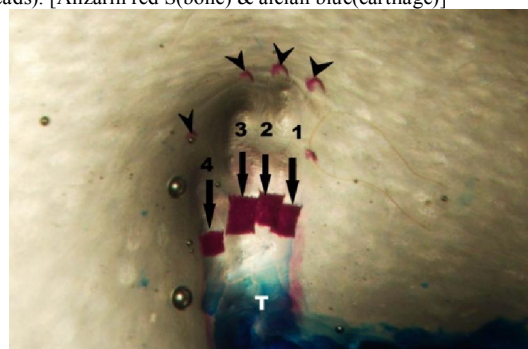


Fig. (11): A photograph for double stained control rat fetus showing the bones of foot which is formed of tarsus (T) stained blue, metatarsus stained red(black arrow) and phalanges which are cartilaginous (cartilage draft) except the distal phalanges are ossified (black arrow heads).[Alizarin red S(bone) & alcian blue(cartilage)]

Costal ossification was determined to be deteriorated in the fetuses of the treated group, particularly in those which possessed this anomaly (figs 17 and 18). Joint cartilages(the upper and lower surfaces of vertebral bodies) in the vertebral column were stained as blue. Distal one-third of the spinous processes, intervertebral discs and caudal vertebrae were cartilaginous in nature. Ossifications at various levels were documented in all the components of the vertebral column, but caudal. The caudal vertebrae were fully cartilaginous in nature yet (Figs 15,16,and 22) No ossification was determined in the radius and the ulna of five fetuses (Figs 19 and 20).Of the metacarpal bones, no ossification is present in some of the metacarpal bones of four fetuses(Fig 19). Deficiency was also seen in the cartilage drafts of the metacarpal bones and phalanges in four fetuses (Fig 19). No ossification was determined in the coxal bones of four fetuses of this group(Fig 21). Tibia and fibula in 6 fetuses were completely cartilaginous in nature (Fig 21). Tarsal cartilage drafts were prominent in all the fetuses in the treated group (Figs

21 and 22), but no ossification was observed in the metatarsal bone drafts of one fetus. None of the phalanges of the foot of this fetus was ossified. Deficiency is also seen in the cartilage drafts of the phalanges (Fig 22).

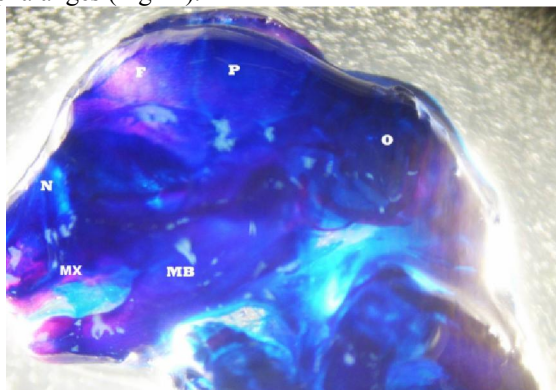


Fig. (12): A photograph for the skull of double stained treated rat fetus (lateral view) showing blue stained nasal bone (N), parietal bone (P) and occipital bone (O) which are yet not ossified and also showing maxilla (MX), mandible (MB) and frontal bone (F) with fine ossification. [Alizarin red S (bone) & alcian blue (cartilage)]

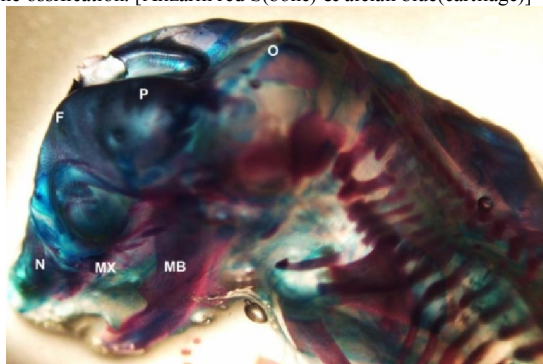


Fig. (13): A photograph for the skull of double stained treated rat fetus (lateral view) showing blue stained frontal bone (F) and parietal bone (P) which are yet not ossified and also showing red stained maxilla (MX) and mandible (MB), nasal bone (N) with fine ossification and cartilaginous occipital bone (O) with its ossified parts. [Alizarin red S (bone) & alcian blue (cartilage)]

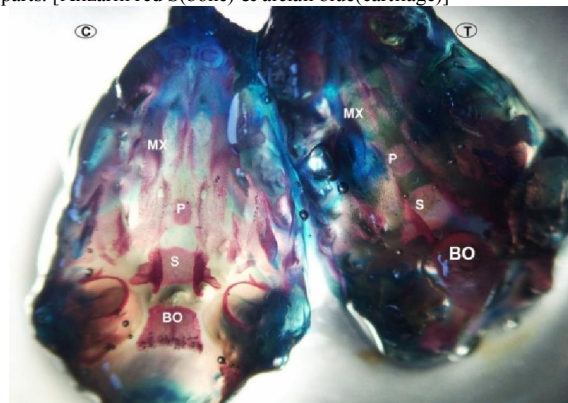


Fig. (14): A photograph for two skull bases of double stained control and treated rat fetus showing red stained maxilla (MX), palatine bones with no intervening cartilage (P), sphenoid bone (S) and basiocciput (BO) which are ossified by the age of 20 day gestation. [Alizarin red S (bone) & alcian blue (cartilage)]

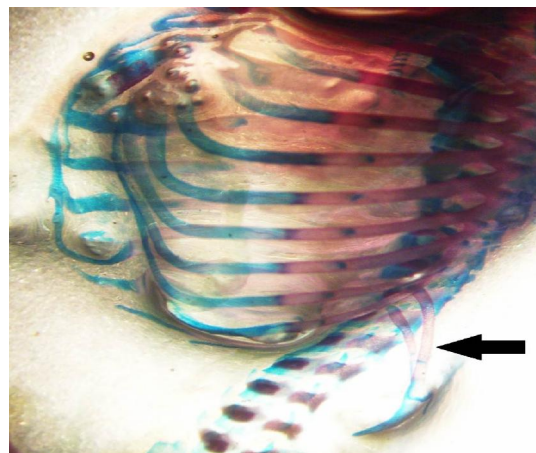


Fig. (15): A photograph for the thoracic cage of double stained treated rat fetus showing costal separation anomaly in which the last two ribs (12th and 13th) are separated from other ribs and laterally located (black arrow). [Alizarin red S (bone) & alcian blue (cartilage)]

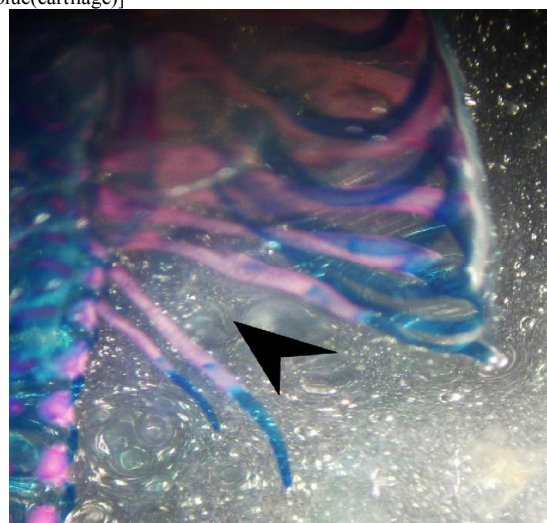


Fig. (16): A photograph for the lower ribs of double stained treated rat fetus showing costal separation anomaly between the 11th and the 12th ribs (black arrow head). [Alizarin red S (bone) & alcian blue (cartilage)]

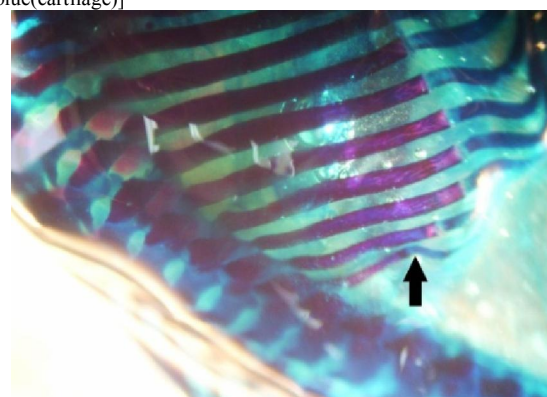


Fig. (17): A photograph for the thoracic cage of double stained treated rat fetus showing costal angulation of the last rib (black arrow). costal ossification is determined to be deteriorated. [Alizarin red S (bone) & alcian blue (cartilage)]

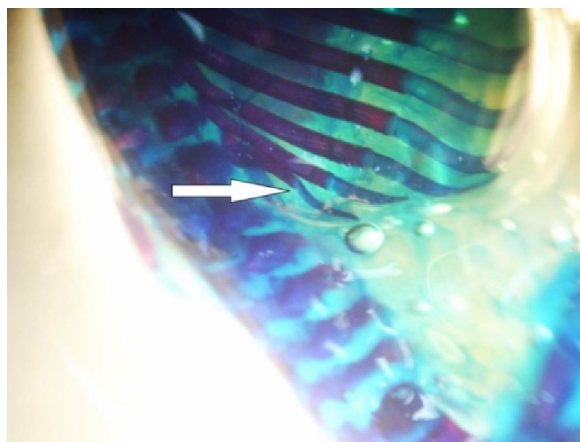


Fig. (18): A photograph for the thoracic cage of double stained treated rat fetus showing costal angulation of the last rib (white arrow). costal ossification is determined to be deteriorated. [Alizarin red S(bone) & alcian blue(cartilage)]

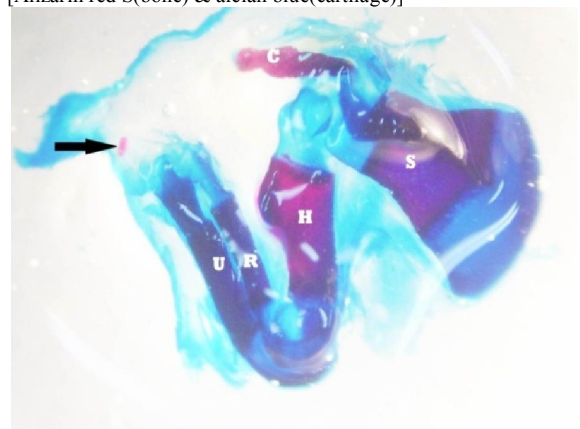


Fig. (19): A photograph for the left fore limb of double stained treated rat fetus(dorsal view) showing red stained scapula(S),clavicle (C) and humerus diaphysis (H) which are ossified while radius (R) and ulna(U) are not ossified (blue stained). there is only one ossified metacarpal bone and absent cartilage draft of phalanges with non ossified distal phalanges. [Alizarin red S(bone) & alcian blue(cartilage)]




Fig. (20): A photograph for the the left forelimb of double stained treated rat fetus(ventral view) showing ossified body of scapula (S) and ossified diaphysis of humerus (H) while there are unossified radius (R)and ulna(U). [Alizarin red S(bone) & alcian blue(cartilage)]




Fig. (21): A photograph for the left hind limb of one fetus in double stained treated group of rats showing coxal bone (CX) with non ossified ilium and pubis but ischium is ossified and showing also red stained femur diaphysis (Fe) and non ossified blue stained tibia (T)and fibula (F). [Alizarin red S(bone) & alcian blue(cartilage)]

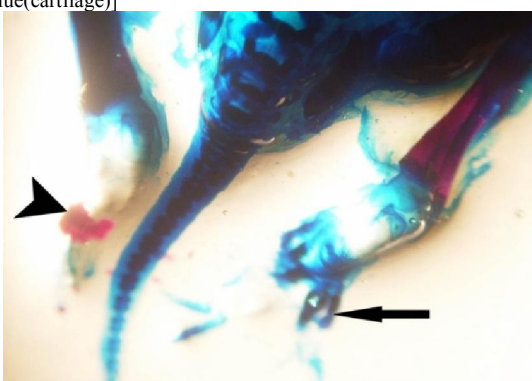


Fig. (22): A photograph for the hind limbs of one fetus in treated group of rats showing non ossified metatarsal bones and deficiency is also seen in the cartilage drafts of the phalanges with non ossified distal phalanges of one foot (black arrow) as compared with the other normal foot with its characteristic ossified metatarsal bones (black arrow head).[Alizarin red S(bone) & alcian blue(cartilage)]

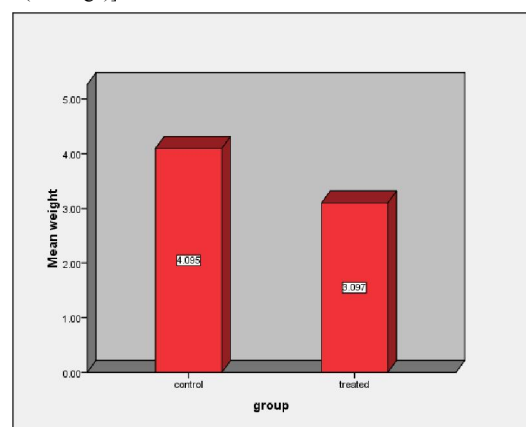


Fig 23 : showing The mean value of the weight of the treated fetuses was(3.097g) which showed a highly significant difference as compared with control fetuses (4.095g).

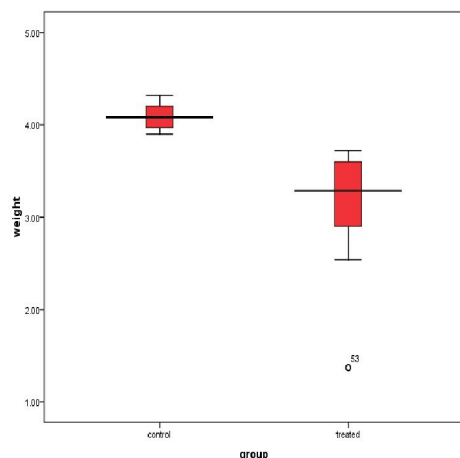


Fig 24: Box plot showing the weight of control and treated groups. Median of control =4.0000. Lower Quartile= 3.9700.Upper Quartile= 4.2000. minimum value= 3.90 maximum value=4.32 Median of treated =3.2850. Lower Quartile=2.9000. upper Quartile =3.6000. minimum value= 1.37. maximum value=3.6000.

2- Morphometric measurements:

1) Comparison of the weights of the fetuses in the two groups.

Table1: Comparison of the weights of the fetuses in the two groups as regards the mean and standard deviation

Group Statistics

Group	Number of fetuses	Mean(g)	Std. Deviation	Std. Error Mean	p.value
Weight Control	44	4.0955	.13311	.02007	.000
Treated	40	3.0970	.67669	.10699	

The mean value of the weight of the treated fetuses was **(3.097g)** which showed a highly significant difference as compared with control fetuses **(4.095g)**.

1) Comparison of the lengths of the fetuses in the two groups:-

Table 2: The mean value of the length of the treated fetuses was**(3.03cm)** which showed a highly significant difference as compared with control fetuses**(3.964cm)**.

Group Statistics

	group	N	Mean	Std. Deviation	Std. Error Mean	p.value
Length	Control	44	3.9636	.15111	.02278	.000
	Treated	40	3.0300	.48368	.07648	

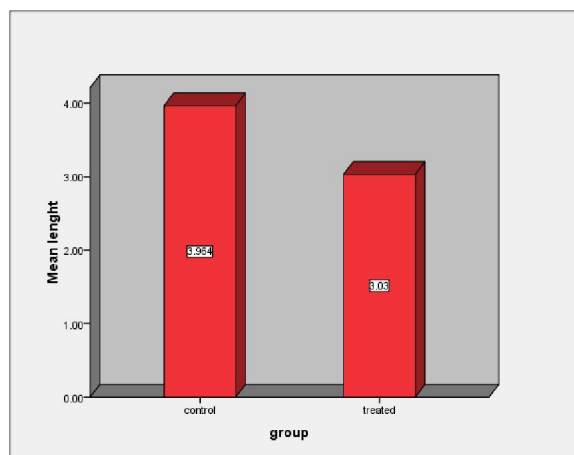


Fig 25: The mean value of the length of the treated fetuses was**(3.03cm)** which showed a highly significant difference as compared with control fetuses**(3.964cm)**.

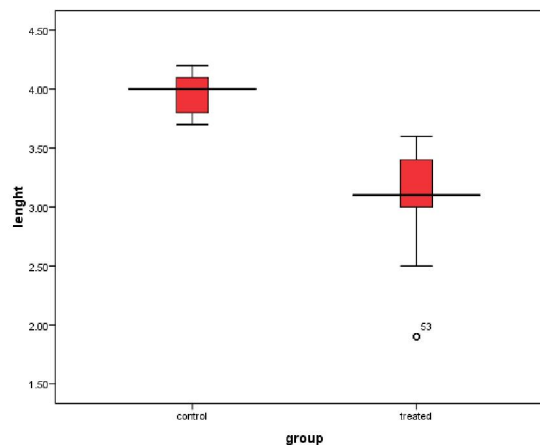


Fig 26: Box plot showing the length of control and treated groups. Median of control =4.0000. Lower Quartile= 3.8000.Upper Quartile= 4.1000. minimum value= 3.70 maximum value=4.20 Median of treated =3.1000. Lower Quartile=3.0000. upper Quartile =3.4000.. minimum value= 1.90. maximum value=3.60

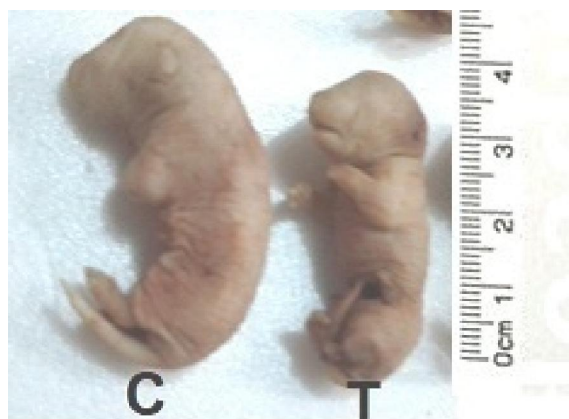

Fig 27 : showing the difference between the length of control group (C) and treated group fetuses (T)

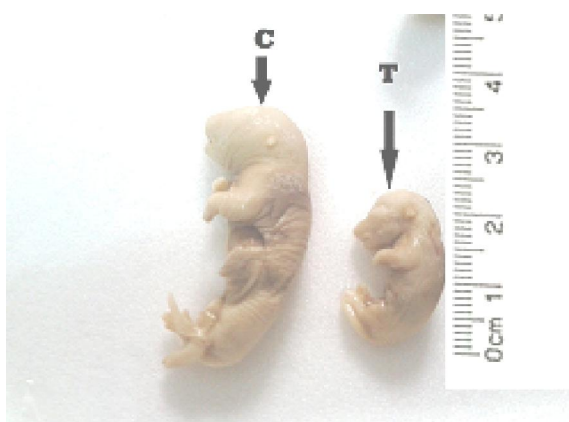


Fig 28: showing the difference between the length of one fetus of control group (C) and the smallest fetus of treated group

4. Discussion

PHT is generally recognized as a human teratogen, causing a range of malformations including: cleft lip/palate; heart malformations; and a phenytoin syndrome of prenatal growth deficiency, microcephaly, and mental deficiency. There have been a number of suggested mechanisms for the observed teratogenicity, including damage from reactive metabolites⁽⁸⁾, induced vitamin K deficiency⁽⁹⁾, and induced embryonic fetal hypoxia⁽¹⁰⁾. In relation to that, this study documented the teratogenic effect of the phenytoin on the skeletal development of the rat fetuses. It has been indicated that occurrence and intensity of this effect depend on the dose and administration way of the drug, and the gestation stage⁽³⁾. Oral and subcutaneous administrations of PHT have less effect, as compared to intraperitoneal usage⁽³⁾. Similarly, the present study has also documented that intraperitoneal usage of phenytoin is much more effective. In this study, an intraperitoneal single dose of 25 mg/kg phenytoin was applied to the rats on the 8th–10th days of the pregnancy. Such a

low dose administration, which is yet only one-fourth of the lowest dose, 100 mg/kg, seen in the literature. Because of the fetal rodent skeleton at term is only partially ossified single staining of bone cannot accurately describe normal and abnormal fetal skeletal structures. In spite of this limitations the single stain for bone is universally used in routine teratology tests, as it is simpler and cheaper than double staining methods⁽⁷⁾. Although these unossified structures generally become ossified as development continues, Alizarin Red S does not specifically stain these cartilaginous precursors of bone, and this technique is not useful for specific identification of cartilage⁽⁶⁾⁽⁷⁾. Failure to evaluate the cartilaginous portions of the skeleton may result in failure to identify important abnormalities in skeletal morphology. The double staining method for fetal skeletons was proposed several years ago by different investigators, with minor differences in methodology⁽³⁾. In the present study in the treated group there were no ossification signs yet in the nasal bones of 20 fetuses, the frontal bones of 8 fetuses and the parietal bones of 26 fetuses. Ossification was fine in the the maxillae of 17 fetuses, and the mandibles of 28 fetuses. These observations were in agreement with (Soysal *et al.*, 2011 and Abela *et al.*, 2005)⁽³⁾⁽¹¹⁾. In this study, no cleft lip neither cleft palate was seen in the fetuses of the phenytoin treated rats but Mahabady and varzi, 2009⁽¹²⁾ had observed cleft palate in fetuses of rat received phenytoin (75mg/kg) and they also concluded that vitamin E can decrease oxidative stress more than silymarine and has better prophylactic effect on incidence of phenytoin-induced cleft palate. Phenytoin had been reported to cause orofacial malformations in babies. Prenatal and postnatal growth deterioration, extremity defects, major malformations, and mental retardation have also been documented. (Fried *et al.*, 2004, Adams *et al.*, 1990 and Kock *et al.*, 1992)⁽⁵⁾⁽¹³⁾⁽¹⁴⁾. Tavli *et al.*, 2006, hanson 1986 and Yerby *et al.*, 1992 had observed fetal hydantoin syndrome (FHS) in human being, which is characterized as short nose, flattened nose bridge, hypoplasia in digits, curve-like or cleft lips, and cardiac septum defects.⁽¹⁵⁾⁽¹⁶⁾⁽¹⁷⁾ Sullivan & Mcelhatton, 1975 Eluma *et al.*, 1984 had reported exencephaly in mouse fetuses after giving 120 mg/kg and 125 mg/kg phenytoin, respectively, through gastric probe.⁽¹⁸⁾⁽¹⁹⁾ In the present study malformation in the ossification of the frontal bone in the rat fetuses was observed this observation was in agreement with (Soysal *et al.*, 2011)⁽³⁾, who said that the presence of malformation of ossification in the frontal bone suggests the presence of exencephally.

Costal separation anomaly was observed in some fetuses of the treated group (Soysal *et al.*, 2011)⁽³⁾. This observations was in agreement with this

study in which this anomaly was observed in 8 fetuses of the treated group.

This anomaly in all of cases occurred between the 11th and the 12th ribs. Costal angulation anomaly was observed in the 3 fetuses of the treated group. This anomaly was observed also by (Soysal *et al.*, 2011) ⁽³⁾. Costal ossification was determined to be deteriorated in the fetuses of the treated group, particularly in those which possessed this anomaly. In the present study in the treated group no ossification was determined in the radius and the ulna of five fetuses were completely cartilaginous in nature. These results were in agreement with (Soysal *et al.*, 2011) ⁽³⁾. Harbison and Becker 1969 had indicated that phenytoin leads to a worsening in the ossification process of the long bones in the mouse fetus⁽²⁰⁾.

In the present study no ossification is present in some of the metacarpal bones of four fetuses. Deficiency was also seen in the cartilage drafts of the metacarpal bones and phalanges in four fetuses of the treated group. These results were in agreement with (Soysal *et al.*, 2011) ⁽³⁾. In the present study no ossification was determined in the coxal bones of four fetuses of treated group and also no ossification was determined in the tibia and fibula in 6 fetuses which were completely cartilaginous in nature. These results were in agreement with (Soysal *et al.*, 2011) ⁽³⁾. Tarsal cartilage drafts were prominent in all the fetuses in the treated group but no ossification was observed in the metatarsal bone drafts of the foot of one fetus. None of the phalanges of this foot was ossified. Deficiency is also seen in the cartilage drafts of the phalanges. Fried *et al.*, 2004, Adams *et al.*, 1990 and Kock *et al.*, 1992 added that phenytoin had been reported to cause phalanx and digit hypoplasia in babies. Prenatal and postnatal growth deterioration, extremity defects (hypoplasia in distal phalanges and digits), major malformations, and mental retardation have also been documented. ^{(5) (13) (14)} Soysal *et al.*, 2011 said that there were significant differences on the weights and lengths of the fetuses between the two groups ($p = 0.0001$). They said also that the mean value of the weight of the treated fetuses was **(3.04g)** which showed a highly significant difference as compared with control fetuses **(3.51g)**, while the mean value of the length of the treated fetuses was **(2.75cm)** which showed a highly significant difference as compared with control fetuses **(3.21cm)**. ⁽³⁾ These observations were in agreement with the results of this study in which the mean value of the weight of the treated fetuses was **(3.097g)** which showed a highly significant difference as compared with control fetuses **(4.095g)**. The mean value of the length of the treated fetuses was **(3.03cm)** which showed a highly significant difference as compared with control fetuses **(3.964cm)**.

Consequently, we have documented that phenytoin is a teratogenic substance, even with the lower doses, on the bone development of rats. It should not be used in pregnancy unless otherwise required. Even if doing so, its teratogenic effect should be considered in relation with the dose, administration way, and timing.

References:

1. De Santis, M., Straface, G., Cavaliere, B., De Santis, L., Lu Echese, A., Merola, A.M., Caruso, A. 2004 Risk of drug-induced congenital defects. Eur. J. Obstet. Gynecol. Biol., 117: 10-19.
2. Vickers. M and Brackley, K. 2002 Drugs in pregnancy. Curr Obstet Gynaecol ;12:131-7.
3. Soysal, H., Unur, E., Duzler, A., Karaca, O., Ekinci, N. 2011 Effects of intraperitoneal administration of the phenytoin on the skeletal system of rat fetus. Seizure 20 :187-193.
4. Tomson. T and Battino. D. 2005 Teratogenicity of antiepileptic drugs: state of the art. Curr Opin Neurol; 18:135-40.
5. Fried, S., Kozar, E., Nulman, I., Einarson, T.R., Koren, G. 2004 Malformation rates in children of women with untreated epilepsy. Ameta-analysis. Drug Safety; 27:197-202.
6. Burdan, F., Rozylo-Kalinowska, I., Rozylo, T.K., Chahoud, I. 2002 A new, rapid radiological procedure for routine teratological use in bone ossification assessment: a supplement for staining methods. Teratology, 66: 315-325.
7. Menegola, E., Broccia, M. L., Di Renzo, F., Giavini, E. 2002 Comparative study of sodium valproate-induced skeletal malformations using single or double staining methods. Reprod Toxicol, 16(6):815-23.
8. Wells PG Wells, P.G., Zubovits, J.T., Wong, S.T., Molinari, L.M., Ali, S. 1989 Modulation of phenytoin teratogenicity and embryonic covalent binding by ASA, caffeic acid and a-phenyl-N-t-butyl nitron: Implications for bioactivation of prostaglandin synthetase. Toxicol Appl Pharmacol 97:192-202.
9. Howe, A.M., Lipson, A.H., Sheffield, L.J., Haan, E.A., Halliday, J.L., Jenson, F., David, D.J., Webster WS. 1995 Prenatal exposure to phenytoin, facial development, and a possible role for vitamin K. Am J Med Genet 58:238-244.
10. Danielsson, B.R., Azarbayjani, F., Skold A.C., Webster. W.S. 1997 Initiation of phenytoin teratogenesis: pharmacologically induced embryonic bradycardia and arrhythmia resulting in hypoxia and possible free radical

- damage at reoxygenation. *Teratology* 56:271–281.
11. Abela, D., Howe, A.M., Oakes, D.A., Webster, W.S. 2005 Maternal antioxidant supplementation does not reduce the incidence of phenytoin-induced cleft lip and related malformations in rats. *Birth Defects Res B*; 74:201–6.
 12. Mahabady, M. k., varzi, H. N. 2009 A comparison study of effects of vitamin E and silamarin on phenytoin-induced cleft palate in rats. *biological sciences* 9 (4): 381-384.
 13. Adams, J., Voorhees, C.V., Middaugh, L.D. 1990 Developmental neurotoxicity of anticonvulsants: human and animal evidence on phenytoin. *Neurobehavioral Toxicol Teratol*; 3(12):203–14.
 14. Koch, S., Losche, G., Jager-Roman, F., Jakob, S., Rating, D.D. 1992 Major and minor birth malformations and antiepileptic drugs. *Neurology*; 4(42):83–8.
 15. Tavli, V., Agin, H., Saritas, T.C., Evik, B. 2006 Fetal hydantoin syndrome. *Turk Klin Tip Bilim Derg*; 16:156–8.
 16. Hanson, J.W., 1986 Teratogen update: fetal hydantoin effects. *Teratolog* ;33:349–53.
 17. Yerby, M.S., Leavitt, A., Erickson, D.M., McCormick, K.B., Loewenson, R.B., Sells, C.J. 1992 Antiepileptics and the development of congenital anomalies. *Neurology* ;4(42):132–40.
 18. Sullivan, F.M., Mcelhatton, P.R., 1975 Teratogenic activity of the antiepileptic drugs phenobarbital, phenytoin and primidone in mice. *Toxicol Appl Pharmacol* ;34:271–82.
 19. Eluma, F.O., Sucheston, M.E., Hayes, T.G., Paulson R.B. 1984 Teratogenic effects of dosage levels and time of administration of carbamazepine, sodium valproate and diphenylhydantoin on craniofacial development in the CD-1 mouse fetus. *J Craniofac Gen Dev Biol* ;4:191–210.
 20. Harbison, R.D., Becker, B.A. 1969 Relation of dosage and time of administration of diphenylhydantoin to its teratogenic effect in mice. *Teratology*; 2:305–11.

2/19/2014