

## Effect of Lead Acetate on the Thyroid Gland of Adult Male Albino Rats and the Possible Protective Role of Zinc Supplementation: A Biochemical, Histological and Morphometric Study

Abeer E. El-Mehi<sup>1</sup> and Safaa A. Amin<sup>2</sup>

<sup>1</sup>Anatomy and Embryology Department, Faculty of Medicine, Menoufiya University.

<sup>2</sup>Forensic Medicine and Clinical Toxicology Department, Faculty of Medicine, Menoufiya University.

[abeermehi@gmail.com](mailto:abeermehi@gmail.com)

**Abstract: Background:** Lead is a major environmental pollutant. The interaction of micronutrients with toxic metals is of great interest. **Aim:** To evaluate the effect of lead toxicity on the structure and function of thyroid gland and the role of zinc supplementation. **Material and Methods:** Twenty eight adult male albino rats were divided into four groups: group I "control group", group II (zinc sulphate treated group), group III (lead acetate treated group) & group IV (lead acetate and zinc sulphate treated group). Lead acetate was administered in a dose of 30 mg /kg body weight (1/8 of lead acetate LD50) daily orally for 30 days. Zinc sulphate was administered in a dose of 1mg/kg body weight daily orally for 30 days. At the end of the experimental period, blood was collected to measure T3, T4 and TSH serum levels. The thyroid glands were processed for light and electron microscopic examinations. Morphometric analysis, for epithelial height, follicular area and colloidal area percent, was performed and statistically analyzed. **Results:** Lead treated rats showed significantly decreased T3, T4 and TSH serum levels. Histologically, lead treated rats showed enlarged thyroid follicles lined with flattened epithelium. Their colloid showed minimal peripheral scalloping and faint PAS reaction. Some follicles showed shedded epithelial lining. Ultrastructural findings included dilated rough endoplasmic reticulum, degenerated mitochondria, increased lysosomes and lack of microvilli of follicular cells. Apoptotic signs were detected in the form of darkly stained cytoplasm, shrunken nuclei with peripheral margination of chromatin and apoptotic bodies. Morphometrically, lead treated group showed significantly decreased epithelial height while the follicular area and colloidal area percent were significantly increased when compared to control group. Zinc coadministration resulted in improvement of the biochemical, histological and histomorphometric changes resulting from lead treatment. **Conclusions:** Lead acetate exerted harmful effects on the histological structure and the function of the thyroid gland. Zinc, when given to rats in a dose of 1mg/kg for 30 days, minimized these damaging effects.

[Abeer E. El-Mehi and Safaa A. Amin. **Effect of Lead Acetate on the Thyroid Gland of Adult Male Albino Rats and the Possible Protective Role of Zinc Supplementation: A Biochemical, Histological and Morphometric Study.** *J Am Sci* 2012;8(7):61-71]. (ISSN: 1545-1003). <http://www.jofamericanscience.org>. 10

**Key words:** lead acetate – thyroid gland – zinc sulphate

### 1. Introduction

Lead is one of the most abundant toxic metals and has been detected in all parts of the environment and in biological systems (Xia *et al.*, 2010). Worldwide a large number of people are exposed to lead every year, especially those who are poor and live in developing countries (Meyer *et al.*, 2008).

Humans have used lead since ancient times. However, the quantity of lead used in the 20th century far surpasses the total consumption in all previous eras. This is mainly because of the industrial applications (Landrigan *et al.*, 2000). The removal of lead from gasoline has resulted in decreased exposure in many countries. However, because of its malleability, resistance to corrosion, and low melting point, lead has been widely used in industry and levels remain high in many areas (Wang *et al.*, 2011).

Lead poisoning in humans, because of either occupational or environmental exposure, is a great public problem. Everyone is exposed to lead in air,

household dust, food, drinking water and various consumer products. Lead alters almost all biochemical processes and organ systems (Lee *et al.*, 2009).

Lead can be found in water pipes, insecticides, lining of equipment, in petroleum refining, in construction, bullets of gun, x-ray, cosmetics, paint pigments, book printing, internal and topical medicinal preparations and is a major industrial byproduct. Chronic lead poisoning is commonly seen in young children from sucking lead paint or lead toys and in workers engaged in printing, paint and petroleum industries (Bokara *et al.*, 2008).

Lead can cause marked hematological, neurological, gastrointestinal, renal, rheumatological and endocrine manifestations in man even at levels previously considered safe (Badii *et al.*, 2009). However, there are conflicting reports in the literature about the effect of occupational lead exposure on the thyroid functions in experimental animals and humans.

There are several trace elements that are needed for the normal function of the thyroid gland. Zinc has an important place among these elements because it may play a role in thyroid hormone metabolism and in converting T4 to T3 (Arthur and Beckett, 1999; Nishiyama *et al.*, 1994).

Moreover, poor nutritional status may increase lead absorption and potentiate toxic effects; thus, supplementation with essential minerals may compete for lead during intestinal uptake and transport, thereby decreasing absorption and toxicity. This interaction between zinc nutrition and lead exposure is a potentially significant health concern, as marginal or subclinical zinc intakes in human populations may be more common than previously thought (Wuehler *et al.*, 2005).

The main purpose of this study was to assess the influence of toxicity with lead on the structure and function of the thyroid gland and the possible protective role of zinc supplementation.

## 2. Materials and Methods:

### Chemicals:

Lead (Pb) acetate (purity: 99.6%) and Zinc (Zn) sulphate (purity: 98.9%) were purchased from Sigma Chemical Co., USA. Each of Pb acetate or Zn acetate doses was dissolved in 0.5 ml. water.

### Experimental design:

Twenty - eight adult male (12 weeks old) albino rats, weighing 180-200 g, were used in the present study. They were housed in stainless steel cages, maintained at room temperature and provided with water and standard feed *ad libitum*. After an adaptation period of one week, the rats were randomly divided into four equal groups (seven rats each): I, II, III and IV:

**Group I (control group):** represented the healthy control animals.

**Group II (zinc sulphate treated group):** included rats that received 1mg/kg body weight of Zn sulphate daily orally by means of a gastric tube (Batra *et al.*, 2001).

**Group III (lead acetate treated group):** administered 30 mg /kg body weight (1/8 of LD50) of lead acetate daily once a time for 30 days by means of a gastric tube (El-Nahal, 2010).

**Group IV (lead acetate and zinc sulphate treated group):** received Pb acetate as the previous group, and after 1 h they received 1 mg/kg body weight of Zn sulphate daily once a time for 30 days by means of a gastric tube.

### Evaluation methods:

#### Hormonal assay

At the end of the experimental period, blood samples were drawn from each animal, after subjecting them to mild ether anesthesia, by

puncturing the ocular vein with sterilized capillary glass tube, and centrifuged at 3000 rpm for ten minutes. Sera were separated and stored at -20°C until hormonal assay. Total T3 and T4 levels were measured by radioimmunoassay (RIA) using commercial kits (Coat-A-Coat), while Serum TSH was measured by RIA using a specific rat TSH kit (supplied by Diagnostic Products Corporation DPC, Los Angeles, USA). Radioactivity was determined by the gamma-counter (Chopra, 1971). The data were presented as mean  $\pm$  SD.

#### Histological study

At the end of experiment, all animals were killed by cervical dislocation. Thyroid gland, purposed for morphological study, was removed and separated from trachea. One lobe of each thyroid gland of the animals was dissected, cut into small cubes (about 1 mm<sup>3</sup>) and immediately fixed in 2% gluteraldehyde for electron microscopic study

#### Light microscopic study:

The lobes of the thyroids were fixed immediately in 10% neutral formalin for 24 hours. The specimens were then dehydrated in ascending grades of alcohol, cleared and embedded in paraffin. Sections of 5 microns thick were cut by microtome and stained with haematoxylin and eosin and periodic acid Schiff's stains (Bancroft and Gamble, 2007).

#### Morphometry:

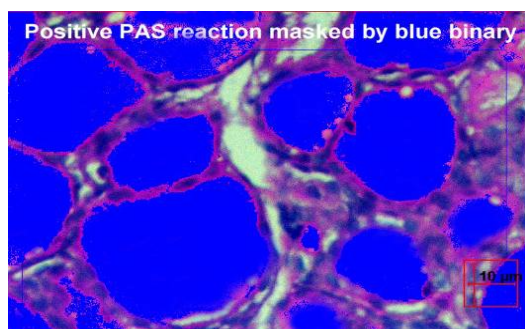
For estimation of functional state of thyroid gland, the following parameters were used:

\*The area percent of positive PAS reaction: was measured in 10 non overlapping fields for every specimen at magnification X 400 for all groups (Fig.1).

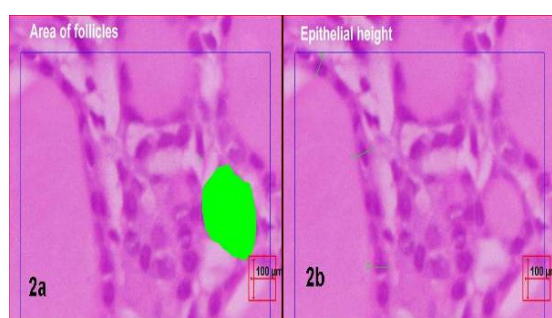
\*Area of follicles: was also measured in all groups by interactive drawing around the circumference of the follicles (Fig.2a).

\* Epithelial height of the cells lining the follicles: was measured for all groups at X 400 magnification (Fig.2b).

Image analysis was done using Leica Qwin 500C image analyzer computer system (England) present in Histology Department, Faculty of Medicine, Cairo University.



**Fig.1:** a copy of display seen on the monitor's screen of the image analyzer showing: areas of PAS +ve reaction of follicular colloid masked by a blue binary colour.



**Fig.2:** a copy of display seen on the monitor's screen of the image analyzer showing an example of measurement of the follicular area (2a) and the height of the epithelial lining (2b) of the thyroid follicles with the interactive measurement menu in sections stained by H&E.

### Electron microscopic study

Small fragments from the thyroid glands were rinsed in phosphate buffer (pH 7.4), fixed in 2% glutaraldehyde, postfixed in 1% osmium tetroxide and dehydrated. After embedding in epoxy resin, ultrathin sections (50-80 nm thick) were cut and stained with lead citrate and uranyl acetate (Hayat, 1986). The grids were examined and photographed with electron microscope at the Electron Microscope Unit, Faculty of Science, Menoufia University.

### Statistical analysis

The data obtained from hormonal assay and morphometry were presented as mean  $\pm$  SD. Data analysis was performed using GraphPad Prism version 4.03 for Windows (GraphPad software Inc., San Diego, California, USA). The obtained data were analyzed through the use of the analysis of variance (ANOVA) and the differences among groups were determined by Newman-Keuls multiple comparison test as post test. The results were considered statistically significant and nonsignificant when the P values were  $<0.05$  and more than 0.05 respectively (Altman, 1990).

## 3. Results

### Hormonal assay

Lead treated rats witnessed statistically significant decrease in serum T3, T4 and TSH levels as compared with normal controls. Zinc treatment alone did not result in any significant change in T3, T4, and TSH levels. Here also zinc supplementation to lead treated rats resulted in a significant rise ( $p < 0.05$ ) in serum T3, T4, and TSH levels, when compared with the lead treated rats but no significant change when compared with the normal controls (Table 1).

**Table (1): The mean values of T3 in  $\mu\text{g/dL}$ , T4 in  $\mu\text{g/dL}$  and TSH in  $\mu\text{U/dL} \pm \text{SD}$  in different groups.**

Groups	T3 ng/dL	T4 ng/dL	TSH microU/dL
Control	54.001 $\pm$ 2.29	66.021 $\pm$ 1.32	33.96 $\pm$ 1.86
Zinc treated	53.56 $\pm$ 2.1*††	66 $\pm$ 1.3*††	33.56 $\pm$ 1.6*††
Lead treated	50.02 $\pm$ 1.9 #†	63.57 $\pm$ 1.35 #†	30.15 $\pm$ 1.5 #††
Lead+zinc treated	53.90 $\pm$ 2.01*†	66.01 $\pm$ 1.31*†	32.5 $\pm$ 1.85*†

#: significant difference as compared to control.

\*: significant difference as compared to lead treated group. †:  $P < 0.05$  ††:  $P < 0.01$

### Light microscopic results:

In the control group, as well as in zinc treated rats, the thyroid gland was found to be divided into ill defined thyroid lobules by means of thin connective tissue septa. The lobules were composed of follicles which appeared generally oval or rounded lined with a single layer of cuboidal cells with rounded nuclei. Some follicles contained conspicuous peripheral

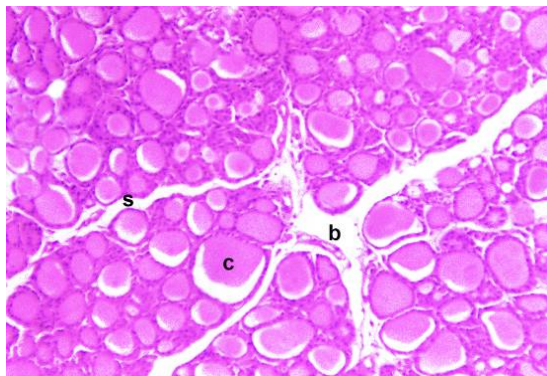
vacuoles (resorption lacunae) (Figs.1&2). The colloid showed different staining affinity with PAS & its amount varied from one follicular lumen to another (Fig.3).

In lead treated rats, the gland was mainly characterized by many enlarged follicles lined mostly with flat follicular cells that had flat nuclei. The follicles were distended with large amounts of

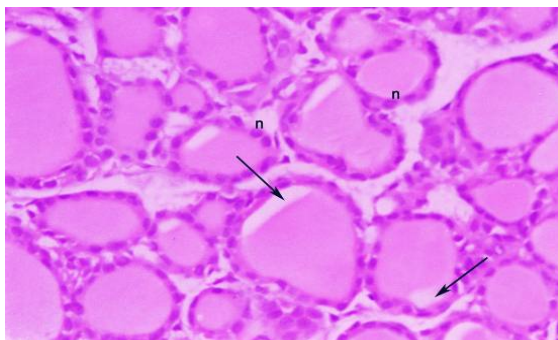


colloid, filling up the entire lumen in most of the follicles, with no or little peripheral scalloping (Fig.4). Some of the follicles had ruptured and coalesced to form large cysts with colloid seeping into the interfollicular spaces. Some follicles revealed shedded cells in their lumina (Fig.5). Shrunken pyknotic nuclei of many thyroid follicular cells were observed. Congested blood vessels were detected in the interstitial tissue (Fig.6). The colloid showed faint PAS reaction (Fig.7).

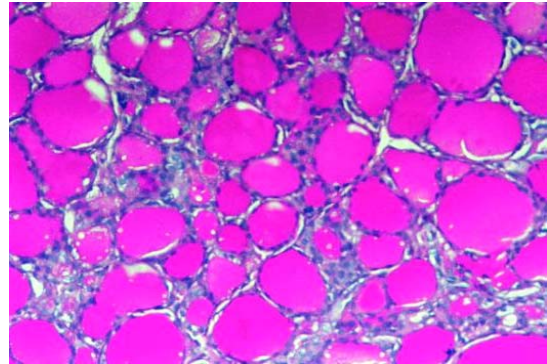
In the gland of rats administered additionally zinc ("lead + zinc" group), follicles of ordinal size and roundness lined with cuboidal cells were mostly seen. However, areas of enlarged follicles, distended with colloid and lined with flattened epithelium were seen (Fig.7). The colloid was highly colored in a manner nearly similar to that of control (Fig.8).



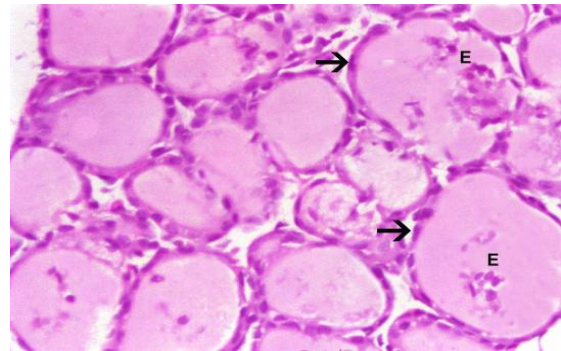
**Fig. (1) :** A photomicrograph of a transverse section of the thyroid gland of a control adult rat showing thyroid follicles containing acidophilic homogenous colloid (c) with scalloping of its edges in some follicles. The follicles were variable in size forming the gland lobules separated by thin connective tissue septa (s). Notice the blood vessel in the connective tissue (b). (Hx. & E. x 100)



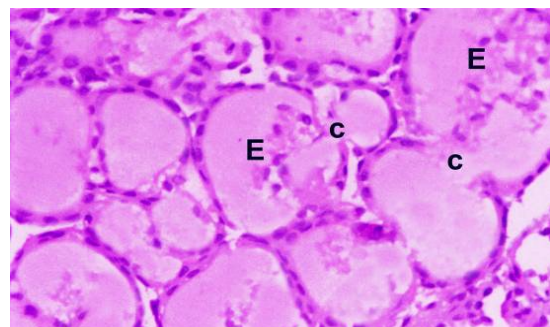
**Fig. (2) :** A photomicrograph of a transverse section of the thyroid gland of zinc treated adult rat showing thyroid follicles lined with cubical cells with rounded nuclei (n). Note: the scalloped colloid edges in some follicles (arrows). (Hx. & E. x 400)



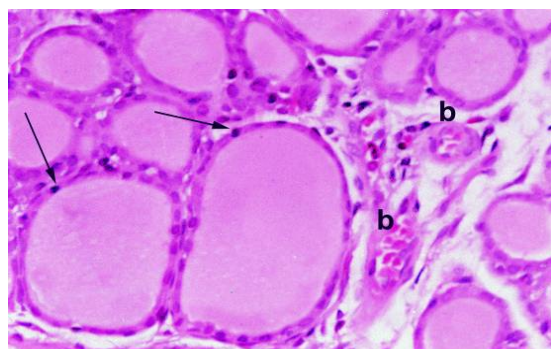
**Fig. (3):** A photomicrograph of a transverse section of the thyroid gland of a control adult rat showing a strong positive PAS reaction of the colloid of thyroid follicles. (PAS x200)



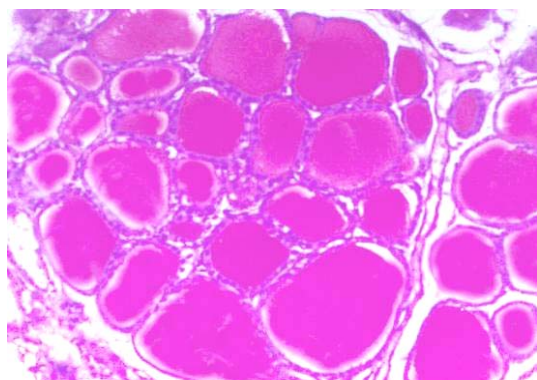
**Fig. (4) :** A photomicrograph of a transverse section of the thyroid gland of an adult rat treated with lead showing enlarged distended thyroid follicles turgid with colloid with minimal scalloping. The thyroid follicles were lined with flattened epithelial cells (arrows) some of which were exfoliated in the lumina of some follicles (E). (Hx. & E. x 400)



**Fig.(5) :** A photomicrograph of a transverse section of the thyroid gland of an adult rat treated with lead showing large follicles that ruptured and coalesced to form large cysts with colloid (c) seeping into the interfollicular space. Note: the exfoliated cells (E) in the lumina of some follicles. (Hx. & E. X 400)



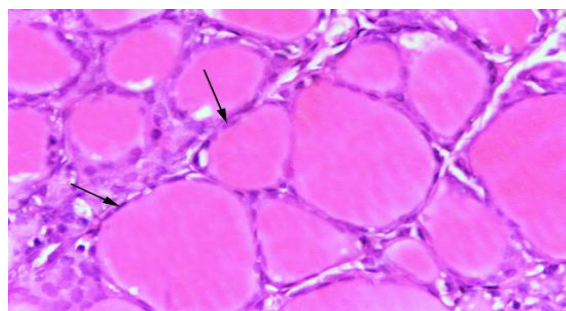**Fig.(6) :** A photomicrograph of a transverse section of the thyroid gland of an adult rat treated with lead showing darkly stained pyknotic nuclei of some thyrocytes (arrows). Notice: the congested blood vessels (b) in connective tissue septa. (Hx. & E.x400)



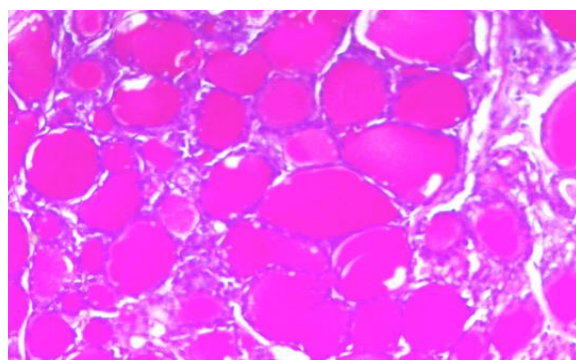
**Fig.(7) :** A photomicrograph of a transverse section of the thyroid gland of an adult rat treated with lead showing less positive PAS reaction of the follicular colloid. (PAS x200)

#### Morphometric analysis of light microscopic results:

In lead treated group, epithelial height was significantly decreased while the follicular area and colloidal area percent were significantly increased when compared to control group. Combined



**Fig.(8):** A photomicrograph of a transverse section of the thyroid gland of an adult rat treated with lead and zinc showing apparently normal ordinary sized follicles with cubical epithelial lining and peripheral scalloping of their colloid. Some follicles, however, appeared large, lined with flattened epithelium and distended with colloid (arrows). (Hx.& E. x400)



**Fig. (9) :** A photomicrograph of a transverse section of the thyroid gland of an adult rat treated with lead and zinc showing strong PAS +ve reaction nearly similar to that of control. (PAS X 200)

treatment with lead plus zinc resulted in improvement of all of the previous histomorphologic parameters that showed a non-significant difference when compared to the control group and a significant difference when compared to lead treated group (Table 2 ).

**Table 2: Analysis of histomorphometric data of the different animal groups.**

PARAMETERS	CONTROL	ZINCTREATED	LEADTREATED	LEAD+ZINCTREATED
Epithelial height	7.84±1.32	7.66±0.94*†††	4.21±0.82 #†††	7.56±0.7*†††
Follicular area	3240.5±357.3	3157.3±376.07*†††	4353.8±544.7 #†††	3287.9±286.805*†††
Colloidal area %	30.75±9.7	30.73±9.32*††	40.33±10.44 #††	31.37±11.8*††

#: significant difference as compared to control.

\*: significant difference as compared to lead treated group. ††: P<0.01 †††: P<0.001

#### Electron microscopic results:

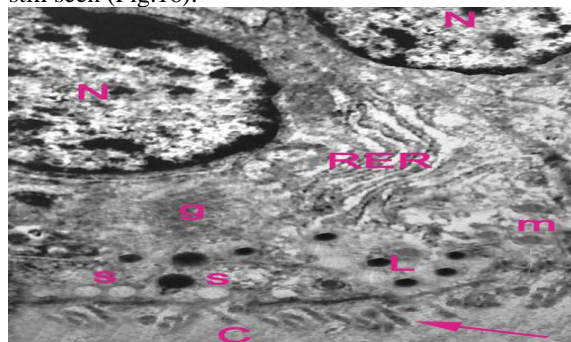
Follicular cells of control rats appeared with rounded euchromatic nuclei and numerous short apical microvilli. Their cytoplasm contained rough

endoplasmic reticulum (RER), abundant mitochondria, prominent Golgi apparatuses, lysosomes and intracytoplasmic secretory vesicles containing colloid (Fig.10).

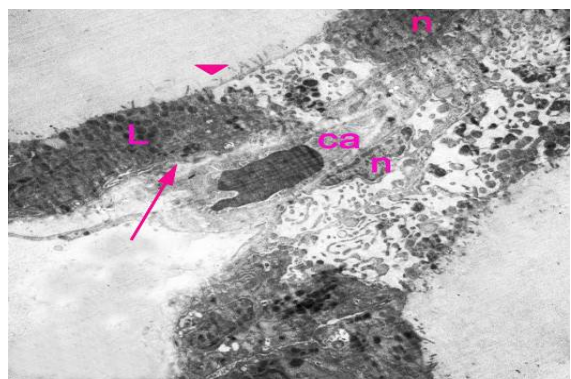


Lead treated rats showed loss of the normal follicular architecture. The follicles had stretched walls and large distended lumens. The cytoplasm of some follicular cells appeared darkly stained and showed scanty degenerated organelles and many lysosomes (Fig.11). The nuclei were flattened, shrunken and irregular with peripheral condensation of chromatin (Fig.12). There was marked reduction in the surface microvilli (Figs.11&12). The mitochondria were degenerated with loss of cristae and there was dilatation of RER (Figs. 12&13). Debris of exfoliated follicular cells and apoptotic bodies were noticed in the lumen of some follicles (Fig.14). Collagen bundles were seen in the interstitium (Fig.15).

Rats treated with both lead and Zinc showed many follicular cells with euchromatic nearly normal shaped nuclei. However, some cells with damaged mitochondrial cristae and detached microvilli were still seen (Fig.16).

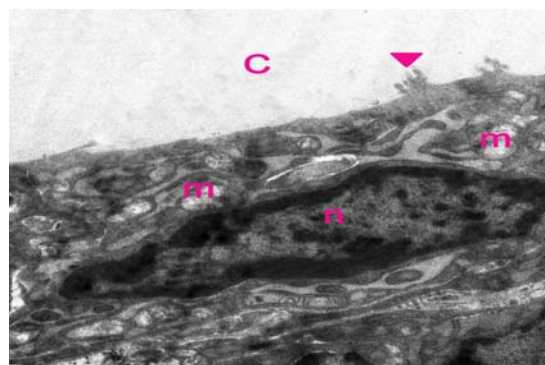


**Fig.(10):** An electron micrograph of a section of the thyroid gland of a control adult rat showing a follicular cell and a part of another adjacent cell showing apical microvilli (arrow) facing colloid (C), spherical euchromatic nuclei (N), mitochondria (m), rough endoplasmic reticulum (RER), lysosomes (L) and secretory vesicles (s). X 10000

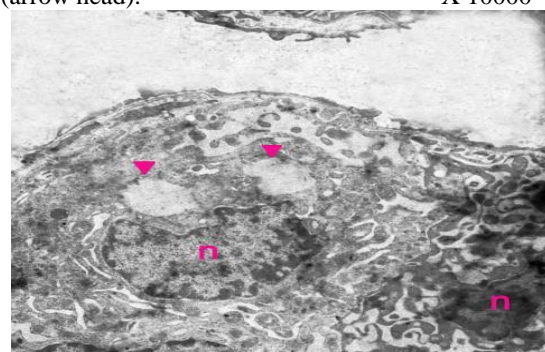


**Fig. (11):** An electron micrograph of a section of the thyroid gland of a lead treated rat showing two markedly stretched thyroid follicles with a blood capillary (ca) in between. The follicular cells


exhibited scanty cytoplasmic organelles. Some follicular cells appeared darkly stained (arrow). There was nuclear shrinkage (n), abundant lysosomes (L) and reduction of microvilli (arrow head). X5000




**Fig. (12):** An electron micrograph of a thyroid follicular cell of a lead treated rat showing a flattened nucleus (n) with peripheral condensation of chromatin. Many mitochondria were degenerated with loss of cristae (m). The cell surface facing the colloid (c) showed marked reduction of microvilli (arrow head). X 10000



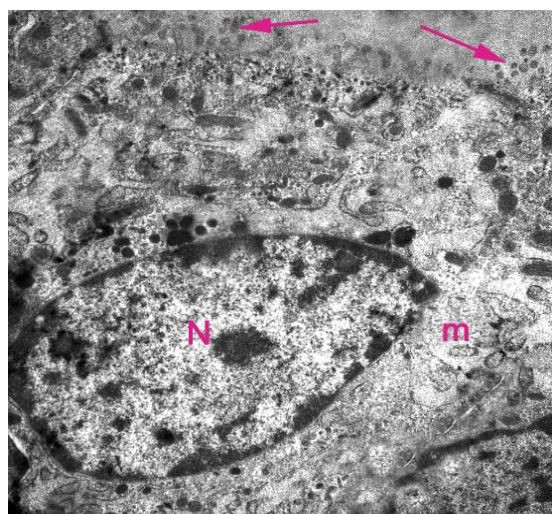
**Fig.(13):** An electron micrograph of thyroid gland of a lead treated rat showing shrunken deformed nuclei (n), and dilated RER (arrow head). X 8000



**Fig. (14):** An electron micrograph of thyroid gland of a lead treated rat showing an area of marked loss of thyroid architecture. Debris of exfoliated cells (EX), apoptotic bodies (arrows) and shrunken deformed nuclei (n) were seen. X5000



**Fig. (15):** An electron micrograph of thyroid gland of a lead treated rat showing longitudinally and transversely cut collagen fibers (cf) in the interstitium between the thyroid follicles. X 5000



**Fig. (16):** an electron micrograph of the thyroid gland of a rat treated with both lead and zinc, showing a part of a thyroid follicle showing more or less normal nucleus (N) and cytoplasmic organelles. Some mitochondria with degenerated cristae (arrows) were seen. The surface microvilli were nearly normal except for some detached microvilli (arrows).

X10000

#### 4. Discussion

The results of the present study revealed that lead acetate exerted significant harmful effects on the structure and function of thyroid gland and that zinc coadministration markedly minimized these effects. The pathogenesis of lead toxicity is multifactorial, as lead directly interrupts enzyme

activation, competitively inhibits trace mineral absorption, binds to sulfhydryl proteins (interrupting structural protein synthesis), alters calcium homeostasis, and decreases the level of available sulfhydryl antioxidant reserves in the body, as reported by **Ercal et al., 2001**. **Soltaninejad et al., 2003** suggested that lead-induced toxic effects may occur through free radical production and oxidative stress. This point of view was supported by **Abdollahi, 2001** who found that lead exposure causes the generation of reactive oxygen species and alteration of antioxidant defense systems in animals and occupationally exposed workers.

**Silbergeld et al., 2000** and **Patrick, 2006** added that Lead can lead to inhibition of the activities of antioxidant enzymes, including glutathione peroxidase, catalase and superoxide dismutase, and, furthermore, generation of reactive oxygen species (ROS), stimulation of lipid peroxidation and depletion of antioxidant reserves which was postulated to be major contributors to lead-exposure related diseases. **Abdel-Wahhab and Aly, 2005** explained that lipid peroxidation inactivates cell constituents by oxidation or causes oxidative stress by undergoing radical chain reaction, ultimately leading to loss of membrane integrity.

The findings of this study indicated hypoactivity of the thyroid gland in lead treated rats as previously found by **Rao-Rupanagudi et al., 1992** and was further supported by **Erfurth et al., 2001**.

Hypothyroidism was proved biochemically by the significant decrease in the serum levels of T3 and T4, histologically by the large follicles overdistended with colloid with minimal scalloping and lined with flattened cells, the degenerated follicular cells and loss of microvilli, histochemically by the faint PAS reaction of the follicular colloid and morphometrically by decreased epithelial height and increased follicular area and colloidal area percent.

In our study, mean serum concentrations of T3, T4 and TSH decreased significantly in lead-treated rats as compared to controls. These results were in harmony with those of **Wade et al. (2002)** and **Badiei et al., 2009**. Moreover, **Gustafson et al., 1989** observed a dose related depression of thyroid functions in humans during occupational exposure to inorganic lead.

Declined concentration of serum T3 in Lead treated rats might be due to decreased transformation rate from T4 to T3 according to inhibition of type-I iodothyronine 5'-monodeiodinase(5'-D), the enzyme responsible for the peripheral deiodination of T4 to T3, activity as suggested by **Chaurasia et al., 1996**. **Yoshizuka et al., 1991** explained that Lead can inhibit 5'-D activity through binding to sulfhydryl



groups of this enzyme. **Badiei et al., 2009** reported that the decrease of serum T3 concentration in lead treated sheep might be related to hepatic dysfunction that occurred secondary to lead treatment.

A tendency towards an increase in the serum TSH concentration observed at exposure to lead is a likely response to decreased serum T4 and T3 level. TSH didn't respond to low thyroid hormones and conversely significantly decreased. Similar results were recorded by **Pavia Junior et al., 1997** and **yousif and Ahmed ,2010** who suggested lead interference in synthesis and /or secretion of TSH by the pituitary gland or TRH by the hypothalamus . Moreover, **Singh et al., 2000** found that lead poisoning lowers TSH levels in humans.

Since the thyroid gland is the only organ involved in T4 synthesis (**Kelly, 2000**), the decrease of this hormone level in the serum of the Lead-exposed rats, may suggest that lead influences the production and/or secretion of T4 by follicular cells that might be related to structural damage of thyroid follicular cells due to accumulation of lead in the thyroid gland as stated by **Badiei et al., 2009**.

The results of this study supported this view as it showed lead induced apoptotic changes of thyroid follicular cells as evidenced by the darkly stained cytoplasm, shrunken pyknotic nuclei with peripheral condensation of chromatin, degenerated mitochondria and detection of apoptotic bodies.

Lead induced apoptosis may be due to oxidative stress that caused degeneration of mitochondria, observed in this study, and is a sign of cell injury. Disruption of the inner mitochondrial membrane might increase the permeability and allow the solute to enter inside the matrix and lead to its swelling, followed by rupture of the outer mitochondrial membrane and release of the preapoptotic proteins (**Loeffler and Kroemer, 2000**). **Esmekaya et al., 2010** reported that reactive oxygen species (ROS) generation and overload of cellular calcium [Ca<sup>2+</sup>] ions may be involved in the alteration of thyroid morphology and the induction of caspase pathways in thyroid cells

Morphometric analysis revealed, in lead treated group, a significant decrease in follicular epithelium height which suggested unstimulated and resting follicular cells as follicle epithelium height depends on the functional state of the thyroid gland (**Ingbar, 1985**). The area of the colloid in the lumen of the follicles increased significantly. This indicates that thyroid glands of the lead treated rats were in an inactive state. Inhibition of phagocytosis/pinocytosis of the colloid that contains thyroglobulin causes it to accumulate in the follicular lumen, thereby increasing the colloidal diameter and diminishing the height of the follicular epithelium ( **Wollman et al., 1990** ;

**Castillo et al., 2001** ). Moreover, the increase in the follicular area in the lead treated group may be associated with the increase in colloidal area because it is known that the size of a follicle depends on the amount of colloid (**Hartoft et al., 2005**). These morphometrical results of this study suggest that thyroid hormone secretion is inhibited by lead.

At the light microscopic level; examination of thyroid glands of rats of the lead treated group revealed marked distortion of follicular structure. Many follicles appeared distended and lined by flat follicular cells due to increased colloid content that had minimal peripheral vacuolations denoting hypoactivity of these follicles as previously supported by **Abdel-Dayem and Elgendy, 2009** and **El-Rouby, 2010**. A group of follicles had shedded epithelial cells. These changes could be attributed to cellular distension with accumulated colloid which resulted in cellular disruption.

Ultrastructurally, there was dilatation of RER. This dilatation might reflect a need by the injured cells for oxidative enzymes which are required for detoxification (**Jarrar, 2001**).

The dilated RER might be the cause of nuclear indentation and irregularity as the dilated RER compressed the nucleus causing its indentation and irregularity (**El-Rouby,2010**). The apparent increase in lysosomal number may be due to enhanced phagocytosis and may reflect an increase in the synthesis of hydrolytic and detoxifying enzymes secondary to the degenerative and apoptotic changes seen in many cells (**Miqueles and Simon, 1981** ; **Jarrar, 2001**)

The flattened cells contained degenerated organelles and showed a lack of microvilli. **Nakazawa et al., 2008** reported that these changes might disturb the transport of colloid substance between the follicular lumen and the follicular cells and that they probably represented histological and ultrastructural equivalents of poor thyroid hormone synthesis and were in accordance with the hypofunctional status of the thyroid.

Histochemically, thyroid sections of Lead treated rats showed a decreased PAS reaction of colloid which may be due to impaired uptake of iodine in thyroid gland contributing to formation of the so-called relative iodine deficiency that leads to expansion of connective tissue and reduction of the thyroglobulin concentration in the follicles of the gland , as previously explained by **Khotimchenko et al.,2004**.

In this study, we have registered significant signs of improved morphological structure of thyroid gland, and enhanced level of thyroid hormones in animals treated with zinc together with Lead. This indicates that zinc diminishes the adverse effects of



lead on thyroid gland and thyroid hormone metabolism. The mechanism is likely to relate with the fact that zinc and Lead compete for similar binding sites on the metallothionein-like transport protein in the gastrointestinal tract and that this competition might diminish the absorption of lead resulting in reduction of lead toxicity, as explained by **Hsu and Guo, 2002**.

Our results were in harmony with those of **Malekirad et al., 2010** who concluded that exposure to lead and Zn in mine workers increases plasma concentrations of lead and Zn and elevates total antioxidant capacity of the body to overcome oxidative stress. This could be explained by **Formigari et al., 2007** and **Catania et al., 2009** who stated that, zinc is a known fundamental component of the endogenous enzymatic antioxidant system with antioxidant properties and that it plays an essential role in cell membrane integrity and functions in many aspects of cellular metabolism.

Moreover, The fact that in cases of zinc deficiency the activity of 5-deiodinase in liver falls by 67% (**Kralik et al., 1996**), may be accepted as evidence that zinc deficiency results in a reduction in conversion of T4 to T3, and in turn T3 requires zinc to fulfill its biological activity (**Freake et al., 2001**). **Morley et al., 1980** showed that zinc deficiency resulted in a fall in T3 and T4 hormones as well as hypothalamic TRH content. In another study, zinc application increased thymic functions and this, in turn, improved thyroid functions influencing the pituitary–thyroid axis (**Napolitano et al., 1990**).

Contrary to the present results, **Piao et al., 2007** found a greater decrease in serum T4 in rats that received both lead and Zn compared to those which received lead alone, they explained that this result was a consequence of the joint toxic action of lead and Zn. The discrepancy may be explained by differences in the manner and dose of zinc administration. The inhibitory effect of zinc on thyroid hormone secretion was found to be dose-dependent and resulted from high-dose applications (**Baltaci et al., 2004**). This was further supported by **Formigari et al., 2007** who reported that extra-normal levels of Zn in the body can be harmful to the cells.

## 5. Conclusion

From the results of this study, it is concluded that lead has a deleterious effect on the histological structure of the thyroid gland and on the biochemical parameters that reflect the function of the gland. Zinc, when given to rats in a dose of 1mg/kg for 30 days, minimized these damaging effects. We recommend receiving exogenous zinc supplements and eating foods that contain sufficient amounts of zinc as a way

to counteract the deleterious effects of the environmental and occupational exposure to lead. In addition, we recommend further studies on the role of zinc in lead toxicity in different doses and on various organs.

## Corresponding author

**Abeer E. El-Mehi**

Anatomy and Embryology Department, Faculty of Medicine, Menoufiya University.

[abeermehi@gmail.com](mailto:abeermehi@gmail.com)

## References

- Abdel-Dayem, M.M., and M.S. Elgendy, 2009. Effects of chronic estradiol treatment on the thyroid gland structure and function of ovariectomized rats. *BMC Res Notes*. 2:173.
- Abdel-Wahhab, M.A., and S.E. Aly, 2005. Antioxidant property of *Nigella sativa* (black cumin) and *Syzygium aromaticum* (clove) in rats during aflatoxicosis. *Journal of Applied Toxicology*. 25( 3) :218–223,.
- Abdollahi, M., N. Rahmat-Jirdeh, and K. Soltaninejad. 2001. Protection by selenium of lead-acetate-induced alterations on rat submandibular gland function. *Hum Exp Toxicol*. 20:28-33.
- Altman , D.G. 1990. Practical statistics for medical research. Chapman and Hall.
- Arthur, J.R., and G.J. Beckett., 1999. Thyroid function. *Br Med Bull.*, 55:658-668.
- Badie, K., P. Nikghadam, K. Mostaghni, and M. Zarifi. 2009. Effect of lead on thyroid function in sheep. *Iranian Journal of Veterinary Research*. 10 (3) :223-227.
- Baltaci, A.K., R. Mogulkoc, A. Kul, C.S. Bediz, and A. Ugur., 2004. Opposite effects of zinc and melatonin on thyroid hormones in rats. *Toxicology*, 195:69-75.
- Bancroft , J.D., and M. Gamble., 2007. Theory and practice of histological techniques. Churchill Livingstone, New york, London, Philadelphia.
- Batra, N., B. Nehru, and M.P. Bansal., 2001. Influence of lead and zinc on rat male reproduction at 'biochemical and histopathological levels'. *J Appl Toxicol.*, 21:507-512.
- Bokara, K.K., E. Brown, R. McCormick, P.R. Yallapragada, S. Rajanna, and R. Bettaiya, 2008. Lead-induced increase in antioxidant enzymes and lipid peroxidation products in developing rat brain. *Biometals*, 21:9-16.
- Castillo, V.A., J.C. Lalia, M. Junco, G. Sartorio, A. Marquez, M.S. Rodriguez, and M.A. Pisarev. 2001. Changes in thyroid function in puppies fed a high iodine commercial diet. *Vet J*. 161:80-84.

- Catania, A.S., C.R. Barros, and S.R. Ferreira. 2009. [Vitamins and minerals with antioxidant properties and cardiometabolic risk: controversies and perspectives]. *Arq Bras Endocrinol Metabol.* 53:550-559.
- Chaurasia, S.S., P. Gupta, A. Kar, and P.K. Maiti. 1996. Free radical mediated membrane perturbation and inhibition of type-I iodothyronine 5'-monodeiodinase activity by lead and cadmium in rat liver homogenate. *Biochem Mol Biol Int.* 39:765-770.
- Chopra, I.J., D.H. Solomon, and R.S. Ho. 1971. A radioimmunoassay of thyroxine. *J Clin Endocrinol Metab.* 33:865-868.
- El-Nahal, D., M. 2010. Effect of using pectin on lead toxicity. *The Journal of American Science.* 6(12):541-554.
- El-Rouby, N.M. 2010. A Histological Study on the Effect of Diclofenac Sodium (Declophen) Administration on Thyroid Follicular Cells of Albino Rats  
*Egypt. J. Histol.* 33, No. 2, June:213 - 223.
- Ercal, N., H. Gurer-Orhan, and N. Aykin-Burns. 2001. Toxic metals and oxidative stress part I: mechanisms involved in metal-induced oxidative damage. *Curr Top Med Chem.* 1:529-539.
- Erfurth, E.M., L. Gerhardsson, A. Nilsson, L. Rylander, A. Schutz, S. Skerfving, and J. Borjesson. 2001. Effects of lead on the endocrine system in lead smelter workers. *Arch Environ Health.* 56:449-455.
- Esmekaya, M.A., N. Seyhan, and S. Omeroglu. 2010. Pulse modulated 900 MHz radiation induces hypothyroidism and apoptosis in thyroid cells: a light, electron microscopy and immunohistochemical study. *Int J Radiat Biol.* 86:1106-1116.
- Formigari, A., P. Irato, and A. Santon. 2007. Zinc, antioxidant systems and metallothionein in metal mediated-apoptosis: biochemical and cytochemical aspects. *Comp Biochem Physiol C Toxicol Pharmacol.* 146:443-459.
- Freake, H.C., K.E. Govoni, K. Guda, C. Huang, and S.A. Zinn. 2001. Actions and interactions of thyroid hormone and zinc status in growing rats. *J. Nutr.* 131:1135-1141.
- Gustafson, A., P. Hedner, A. Schutz, and S. Skerfving. 1989. Occupational lead exposure and pituitary function  
*Int. Arch. Occup. Environ. Health.* 61:277-281.
- Hartoft, M., A. Rasmussen, U. Rasmussen, K. Buschard, and T. Bock. 2005. Estimation of number of follicles, volume of colloid and inner follicular surface area in the thyroid gland of rats. *J. Journal of Anatomy.* 207:117-124.
- Hayat, M.A. 1986. Preparation of the tissue for E/M studies. In: Hayat MA, editor. Basic techniques for transmission electron microscopy. Academic Press, New York. p. 220.
- Hong, R.T., J.M. Xu, and Q. Mei. 2009. Melatonin ameliorates experimental hepatic fibrosis induced by carbon tetrachloride in rats. *World journal of gastroenterology : WJG.* 15:1452-1458.
- Hsu, P.C., and Y.L. Guo. 2002. Antioxidant nutrients and lead toxicity. *Toxicology.* 180:33-44.
- Ingbar, S. 1985. The thyroid gland. Textbook of endocrinology. Vol. 7th ed. WB Saunders, London.
- Jarrar, B.M. 2001. Ultrastructural Ultrations in Proximal Tubule Cells Induced by Lead. *Pakistan Journal of Biological Science.* 4(10):1281-1284.
- Kelly, G.S. 2000. Peripheral metabolism of thyroid hormones: a review. *Altern Med Rev.* 5:306-333.
- Khotimchenko, M., I. Sergushchenko, and Y. Khotimchenko. 2004. The effects of low-esterified pectin on lead-induced thyroid injury in rats. *Environ Toxicol Pharmacol.* 17:67-71.
- Kralik, A., K. Eder, and M. Kirchgesner. 1996. Influence of zinc and selenium deficiency on parameters relating to thyroid hormone metabolism. *Horm Metab Res.* 28:223-226.
- Landrigan, P.J., P. Boffetta, and P. Apostoli. 2000. The reproductive toxicity and carcinogenicity of lead: a critical review. *Am J Ind Med.* 38:231-243.
- Lee, K.H., S.K. Lee, H.S. Kim, E.J. Cho, H.K. Joo, E.J. Lee, J.Y. Lee, M.S. Park, S.J. Chang, C.H. Cho, J.B. Park, and B.H. Jeon. 2009. Overexpression of Ref-1 Inhibits Lead-induced Endothelial Cell Death via the Upregulation of Catalase. *Korean J Physiol Pharmacol.* 13:431-436.
- Loeffler, M., and G. Kroemer. 2000. The mitochondrion in cell death control: certainties and incognita. *Exp Cell Res.* 256:19-26.
- Malekirad, A.A., S. Oryan, A. Fani, V. Babapor, M. Hashemi, M. Baeeri, Z. Bayrami, and M. Abdollahi. 2010. Study on clinical and biochemical toxicity biomarkers in a zinc-lead mine workers. *Toxicol Ind Health.* 26:331-337.
- Meyer, P.A., M.J. Brown, and H. Falk. 2008. Global approach to reducing lead exposure and poisoning. *Mutat Res.* 659:166-175.
- Miquelis, R., and C. Simon. 1981. The thyroid lysosomal system: dynamic state of the organelles in relation to iodine release. *Eur J Cell Biol.* 24:70-73.
- Morley, J.E., J. Gordon, and J.M. Hershman. 1980. Zinc deficiency, chronic starvation, and hypothalamic-pituitary-thyroid function. *Am J Clin Nutr.* 33:1767-1770.

- Nakazawa, T., S. Murata, T. Kondo, N. Nakamura, T. Yamane, S. Iwasa, and R. Katoh. 2008. Histopathology of the thyroid in amiodarone-induced hypothyroidism. *Pathol Int.* 58:55-58.
- Napolitano, G., G. Palka, S. Lio, I. Bucci, P. De Remigis, L. Stuppia, and F. Monaco. 1990. Is zinc deficiency a cause of subclinical hypothyroidism in Down syndrome? *Ann Genet.* 33:9-15.
- Nishiyama, S., Y. Futagoishi-Suginohara, M. Matsukura, T. Nakamura, A. Higashi, M. Shinohara, and I. Matsuda. 1994. Zinc supplementation alters thyroid hormone metabolism in disabled patients with zinc deficiency. *J Am Coll Nutr.* 13:62-67.
- Patrick, L. 2006. Lead toxicity part II: the role of free radical damage and the use of antioxidants in the pathology and treatment of lead toxicity. *Altern Med Rev.* 11:114-127.
- Pavia Junior, M.A., B. Paier, M.I. Noli, K. Hagmuller, and A.A. Zaninovich. 1997. Evidence suggesting that cadmium induces a non-thyroidal illness syndrome in the rat. *J Endocrinol.* 154:113-117.
- Piao, F., F. Cheng, H. Chen, G. Li, X. Sun, S. Liu, T. Yamauchi, and K. Yokoyama. 2007. Effects of zinc coadministration on lead toxicities in rats. *Ind Health.* 45:546-551.
- Rao-Rupanagudi, S., R. Heywood, and C. Gopinath. 1992. Age-related changes in thyroid structure and function in Sprague-Dawley rats. *Vet Pathol.* 29:278-287.
- Silbergeld, E.K., M. Waalkes, and J.M. Rice. 2000. Lead as a carcinogen: experimental evidence and mechanisms of action. *Am J Ind Med.* 38:316-323.
- Singh, B., V. Chandran, H.K. Bandhu, B.R. Mittal, A. Bhattacharya, S.K. Jindal, and S. Varma. 2000. Impact of lead exposure on pituitary-thyroid axis in humans. *Biometals.* 13:187-192.
- Soltaninejad, K., A. Kebriaeezadeh, B. Minaiee, S.N. Ostad, R. Hosseini, E. Azizi, and M. Abdollahi. 2003. Biochemical and ultrastructural evidences for toxicity of lead through free radicals in rat brain. *Hum Exp Toxicol.* 22:417-423.
- Wade, M.G., S. Parent, K.W. Finnson, W. Foster, E. Younglai, A. McMahon, D.G. Cyr, and C. Hughes. 2002. Thyroid toxicity due to subchronic exposure to a complex mixture of 16 organochlorines, lead, and cadmium. *Toxicol Sci.* 67:207-218.
- Wang, J., Z. Yang, L. Lin, Z. Zhao, Z. Liu, and X. Liu. 2011. Protective Effect of Naringenin Against Lead-Induced Oxidative Stress in Rats. *Biol Trace Elem Res.* Nov 23.
- Wollman, S.H., J.P. Hervég, and O. Tachiwaki. 1990. Histologic changes in tissue components of the hyperplastic thyroid gland during its involution in the rat. *Am J Anat.* 189:35-44.
- Wuehler, S.E., J.M. Pearson, and K.H. Brown. 2005. Use of national food balance data to estimate the adequacy of zinc in national food supplies: methodology and regional estimates. *Public Health Nutr.* 8:812-819.
- Xia, D., X. Yu, S. Liao, Q. Shao, H. Mou, and W. Ma. 2010. Protective effect of Smilax glabra extract against lead-induced oxidative stress in rats. *J Ethnopharmacol.* 130:414-420.
- Yoshizuka, M., N. Mori, K. Hamasaki, I. Tanaka, M. Yokoyama, K. Hara, Y. Doi, Y. Umezue, H. Araki, Y. Sakamoto, and et al. 1991. Cadmium toxicity in the thyroid gland of pregnant rats. *Exp Mol Pathol.* 55:97-104.
- yousif, A.S., and A.A. Ahmed. 2010. Effects of Cadmium and Lead on the structure and function of thyroid gland. *Afri. J. Anim. Biomed. Sci.*, 5 (1):13-25.