

The Protective Role of Ginseng against N- nitrosodimethylamine Induced Hepatic Toxicity in Male albino Rats (A Histological & Ultra structure Study)

Mona Ahmed

Zoology Dept, Girls Collage for Arts, Science and Education, Ain Shams Univ. Egypt

Monaf_123@hotmail.com

Abstract: Objective was to evaluate the possible improvement in the histological and ultra structural features of liver of rats treated with N-nitrosodimethylamine(NDMA)together with Ginseng extract (G). In the present investigation a total number of 40 male adult albino rats of approximately similar body weigh (90 ± 10 gm) were used. Animals were divided into four groups the first group of rats served as control (C), the second group received a single intraperitoneal dose of NDMA (20 mg/kg b.wt.), the third group received intraperitoneal dose of NDMA (20 mg/kg b.wt.) and 20 mg/kg of Ginseng extract by intramuscular injection, the fourth group received intramuscular injection doses (20 mg/kg b.wt.) of Ginseng extract daily, all groups were treated of experimental duration for 1 month. Liver was prepared for histopathological, and ultra structure studies . NDMA administration induced hepatotoxicity compared to G treated group, including dissolution of hepatic cords, focal inflammation and necrotic tissue. Interestingly, interacting group also exhibited abnormal changes, including per portal fibrosis, degeneration of hepatic cords and increased mononuclear inflammation infiltrate .These changes were confirmed at ultra structural level, including vesiculated rough endoplasmic reticulum and atrophied mitochondria with ill differentiated asternae , dense collection of macrophages and lymphocytes as well as fibrocytes with collagenous fibrosis. On the contrary, in animals received G extract only, the hepatic tissue revealed improvement of the histology and ultrastructure of the tissues which became almost similar to the control group tissue. It is possible to suggest that G may have a significant important in protection against NDMA induced hepatic damage.

[Mona Ahmed. **The Protective Role of Ginseng against N- nitrosodimethylamine Induced Hepatic Toxicity in Male albino Rats (A Histological & Ultra structure Study)**. Journal of American Science 2012;8(4):722-729]. (ISSN: 1545-1003). <http://www.americanscience.org>. 95

Key words: N-nitrosodimethylamine ,Ginseng, Hepatotoxicity.

1. Introduction

Dimethyl nitrosoamine (NDMA) is a representative chemical of a family of N-nitroso compounds and has been found in processed meats and industrial products. It is a potent hepatotoxin, carcinogen and mutagen (George *et al.*, 2001). Sofos and Raharjo (1995) postulated that nitrite at excessive levels is a chronic toxic agent for human and animals. In addition , nitrite may react with nitrogenous compounds in foods or *in vivo* to form carcinogenic N-nitroso compounds such as nitrosamines. Uibu *et al.* (1996) & Choi and Valentine (2001) reported that Nitrosodimethylamine in samples of sausages, hamburgers and salmon roe. These items were made from fish and / or whale meat, which form part of the raw materials. Dimethylamine naturally present in these materials and sodium nitrite added in the manufacture of the sausages or the hamburgers had combined to form nitrosodimethylamine .In addition, no nitrosamine was detected in cod roe , but when it was tested again after it had been soaked in a 1% sodium nitrite solution for 24 hours, over 1 mg/kg nitrosodimethyl-amine and nitrosodiethylamine were detected. Trace amounts of NDMA in milk of 10 human mothers from 54 milk samples was formed in

chlorinated treated waste water. Virender *et al.*,(2010) detected also, nitrogen-containing pollutants have been found in surface waters and industrial wastewaters due to their presence in pesticides, dyes, proteins, and humic substances. Reynolds (2001) pointed out that NDMA produced a variety of adverse health effects in human following both short and long term exposures. Health risks were suspected to occur at levels in the range parts per billion (ppb) and parts per trillion (ppt). The author added that exposures may occur from multiple sources i.e. food, water, air and environmental pollutants and produce varied responses in different individuals. Symptoms may be delayed and not be evident for year. In addition, *Ginseng* is a plant of medical importance and it has been used by elderly Asian to boost physical and mental vitality (Kiritikar & Basu, 1987). The biological name is *Panax ginseng*. The most important part of *ginseng* is the root and its chemical constituents are arabinose, comphor mucilage, resin, starch and saponin. *Panax ginseng* is a potent antioxidant since it acts as an active free radical scavenger (Xiaoguang *et al.*, 1998). It reduces tissue damage, reinforces the immune system and helps to keep blood sugar levels under control (Kitts *et al.*, 2000). It has been reported

that *ginseng* can reduce chromosomal aberration induced by some chemicals (Umnova *et al.*, 1991). Ginsan is a polysaccharide isolated from the root of *Panax ginseng* C.A. Meyer, and acts as a potent immunomodulator that promotes the generation of several cytokines (TNF- α , IL-1 β , IL-2, IL-6, IL-12, IFN- γ , GM-CSF) and stimulates proliferation of lymphoid cells (Lee *et al.*, 1997; Kim *et al.*, 1998; Shin *et al.*, 2002; Song *et al.*, 2002). Moreover, ginseng possesses significant chemo-/radioprotective properties (Song *et al.*, 2003), partly through modulation of antioxidant systems and regulation of cytokines and Studies by Taik-Koo *et al.*, 2001, Sakarkar & Deshmukh, 2011 suggest that ginseng may lower the risk of cancer in humans.

The present study investigated whether ginsan affects acute hepatic injury and the underlying mechanisms of action, including hepatic oxidative stress and inflammation.

2. Material and Methods

N-Nitrosodimethylamine is commonly known as NDMA. It is a yellow liquid which has no distinct odor. It is produced in the U.S. only for use as a research chemical and was supplied by Sigma Chemical Co. it is of technical grade and had 91% purity. Ginseng extract was obtained from Sigma Chemical Co.

Adult male Wistar albino rats (*Rattus norvegicus*), each weighing ~90 g they were obtained from National Research Centre, Dokki, Egypt. The animals were allowed for 10 days before the experiment to adapt to the laboratory conditions. They had free access to water and commercial standard food. Rats were randomly divided into 4 groups each of 10 animals. Animals were observed daily and body weights were recorded before initial dosing and at weekly intervals thereafter. The first group of rats served as control (C). The second group received a single intraperitoneal dose of NDMA (20 mg/kg) (Ebenezer *et al.*, 2009). The third group received intraperitoneal dose of NDMA (20 mg/kg) and 20 mg/kg of Ginseng extract (Ahmed *et al.*, 2010) by intramuscular injection. The fourth group received intramuscular injection doses (20 mg/kg) of Ginseng extract daily, all groups were treated of experimental duration for 1 month. The animals were weighed individually before decapitation. Five animals of each of the four groups were killed by decapitation (to avoid animal stress) after 1 month. Animals were rapidly dissected and the liver was cleaned and weighed; very small liver pieces were processed for electron microscopic examination. Other samples were immediately fixed in 10% formalin solution for histological examination.

Small pieces of the liver were immediately fixed in 10% formalin solution, dehydrated in a graded series of alcohol, embedded in a paraffin wax, sectioned at 6 μ m and stained with hematoxylin and eosin. The stained sections were examined and photographed under a light microscope. Liver tissue from both control and treated groups were immediately fixed in 2.5% glutaraldehyde and 2% paraformaldehyde in 0.1 M cacodylate buffer (pH 7.4). After rinsing in 0.1 M cacodylate buffer, samples were post fixed in a buffered solution of 1% osmium tetroxide at 4°C for 1.5 hour. This was followed by dehydration in ascending grades of ethyl alcohol (30%, 50%, 70%, 90%, and absolute) and embedded in epoxy-resin. Ultrathin sections were obtained with a diamond knife on a LKB microtome and mounted on formvar-coated grids, stained with uranyl acetate and lead citrate and examined by transmission electron microscope (JEOL-EX1010 transmission electron microscope at Ain-Shams university).

3. Result

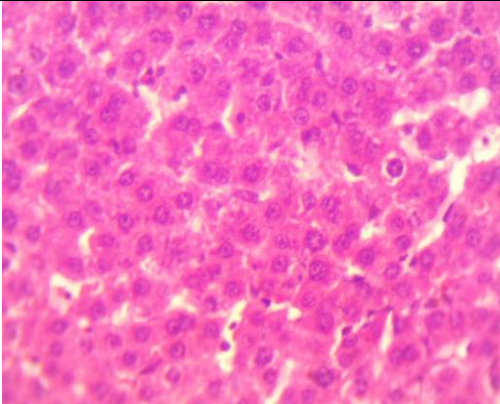
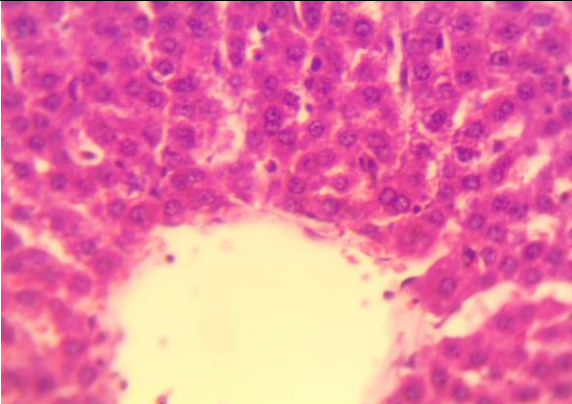
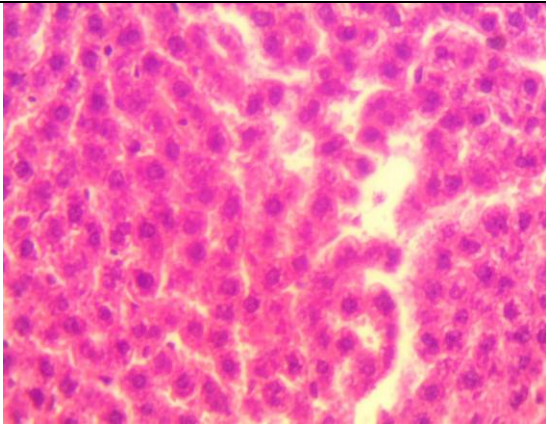
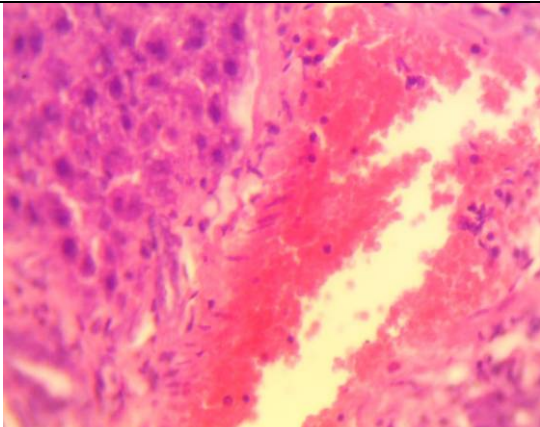
Histological studies:

Light microscopic observation revealed that control hepatic tissue showed normal polygonal cells with prominent round nuclei and eosinophilic cytoplasm and few spaced hepatic sinusoids arranged in between the hepatic cords with fine arranged kuffer cells (Fig.1a,b). The most pronounced histopathological abnormalities observed in rats treated with NDMA involved dissolution of hepatic cords, which appeared as empty vacuoles aligned by strands of necrotic hepatocytes (Fig. 2a&b). The hepatic tissue showed presence of dense focal inflammatory cells (Fig. 3). Liver fibrosis manifested by the presence of many spots of focal cellular granular lesions (Fig. 4). As for the interacting groups (NDMA & G) resulted in common histopathological alterations including per vascular round cell infiltration, associated with membrane changes of endothelial lining cells manifesting per portal fibrosis (Fig. 5), marked degeneration of hepatic cords, increased incidence of vacuolar degeneration (Fig. 6). As for G treated group similar results as that of control group (Fig. 7).

The electron microscopic examination of control hepatocytes showed normal polygonal with oval shaped nuclei, cytoplasm crowded with organelles particularly rough endoplasmic reticulum, smooth endoplasmic reticulum, Golgi apparatus, ribosome mitochondria and glycogen particles (Fig. 8). In contrast, the hepatocytes of liver from group with NDMA showed margination and clumping of chromatin and marked increase in heterochromatin was seen in some nuclei (Fig. 9). Nuclei with irregular

nuclear membrane, the cytoplasm contained vesiculated rough endoplasmic reticulum (Fig. 10). Atrophied mitochondria with ill differentiated cisternae (Fig. 11). The hepatic tissue showed numerous spots of densely collected inflammatory cells composed mainly of macrophages and lymphocytes and a number of fibrocytes (Fig. 12

a&b). The interacted group showed better ultra structure images apart from densely collected inflammatory cells, mild swelling cellular of mitochondria was observed and mild dilation of Golgi apparatus (Fig. 13a&b). As for G treated group similar images to that of the control was almost observed.

	
<p>Fig 1a): Section of liver from control rat showing polygonal cells with prominent round nuclei and eosinophilic cytoplasm and few spaced hepatic sinusoids arranged in between the hepatic cords with fine arranged kuffer cells(HEX400)</p>	<p>Fig 1b): Section from control rat showing normal liver. (H-E-X400)</p>
	
<p>Fig 2a): Section of liver from rat after treated with NDMA showing involved dissolution of hepatic cords, which appeared as empty vacuoles (H-E-X400)</p>	<p>Fig 2b): Section of liver from rat after treated with NDMA showing necrotic hepatocytes (H-E-X400)</p>

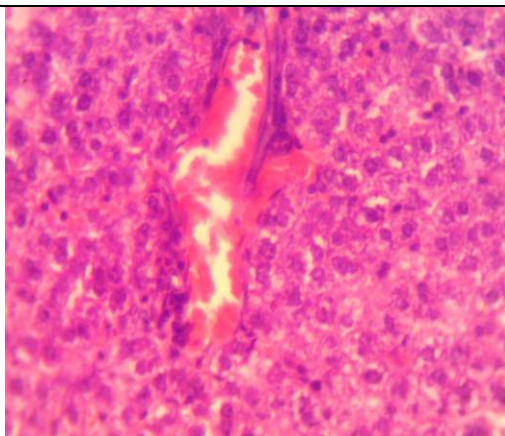


Fig 3): Section of liver from rat after treated with NDMA the hepatic tissue showed presence of dense focal inflammatory cells (H-E-X400) .

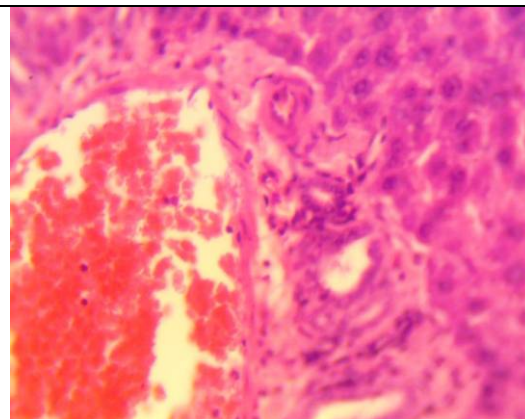


Fig 4): Section of liver from rat after treated with NDMA liver fibrosis manifested by the presence of many spots of focal cellular granular lesions (H-E-X400) .

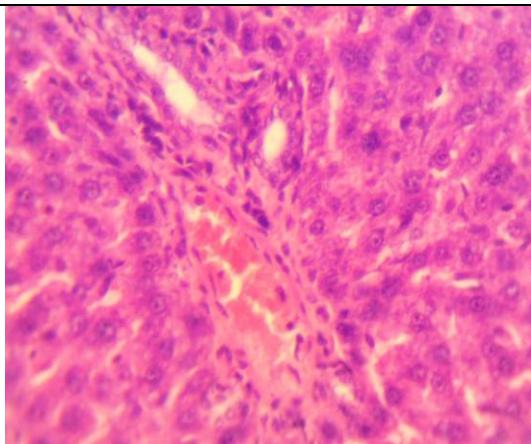


Fig 5): Section of liver from rat of interacted group showed including per vascular round cell infiltration, associated with membrane changes of endothelial lining cells manifesting per portal fibrosis . (H-E-X400) .

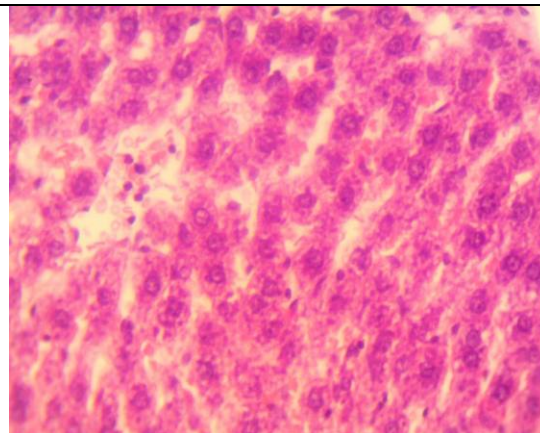


Fig 6): Section of liver from rat of interacted group showed degeneration of hepatic cords, increased incidence of vacuolar degeneration (H-E-X400) .

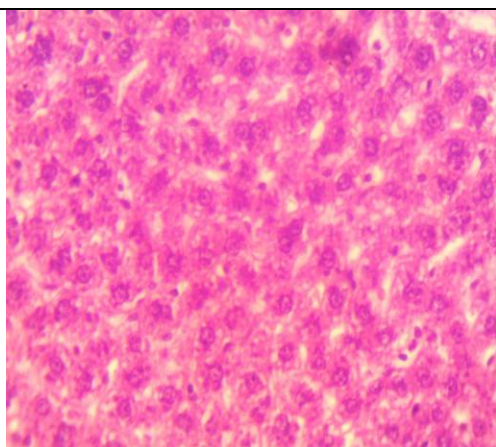


Fig 7): Section of liver of rat treated with gensing group showed similar results as that of control group. (H-E- X400) .

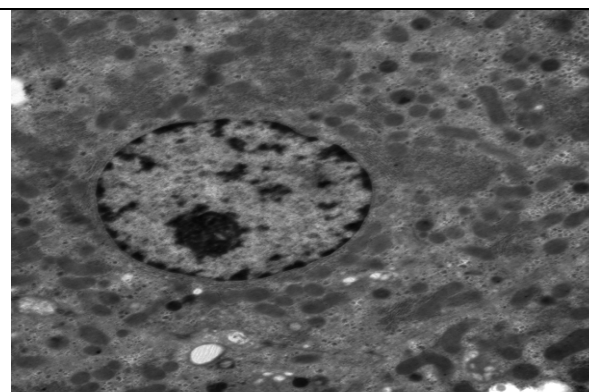


Fig 8) The electron microscopic examination of control hepatocytes showed normal polygonal with oval shaped nuclei, cytoplasm crowded with organelles X2000.

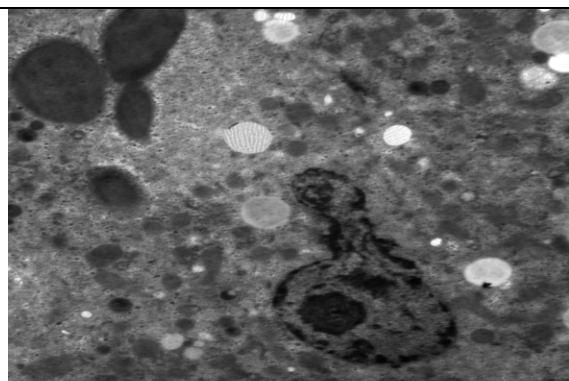


Fig9) The electron microscopic examination of liver from group treated with NDMA showed nuclei with irregular nuclear membrane, and margination and clumping of chromatin and marked increase in heterochromatin X2000




Fig 10) The electron microscopic examination of liver from group treated with NDMA showed nuclei with irregular nuclear membrane, the cytoplasm contained vesiculated rough endoplasmic reticulum. X4000

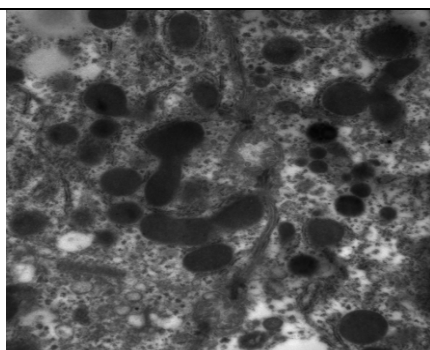


Fig 11) The electron microscopic examination of liver from group treated with NDMA showed atrophied mitochondria with ill differentiated cisternae of liver X4000

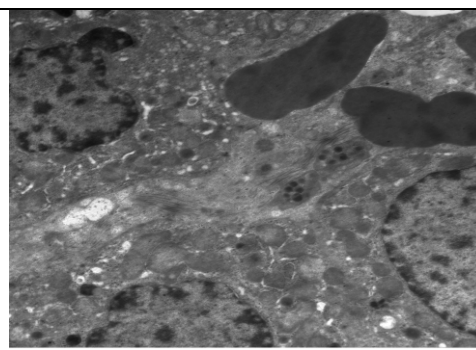


Fig 12a) The electron microscopic examination of hepatic tissue from group treated with NDMA showed numerous spots of densely collected inflammatory cells composed mainly of macrophages and lymphocytes and a number of fibrocytes X2000 .

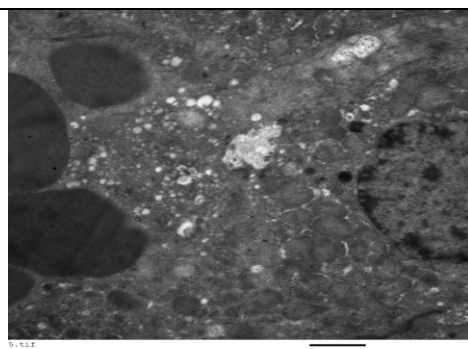


Fig 12b) The electron microscopic examination of hepatic tissue showed numerous spots of densely collected inflammatory cells composed mainly of macrophages and lymphocytes and a number of fibrocytes X2000 .

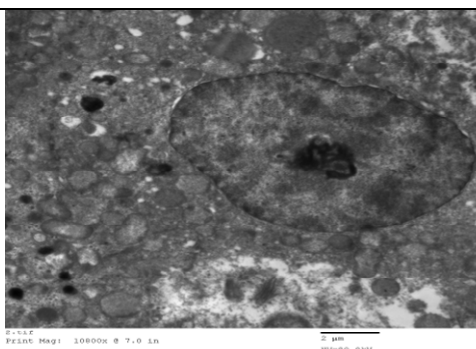


Fig 13a) The electron microscopic examination of hepatic tissue of interacted group showed mild swelling cellular of mitochondria and mild dilation of golgi apparatus X2000




Fig 13b) The interacted group showed better ultra structure images apart form densely collected inflammatory cells, mild swelling cellular of mitochondria was observed and mild dilation of golgi apparatusX2000

4. Discussion

In the present study NDMA induced histological alteration in liver on both levels of examination using light and electron microscope. The light microscopic examination revealed changes after treatment with NDMA, such as peripheral fibrosis, degeneration of hepatic cords and increased mononuclear inflammatory infiltrated and dilated blood sinusoids. Many hepatocytes showed karyolysis and pyknotic nuclei indicating apoptosis (Stewart *et al.*, 1982; Chin *et al.*, 1993 & Liao *et al.*, 2008). Cell death can result from physiological or pathological apoptosis described by Farber (1994). Hepatotoxicity may be induced by many chemicals; it may produce necrosis, as in the hepatotoxicity induced by NDMA (Ledda *et al.*, 1991) or it may occur concurrently with necrosis as in hepatotoxicity associated with acetaminophen (Knight, 2003). As cisplatin NDMA is thought to kill cells primarily by forming DNA adducts, causing G2 arrest in the cell cycle, triggering apoptosis (Kishimoto *et al.*, 2000). More over (Kim *et al.*, 1999) suggested that DNMA induce apoptosis through the down activity of A-dependent kinase.

The ultra structure examination of hepatocytes of treated group showed margination

and clumping chromatin and marked increase in heterochromatin, irregular nuclear membranes in vesiculated rough endoplasmic reticulum, dilated and fragmented Golgi complex, atrophied and degenerated mitochondria, this indicated that thus must be a causal relation between apoptosis and hepatocytes degeneration (Shan-xa *et al.*, 2006). In addition to above mentioned, NDMA is as suggested play an important role in degeneration hepatocytes and cell death (Mattson *et al.*, 1998).

In general, interaction between ginseng and NDMA particularly if delivered over a more

protected time course, induced apoptosis while higher levels of NDMA alone induce necrosis (Shan-xa *et al.*, 2006), while intermediate concentrations after induce a mixture of necrosis and apoptosis. These research results also confirm the present hypothesis. In the present study the administration of ginseng improved the histological and ultra structure of the hepatic tissues since it contain compounds which inhibit toxicity released by NDMA. This inhibition may be responsible for ginseng anti-inflammatory effect. Jeong *et al.* (1997) suggested that G displays a pronounced hepatoprotective effect, assessed through the transaminases (ALT, AST) activities following hepatotoxicity in rats treated with carbon tetrachloride. Moreover, administration of G significantly reduced the activities of ALT and AST induced by dexamethasone (DEN) administration in rats (Lin *et al.*, 1995). Ginseng also was found to protect against liver toxicity induced by CCL4 through the inhibition of cytochrome P450-associated monooxygenase activities (Kim *et al.*, 1997). Therefore, the protective effect of KGE in the current study is attributable to its free radical scavenging activity (Abdel-Wahhab and Ahmed, 2004; Mannaa *et al.*, 2006 Abdel-Fattah *et al.*, 2010). Similar to the current observations, Yun *et al.* (1987) reported that prolonged administration of Korean red ginseng extract resulted in substantial suppression of pulmonary tumorigenesis induced by AFB1. Non-saponin components in red ginseng suppressed the harmful effects of free oxygen radicals (O_2 , H_2O_2 , OH_2), which exercise an important role in tissue degeneration (Kim *et al.*, 1997).

In the conclusion preservatives such as NDMA caused direct hepatic toxicity, our results provide by evidence, at light microscope and ultra structural levels of direct hepatotoxicity caused by NDMA,

furthermore, this study identified pathological features of both structural and ultra structural levels for the NDMA and the protective antioxidant role of ginseng or at least the reduction of damage induced by NDMA using ginseng in the interacting group. It is possible to suggest that G may have a significant important in protection against NDMA induced hepatic damage.

Corresponding author

Mona Ahmed

Zoology Dept, Girls Collage for Arts, Science and Education, Ain Shams Univ. Egypt

Monaf_123@hotmail.com

5. References

- Abdel- Fattah, Sh. M. 1; Sanad, M.I2.; Safaa,M.A2 and Ragaa F. F.Ghanem (2010):The Protective Effect of White Ginseng against Biochemical and Pathological Changes Induced by Aflatoxins in Rats. *Journal of American Science*; 6(12)461-472.
- Abdel-Wahhab, M.A., Ahmed, H.H. (2004): Protective effects of Korean *panax ginseng* against chromium VI toxicity and free radical generation in rats. *J. Ginseng Res.* 28: 11-17.
- Ahmed A. El-Kady, Hafiza A. Sharaf, Ahmed S. Gad, Fathia A. Mannaa, Nabila S. Hassan, Mosaad A. Abdel-Wahhab .(2010): Whey Protein Concentrate and Ginseng Extract Exhibit Antioxidant Properties *in vitro* and Reduce Hepatotoxicity and Oxidative Stress of Aflatoxin *in vivo* . *New York Science Journal*; 3(11)37-51.
- Chin, Valentia M. Lee, Michael C. Archer(1993):Evidence that the hepatotoxicity of N-nitrosodimethylamine in the rat is unrelated to DNA methylation *Wei Chem. Res. Toxicol.*, 6 (3), pp: 372–375
- Choi, J. and Valentine, R.L. (2001): Formation of N-nitrosodimethylamine in chloraminated water: A new disinfection by product. *Dept. of civil and environmental engineering, Univ. of Iowa Seamans Center, IA 52242, Fax: 319-335.*
- Ebenezer O. Farombi, Sangeeta Shrotriya, Young-Joon Surh.(2009): Kolaviron inhibits dimethyl nitrosamine-induced liver injury by suppressing COX-2 and iNOS expression via NF- κ B and AP-1 . *Life Sciences*, 84 :149–155 .
- Farber E. (1994): Programmed cell death: Necrosis versus apoptosis. *Mod Pathol.*;7:605-609
- George, J., Rao, K.R., Stern, R., Chandrakasan, G.(2001): Dimethylnitrosamine-induced liver injury in rats: the early deposition of collagen. *Toxicology*, 156:129–138.
- Hassan I El-Sayyad, Mohamed F Ismail, F M Shalaby, RF Abou-El-Magd, Rajiv L Gaur (2009): Histopathological effects of cisplatin, doxorubicin and 5-fluorouracil (5-FU) on the liver of male albino rat. *Int J Biol Sci.*; 5(5):466-473.
- Jeong, T.C., Kim, H.J., Park, J.I., Ha, C.S., Kim, S.I., Rho, J.K. (1997): Protective effects of red ginseng saponins against carbon tetrachloride-induced hepatotoxicity in Sprague-Dawley rats. *Planta Med.* , 63: 136-140.
- Kim, H.J., Chun, Y.J., Park, J.D., Kim, S.I., Roh, J.K., Jeong, T.C. (1997): Protection of rat liver microsomes against carbon tetrachloride-induced lipid peroxidation by red ginseng saponin through cytochrome P450 inhibition. *Planta Med.*, 63:415-418 .
- Kim, K.H., Lee, Y.S., Jung, I.S., Park, S.Y., Chung, H.Y., Lee, I.R., Yun, Y.S.(1998): Acidic polysaccharide from *Panax ginseng*, ginsan, induces Th1 cell and macrophage cytokines and generates LAK cells in synergy with rIL-2. *Planta Med.*, 64:110–115.
- Kim, S.E., Lee, Y.H., Park, J.H., Lee, S.K. (1999): Ginsenoside-Rs4, a new type of ginseng saponin concurrently induces apoptosis and selectively elevates protein levels of p53 and p21WAF1 in human hepatoma SK-HEP-1 cells. *Eur. J. Cancer*, 35(3): 507-511.
- Kirtikar, K.and Basu, B. (1987): In *Indian medicalplants*ed By Blatter, J. Caius & K. Mhaskar, 3: 1773-1779, International Book Distribution, Dehradun.
- Kishimoto S, Miyazawa K, Terakawa Y, Ashikari H, Ohtani A, Fukushima S, Takeuchi Y. (2000): Cytotoxicity of cis-[(1R,2R)-1,2-cyclohexanediamine-N,N')bis(myristato)]-platinum (II) suspended in Lipiodol in a newly established cisplatin-resistant rat hepatoma cell line. *Jpn J Cancer Res.*;91:1326-32
- Kitts, D.; Wija Wickreme, A. and Hu, C. (2000): Antioxidants properties of a North American ginseng extract: *Mol, Cell. Biochem.*, 203(1-2):1-10.
- Knight TR, Fariss MW, Farhood A, Jaeschke H. (2003): Role of lipid peroxidation as a mechanism of liver injury after acetaminophen overdose in mice. *Toxicol Sci.*;76:229-36
- Ledda-Columbano GM, Coni P, Curto M, Giacomini L, Faa G, Oliverio S, Piacentini M, Columbano A.(1991): Induction of two different modes of cell death, apoptosis and necrosis, in rat liver after a single dose of thioacetamide. *Am J Pathol.* ;139:1099-1109
- Lee, Y.S., Chung, I.S., Lee, I.R., Kim, K.H., Hong, W.S., Yun, Y.S.,(1997):Activation of multiple effector pathways of immune system by the antineoplastic immunostimulator acidic polysaccharide ginsan isolated from *Panax ginseng*. *Anticancer Res.*, 17:323–331.

- Liao Y, Lu X, Lu C, Li G, Jin Y, Tang H. (2008): Selection of agents for prevention of cisplatin-induced hepatotoxicity. *Pharmacol Res.*; **57**:125-31
- Lin, J.H., Wu, L.S., Tsai, K.T., Leu, S.P., Jeang, Y.F., Hsieh, M.T. (1995): Effects of ginseng on the blood chemistry profile of Dexamethasone-treated male rats. *Am. J. Clin. Med.*, **23**:167-172.
- Mannaa, F., Abdel-Wahhab, M.A., Ahmed, H.H., Park, M.H. (2006): Protective role of panax ginseng extract standardized with ginsenoside Rg3 against acrylamide-induced neurotoxicity in rats. *J. Appl. Toxicol.*, **26**: 198-206.
- Mattson MP, Keller JN, Begley JG. (1998): Evidence for synaptic apoptosis. *Exp. Neurol.*, **153**(1):35-48
- Reynolds, K.A. (2001): N-nitrosodimethylamine is emerging contaminant in water a substantial human health risk. WCP online www.wcponline.com/archive/novooontap.htm
- Sakarkar D.M., Deshmukh V.N. Sudhakararao (2011): Ethnopharmacological Review of Traditional Medicinal Plants for Anticancer Activity International Journal of PharmTech Research Vol. 3, No.(1);, pp 298-308, Jan-Mar . CODEN (USA): IJPRIF ISSN : 0974-4304
- Shan-xia LI, Ning Cui, Cui-lizhang (2006): Effect of subchronic exposure to Acrylamide induced on the expression of bel-2 bax and caspase-3 in the rat nervous system. *Toxicology* (217)46-53.
- Shin, J.Y., Song, J.Y., Yun, Y.S., Yang, H.O., Rhee, D.K., Pyo, S. (2002): Immunostimulating effects of acidic polysaccharides extract of Panax ginseng on macrophage function. *Immunopharmacol. Immunotoxicol.*, **24**: 469-482.
- Simpson, K.J., Lukacs, N.W., Colletti, L., Strieter, R.M., Kunkel, S.L. (1997): Cytokines and the liver. *J. Hepatol.*, **27**: 1120-1132.
- Sofos, J.N. and Raharjo, S. (1995): Food additive toxicology. Chapter (5) curing agents. Maga, J.A. and Anthony, T. Colorado State Univ. Fort Collins, Colorado. pp: 235-267.
- Song, J.Y., Han, S.K., Son, E.H., Pyo, S.N., Yun, Y.S., Yi, S.Y. (2002): Induction of secretory and tumoricidal activities in peritoneal macrophages by ginsan. *Int. Immunopharmacol.*, **2**: 857-865.
- Song, J.Y., Han, S.K., Bae, K.G., Lim, D.S., Son, S.J., Jung, I.S., Yi, S.Y., Yun, Y.S., (2003): Radioprotective effects of ginsan, an immunomodulator. *Radiat. Res.*, **159**: 768-774.
- Stewart DJ, Benjamin RS, Luna M. (1982): Human tissue distribution of platinum after cis-diamminedichloroplatinum. *Cancer Chemother Pharmacol.*; **10**:51-54
- Taik-Koo Yun, Yun-Sil Lee, You Hui Lee, Shin Il Kim, Hyo Yung Yun (2001): Anticarcinogenic Effect of *Panax ginseng* C.A. Meyer and Identification of Active Compounds. *J Korean Med Sci*; **16**(Suppl): S6-18
- Uibu, J. ; Tauts, O. ; Levin, A. ; Shimanovskaya, N. and Matto, R. (1996): N- nitrosodimethylamine, nitrate and nitrite-reducing microorganisms in human milk. *Acta. Paediatrica*, **85**(10): 1140-1142.
- Umnova, N V.; Michurina, T.I.; Smirnova, N.I.; Rova, I.V. and Povoshenko, G. (1991): Study of anti-mutagenic properties of biogenser in mammalian cells *in vitro* and *in vivo*: *Bull. Esp. Bioi. Med.*, **111**(5): 507-509.
- Valentia M. Lee, Ross G. Cameron and Michael C. Archer (1998): Zonal Location of Compensatory Hepatocyte Proliferation Following Chemically Induced Hepatotoxicity in Rats and Humans *Toxicol Pathol.*, **26**: 621.
- Virender K. Sharma (2010): Oxidation of nitrogen-containing pollutants by novel ferrate(VI) technology: A review *Journal of Environmental Science and Health, Part A: Toxic/Hazardous Substances and Environmental Engineering* Volume 45, Issue(6);, pages 645-667.
- Xiaoguang, C.; Hongyann, L.; Xiaohong, Z.; Zhaodi, F.; Yan, L.; Lihua, T. and Rui, H (1998) : Cancer chemopreventive and therapeutic activities of red ginseng. *J. Ethoph.armacol.*, **60**(1): 71-78.
- Yun, Y.S., Jo, S.K., Moon, H.S., Kimn, Y.J., Oh, Y.R., Yun, T.K. (1987): Effect of red ginseng on natural killer cell activity in mice with lung adenoma induced by urethane and benzo[a]pyrene. *Cancer Detect. Prev. (Suppl.)* **1**:301-309.

3/8/2012