

## Electron Microscopic Study On The Effect Of Urocortin-1 And Selective Endothelin Type A Receptor Blockade On kidney Cortex Of Preeclamptic Pregnant Rats

Manar E<sup>1</sup>. Selim and Hayam I. Gad<sup>2</sup>

Zoology Department, Faculty of Science, and Physiology Department, Faculty of Medicine, King Saud University  
[manar.selim@hotmail.com](mailto:manar.selim@hotmail.com)

**Abstract:** Preeclampsia is a pregnancy-specific disorder that complicates approximately 5% of all pregnancies, making it perhaps the most common glomerular disease in the world. The current study was carried out on 125 female Wistar rats divided into five equal groups. Group I included virgin non-pregnant rats. Group II included pregnant rats that were received saline solution (0.5 ml/100 g body weight) from day 7 to day 20 of gestation. Group III included pregnant rats that were treated with L-NAME dissolved in sterile saline solution in a dose of 10 mg/0.5 ml/100 g body weights subcutaneously and daily starting from the same day of gestation and for the same duration as mentioned for group II. Group IV included pregnant rats that were treated by both L-NAME (the same dose and for the same duration as mentioned for group III) and urocortin-1, in a dose of 5 µg/kg body weight/ day subcutaneously starting from day 14 to day 20 of gestation. Group V included pregnant rats that were treated by both L-NAME (the same dose and for the same duration as mentioned for group III) and ABT-627, 5 mg/kg / day subcutaneously starting from day 14 to day 20 of gestation. Ultrathin sections from the kidney were processed for electron microscopic examination. The ultrastructural examination of group III showed damage of the parietal epithelium of Bowman's capsules, thickening of the capillary endothelial wall and fusion of the foot process of the podocytes. Mesangial cells and matrix were greatly increased. Moreover, the cells of the proximal convoluted tubules (PCTs) showed degeneration of the brush border and its lumina appeared with hyaline casts. The distal convoluted tubules (DCTs) were affected also as represented by destruction of the basal infoldings, mitochondria and the apical microvilli. The electron microscopic results revealed that the treatment of preeclamptic rats with urocortin-1 lead to apparent repair of the injured renal tissues rather than ABT-627 that might suggest its use as helpful therapeutic line for alleviation nephrotoxicity in preeclampsia .

[Manar E.Selim and Hayam I.Gad. **Electron Microscopic Study On The Effect Of Urocortin-1 And Selective Endothelin Type A Receptor Blockade On kidney Cortex Of Preeclamptic Pregnant Rats.** Journal of American Science 2011; 7(12):162-171]. (ISSN: 1545-1003). <http://www.americanscience.org>.

**Keywords:** Pregnancy, preeclampsia, PCTs, endothelial cell, podocyte.

### 1. Introduction

Preeclampsia remains a leading cause of infant and maternal morbidity and mortality (Duley, 2009). The glomerular endothelial cell has been established as the main site of renal injury, but recent data also emphasize the importance of the podocyte in preeclampsia. The release of factors injurious to the maternal endothelium from an abnormal placenta is now thought to underlie the pathophysiology of preeclampsia and renal involvement is invariable with glomerular dysfunction manifest as hypertension, depression of the glomerular filtration rate (GFR), and proteinuria (Chapman et al, 1998). Normal pregnancy is characterized by vasodilation resulting in reduction of peripheral vascular resistance. Blood pressure begins to decrease early in the first trimester. The events initiating these changes are not completely understood, but human chorionic gonadotropin-induced increased production of relaxin by the corpus luteum may facilitate vasodilation in normal pregnancy (Jeyabalan et al, 2003). Relaxin up-regulates vascular gelatinase activity, thereby contributing to vasodilation and reduced myogenic reactivity of small arteries through activation

of the endothelial endothelin B receptor-nitric oxide (NO) pathway. Angiogenic factors such as vascular endothelial growth factor (VEGF) also may have an important function in the increased production of NO and prostacyclin in pregnancy via pathways involving phospholipase C, mitogen-activated protein kinase, and protein kinase C (He et al, 1999 ). To speculate that the balance between vasodilatory (NO, prostacyclin) and vasoconstrictive (thromboxane A<sub>2</sub>, endothelin) substances, and in parallel the balance between angiogenic and anti-angiogenic factors, are important determinants of blood pressure in pregnancy.

Animal studies have elucidated that impaired up-regulation of NO production leads to vasoconstriction. The infusion of pregnant rats with the NO synthase inhibitor, N<sup>G</sup>-nitro-L-arginine methyl ester, results in hemodynamic changes that are reminiscent of human preeclampsia (Danielson and Conrad, 1995). Also, in animal model supplementation with L-arginine increased NO production, increased blood pressure, and reversed many physiological parameters measured in our previous study (Hayam and Manar, 2011). In human beings, impaired NO production likely factors

into the pathogenesis of preeclampsia, but is clearly accompanied by other important factors. Increased levels of asymmetric dimethylarginine (ADMA), an endogenous NO synthase inhibitor, have been shown to precede the clinical syndrome of preeclampsia (Holden et al, 1998 & Pettersson et al, 1998). But L-arginine has not been shown to have any beneficial effect on the course of the disease (Staff et al, 2004 & Hladunewich et al, 2006). The pathophysiology of pre-eclampsia is much more than the increased blood pressure and altered renal function that facilitate diagnosis. The feature that characterized the pre-eclamptic placenta is its exposure to decreased perfusion secondary to abnormal placentation that leads to the release of cytotoxic factors causes maternal endothelial damage and dysfunction in a variety of organs (Gratten et al, 2001). Whereas pregnancy is associated with striking modifications of the spiral arteries that provide the blood supply to the placenta, these changes do not take place normally in pre-eclampsia (Brosens et al, 1979). In normal pregnancy, the luminal diameter of the spiral arteries is enlarged and the walls are remodelled such that they contain very little smooth muscle. These changes extend into the vessels to the inner third of the myometrium to provide a large bore, flaccid, low-resistance circuit for perfusion of the intervillous space. These modifications are associated with endovascular invasion of fetal trophoblast into these maternal vessels. Endovascular invasion and spiral artery remodeling occur either very superficially or not at all in pre-eclampsia. It seems likely that this abnormal implantation may be immunologically mediated. Preeclampsia occurs mainly in first pregnancies suggesting that exposure to paternal antigen is protective. This idea is supported by the increased risk of those who carry a pregnancy by a new father (Mills et al, 1991).

Perfusion is decreased not only to the placenta but also to virtually all organs. This reduction in tissue perfusion is secondary to intense vasospasm due to an increased sensitivity of the vasculature to any pressor agent. Perfusion is proposed to be further compromised by activation of the coagulation cascade, especially platelets, with attendant microthrombi formation (Mills et al, 1991). Additionally, plasma volume is decreased by loss of fluid from the intravascular space, further compromising organ blood flow. The search for proximate pathophysiological changes requires identification of early alterations present before the profoundly disordered state that occurs with overt disease. With this provision, increased platelet activation and markers of endothelial activation antedate clinically evident pre-eclampsia by weeks to months in groups of women destined to develop the disorder. This finding has led to the unifying notion that vascular endothelium could be an early target for

pathophysiological modification in pre-eclampsia (Trupin et al, 1996). This hypothesis is supported by the well established morphological alteration of glomerular capillary endothelium that accompanies the disorder, the presence of increased circulating concentrations of numerous markers of endothelial activation, and by alterations of endothelial function in vessels obtained from women with pre-eclampsia and examined in vitro.

A deficiency of NO could thus result in vasoconstriction, eventually leading to elevated blood pressure and local or disseminated intravascular coagulation, and thereby demonstrating the feature of preeclampsia. In pregnant animals chronic inhibition of NO synthesis reverses refractoriness to angiotensin and vasopressin and eventually produces a preeclampsia-like syndrome (Molnar et al, 1994). Several investigators reported the inhibition of NO synthesis with analogues of L-arginine such as N<sup>G</sup>-nitro-L-arginine methyl ester (L-NAME) caused hypertension, proteinuria, fetal growth retardation, and increased fetal mortality without affecting gestational length (Kitamura et al, 1993). These phenomena are remarkably similar to preeclampsia. Therefore, L-NAME-treated rats can be used as an animal model of preeclampsia.

Urocortin-1 levels do not change during pregnancy (Vaughan et al, 1995), and no gestational age-related changes in placental urocortin-1 mRNA expression (Cooke and Davidge, 2003) have been found. However, maternal plasma urocortin-1 levels were higher at labor, but they did not change significantly throughout the different stages of spontaneous labor (Suda et al, 2004), suggesting an involvement of the placental neuropeptide in the mechanisms promoting uterine contractility. In cultured human trophoblast cells, the addition of urocortin-1 significantly increased trophoblast ACTH secretion in a dose-dependent manner (Hsu and Hsueh, 2001). In explants of human placental tissue at term, the addition of urocortin-1 stimulated prostaglandin E<sub>2</sub> (PGE<sub>2</sub>) release by tissues in a dose dependent manner, and the urocortin-1- and CRF-induced PGE<sub>2</sub> release were not significantly different (Khan and Ng LL, 2004). Starting from the observations that urocortin-1 produces in rats a prolonged hypotensive effect when administered intravenously; (Rademaker, 2002), the role for urocortin-1 in intraplacental blood flow regulation was postulated. Human urocortin-1 caused concentration-dependent relaxation of the fetal placental vasculature (Florio et al, 2002). As the fetal vessels of the human placenta were not innervated, control of blood flow in this vascular bed is partly dependent on locally produced and circulating vasoactive factors (Faceted and Gorilla, 2007). Since syncytiotrophoblast cells express urocortin-1 during pregnancy (Florio et al, 2000), placental urocortin-1 may

affect the fetal-placental circulation by paracrine or endocrine mechanisms. It may be released locally to affect the vascular smooth muscle and endothelium via action at CRF receptors, or it may be secreted into the fetoplacental circulation and travel to its site of action through the placental vascular system. Supporting the physiological relevance of this function, pregnant women with impaired uterine artery blood flow during mid-gestation exhibit significantly reduced circulating urocortin-1 levels in proportion to the degree of increased arterial resistance (Torricelli et al, 2006). Finally, urocortin-1 may maximize the release of products such as ACTH or PGs (Brosens et al, 1979).

Previous studies have reported that the elevated ET-1 concentrations can have significant long-term effects on systemic hemodynamics and arterial pressure regulation (McMahon et al, 1993). Thus, long-term elevations in plasma ET-1 concentrations comparable to those measured in women with preeclampsia may play a role in mediating the reductions in renal function and elevations in arterial pressure observed in women with preeclampsia. Although some studies have reported no significant changes in circulating ET-1 concentrations during moderate forms of preeclampsia, a possible role for ET-1 as a paracrine or autocrine agent in preeclampsia remains worthy of consideration. Local synthesis of ET has been assessed in preeclamptic women, and investigators have found preproendothelin mRNA to be elevated in a variety of tissues (Greenberg et al, 1997). Owing to the limitations of clinical studies using selective ETA receptor antagonists in pregnant women, the importance of locally produced ET in the pathophysiology of preeclampsia remains unclear.

Based on the scarcity of ultrastructural study on the cortex of preeclamptic rats kidney treated with urocortin -1 or ABT-627, the present study was conducted to compare their role in minimizing the toxicity induced by L-NAME.

## 2, Materials and Methods

The current study was carried out on 125 female Wistar rats supplied by Medical College animal house at King Khalid University Hospital (King Saud University). Their average weight was 250-300 g. They were 13-18 weeks old. They were housed in a controlled environment and get free access to water *ad libitum*. Two or three cycling female rats were housed with a male for 24 hours. The presence of sperms in vaginal smears was considered as day 1 of pregnancy. Rats were divided into five groups (25 rats each) according to the following experimental design:

Group I: included virgin non-pregnant rats. Group II: included pregnant rats that were received saline

solution (0.5 ml/100 g body weight) subcutaneously and daily starting from day 7 to day 20 of gestation. Group III: included pregnant rats that were treated with L-NAME dissolved in sterile saline solution in a dose of 10 mg/0.5 ml/100 g body weights subcutaneously and daily starting from the same day of gestation and for the same duration as mentioned for group II, to make an animal model of preeclampsia (Curtis et al, 1995). Group IV: included pregnant rats that were treated by both L-NAME (the same dose and for the same duration as mentioned for group III) and urocortin-1, in a dose of 5 µg/kg body weight/ day subcutaneously starting from day 14 to day 20 of gestation (Davidge et al, 1996). Group V: included pregnant rats that were treated by both L-NAME (same dose and for the same duration as mentioned for group III) and ABT-627, 5 mg/kg / day (McCarthy et al, 1993) starting from day 14 to day 20 of gestation. For electron microscopic examination, ultrathin sections (60 nm in thickness) were cut on the RMC MT-7 ultramicrotome by using a diamond knife. Doubly stained sections with uranyl acetate and lead citrate were examined under a Joel EX 1200 Transmission electron microscope at the central lab, King Saud University.

## 3. RESULTS

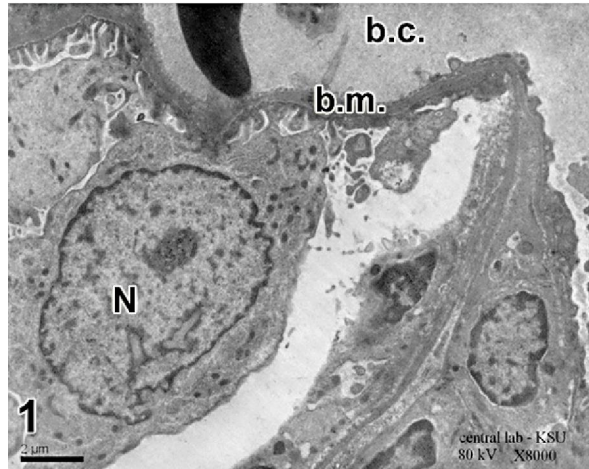
### Group I&II

Electron microscopic study of control animals and non pregnant group showed no difference. The inner wall of the Bowman's capsule is called the visceral or podocyte layer formed of specialized cells called podocyte (Fig.1). Each podocyte has several processes which give rise to secondary processes known as "pedicles". These processes resting upon the basement membrane of the glomerulus leaving narrow slits between them called filtration slits (Fig.2).

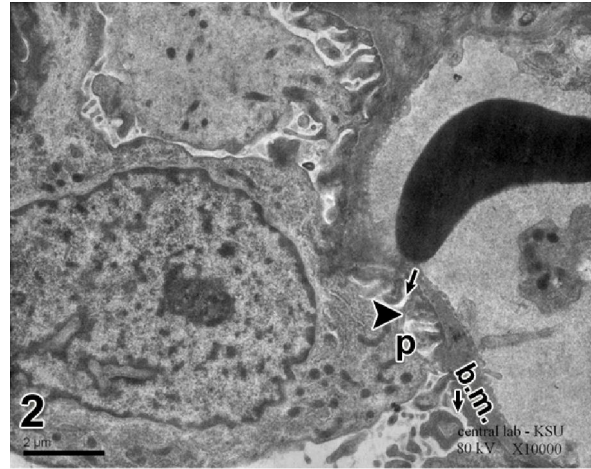
The cells of the proximal convoluted tubules (PCTs) have an elaborate shape, well developed microvilli (or brush border) along their lumina, an active endocytotic apparatus, and many spherical or elongated mitochondria. The nuclei of the cells are relatively large, mostly euchromatic lying on the basal portion of the cells (Fig.3).

The cells of the distal convoluted tubules (DCTs) do not have a brush border but a few luminal microvilli are seen (Fig.4). Mitochondria are not interposed between the nucleus and the apical membrane, but do fill the compartment between the basal enfolding. The nuclei are relatively large and their heterochromatin appears always attached the nuclear membrane. They are located in the apical part of the cytoplasm (Fig.4).

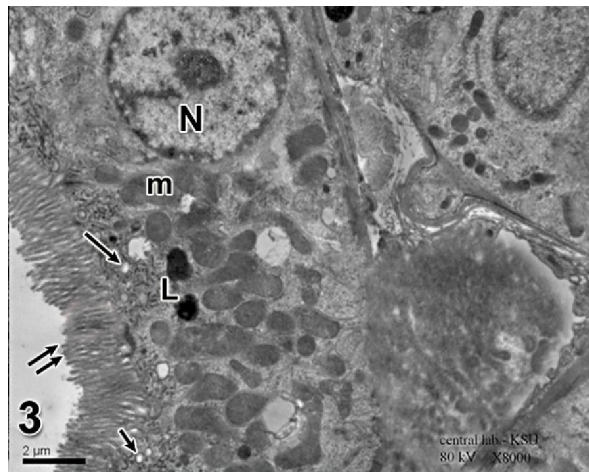




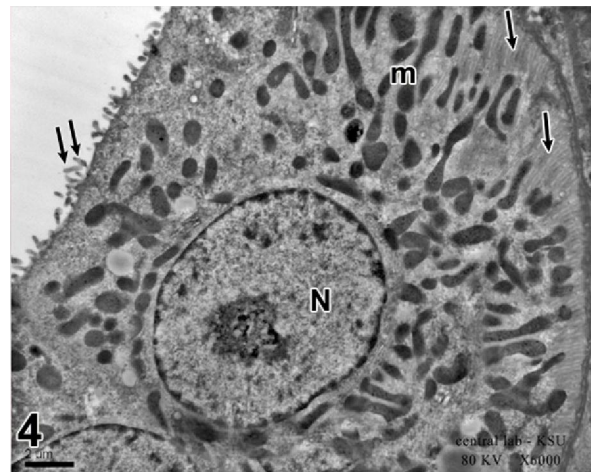
**Fig.1:** Showing nucleus of epithelial cell podocyte (N) with irregular cell border. Notice the blood capillary (b.c.) with normal basement membrane. Control group, TEM x 8000



**Fig.2:** Higher magnification of fig. 1 showing large cytoplasmic processes (arrow head) and small cytoplasmic pedicles (P) resting on basement membrane (b.m.) and leaving slit-like pores (arrows) in between. Control group, TEM x10000



**Fig.3:** Showing normal appearance of proximal convoluted tubules. Notice the nuclei of lining cells (N) located in the basal part of the cytoplasm. Numerous mitochondria (m) and the apical microvilli (double arrow) constituting a brush border, below which lies the endocytotic apparatus (arrows). Notice the presence of secondary lysosomes (L). Control group, TEM x 8000



**Fig.4:** Showing the normal appearance of distal convoluted tubule cells with basal infoldings (arrows) and linear arrangement of the mitochondria (m). Euchromatic nucleus (N). Notice the apical microvilli (double arrow) which do not take the brush border form. Control group, TEM x 6000

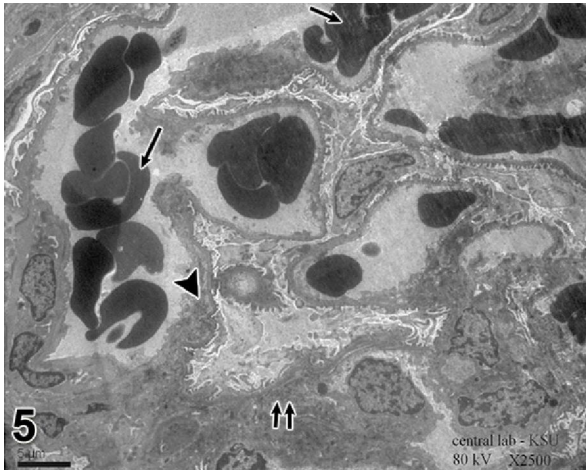### Group III

Electron microscopic results of this group revealed congested blood capillaries with apparent increase in the thickness of the glomerular basement membrane in certain areas (Fig.5). Besides, an increase in the mesangial cells and matrix (Fig.6). Foot processes of the podocytes were frequently fused (Fig.5), thus obliterating the filtration slits. Most of

the PCTs manifested marked alterations of their normal fine structure after L-NAME treatment. Marked accumulation of hyaline casts in the lumina of the tubules was noticed (Figs. 7& 8). The endocytotic apparatus also showed distortion where the small and large vacuoles were fused forming irregular vocalized apical areas (Fig.8). Most of the mitochondria appeared with indistinguishable cristae (Figs 7& 8). In

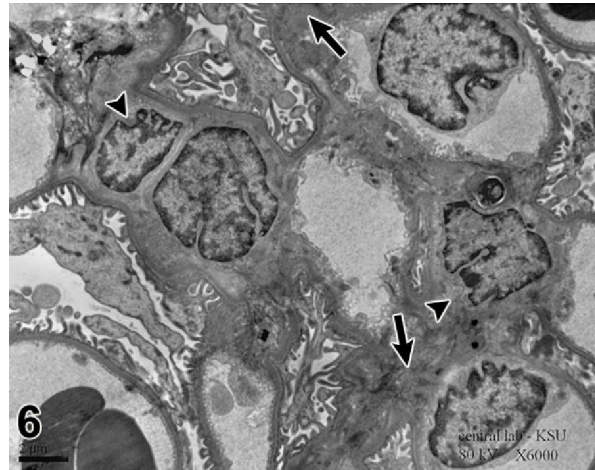
addition to the deformed, stunted basal enfolding that were manifested in most of the PCTs (Figs. 7& 8). In spite of the profound damage of the PCTs caused by L-NAME, yet the ultra-structural observations revealed distortion of the basal enfolding,

mitochondria and apical microvilli (Fig.9). However, the nuclei appeared non affected but the nucleolus was not clearly demonstrated in the PCTs and DCTs (Figs.7,8 & 9).



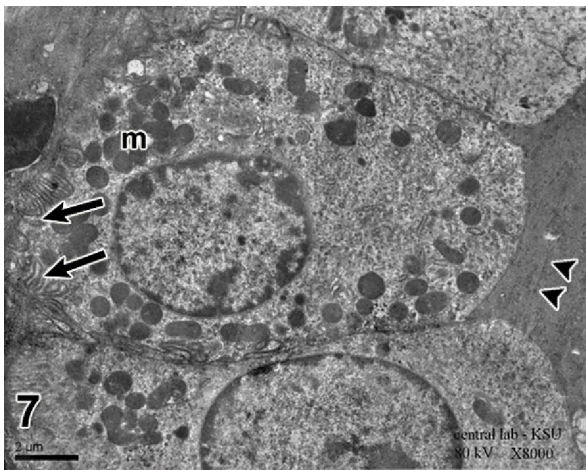
**Fig.5:** Showing congested blood capillaries (arrows). Most of the podocytes showing fusion of the foot processes (double arrow). Notice the thickening of the basement membrane of the blood capillary (arrow head).

L-NAME treated group, TEM x2500

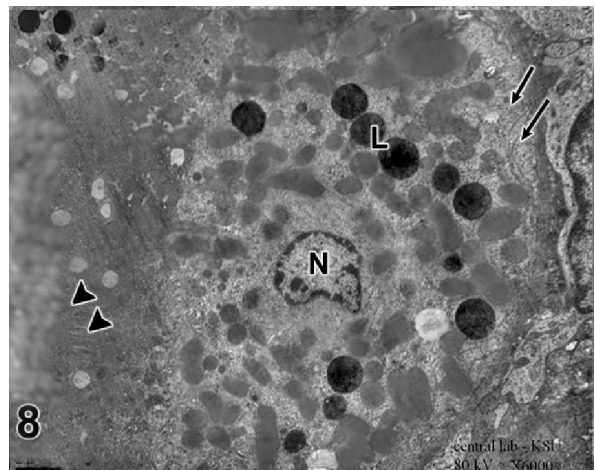


**Fig.6:** Showing increased mesangial cells (arrow heads) and mesangial matrix (thick arrow).

L-NAME treated group, TEM x6000



**Fig.7:** Showing loss of apical microvilli of PCTs and the lumen of the tubule filled with hyaline cast (arrow heads). Stunted, deformed basal infoldings (thick arrows) with irregular distribution of mitochondria (m). L-NAME treated group, TEM x8000



**Fig.8:** Showing distorted basal infoldings (arrows), numerous lysosomes (L). Notice the lumen is filled with hyaline cast (arrow heads) and the nucleus (N) is shrunken with in apparent nucleolus.

L-NAME treated group, TEM x 6000



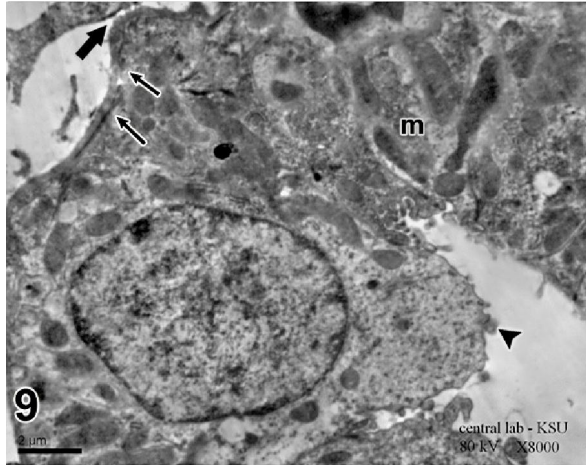
**Group IV:**

Electron microscopic results of this group were similar to control group. Most of the PCTs and DCTs are more or less in normal appearance confirmed the same features observed in control group (Figs 12 & 13). Moreover, the podocytes were projecting from the surface of the glomerular capillaries into the capsular space in normal appearance (Fig. 11). The mesangial cells and matrix were not affected (Fig. 10). Also, the capillary lumina showed normal appearance

and the endothelial cells were clearly demonstrated (10).

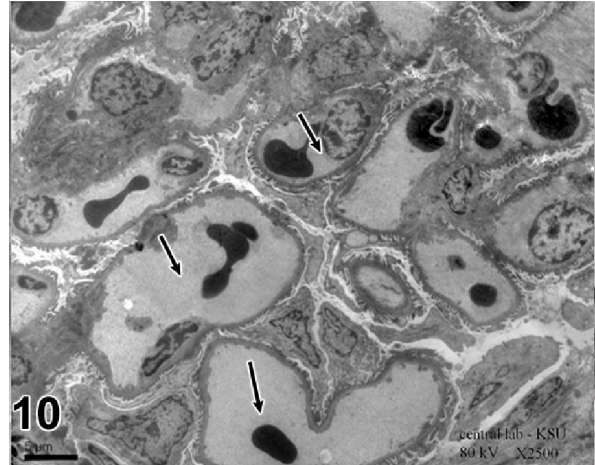**Group V:**

Electron microscopic results of this group showed occasionally fused foot processes of some podocytes, were noticed (Fig. 14). The treatment of ABT-627 with L-NAME was associated with the presence of hyaline cast in some lumina of PCTs (Fig. 15) and distorted apical microvilli in the DCTs (Fig. 16).



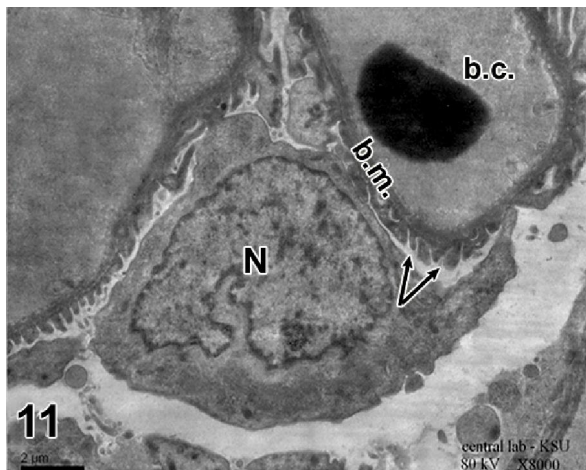
**Fig.9:** Showing DCT with distorted basal infoldings (arrows) and detached irregular basement membrane (thick arrow). Notice distorted apical microvilli (arrow head) and mitochondria (m).

L-NAME treated group, TEM x 8000



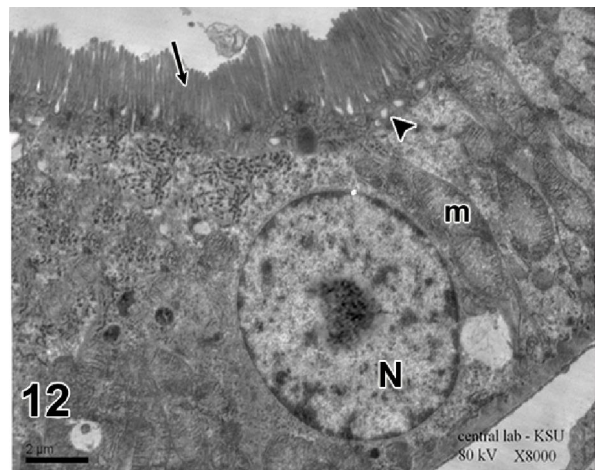
**Fig.10:** Showing normal blood capillaries lined with normal endothelial cells (arrows).

Urocortin-1 and L-NAME treated group, TEM x 2500



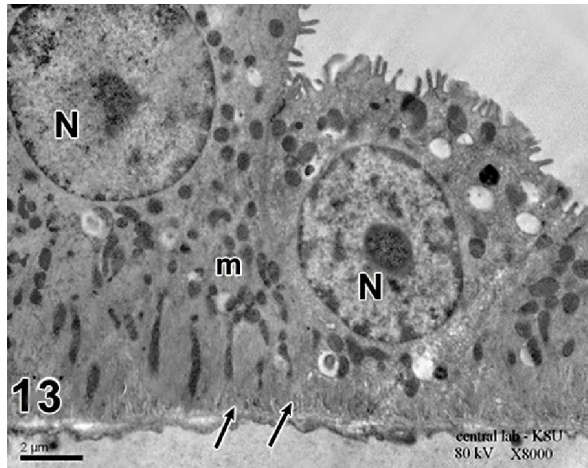
**Fig.11:** Showing typical normal nucleus of podocyte (N) with normal foot processes (arrows) lying on normal blood capillary (b.c.) with normal basement membrane (b.m.).

Urocortin-1 and L-NAME treated group, TEM x 8000

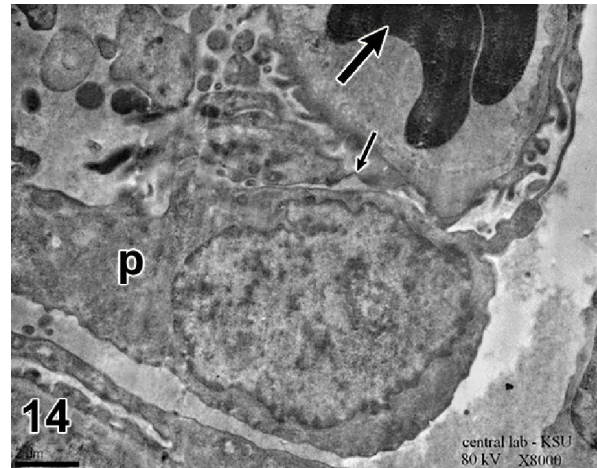


**Fig.12:** Showing normal appearance of PCT with normal distribution of mitochondria (m). Notice the brush border (arrow), endocytotic apparatus (arrow head) and the euchromatic nucleus (N).

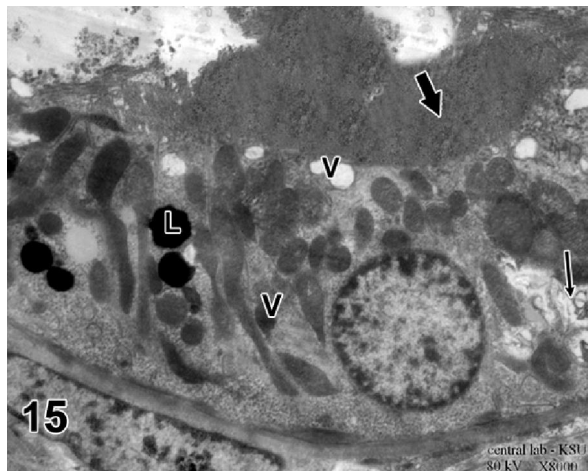
Urocortin-1 and L-NAME treated group, TEM x 8000



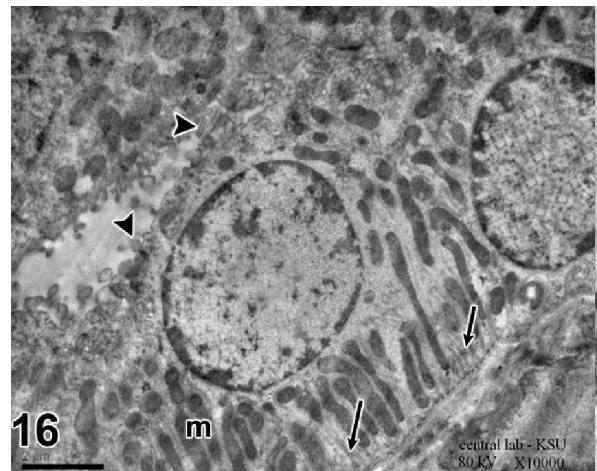
**Fig.13:** Showing normal DCTS with normal mitochondria (m) located mainly in the compartments found between the basal infoldings (arrows). Notice the nucleus (N) in the apical cytoplasmic region. Urocortin-1 and L-NAME treated group, TEM x 8000



**Fig.14:** Showing podocyte (P) with occasionally fused foot processes (arrow) lying on congested blood capillary (thick arrow). ABT-627 and L-Name treated group, TEM x8000



**Fig.15:** Showing nearly normal PCT with lysosomes (L), vacuoles (V) and vacuolar changes (arrow). Notice hyaline cast in the lumen (thick arrow). ABT-627 and L-Name treated group, TEM x8000



**Fig.16:** Showing normal DCT with normal basal infoldings (arrows) and mitochondria (m). Notice distorted apical microvilli (arrow heads). ABT-627 and L-Name treated group, TEM x 10000

#### 4. Discussion

Ultrastructural analysis is the definitive way to demonstrate nephrotoxicity and, in some cases, may be required to confirm the diagnosis. The nephrotoxicity caused by L-NAME in group III was recorded by the electron microscopic study in the proximal convoluted tubules, where loss of apical microvilli and distorted basal infoldings with severe

destruction and loss of the irregular arrangement of mitochondria were noticed (Figs 5&6). It has been stated that mitochondrial dysfunction was seen as an early event in the process of nephrotoxicity (Wang et al, 2000). The authors added mitochondrial dysfunction leads to diminished ATPase and hence diminished energy-dependent sodium pump with the result that sodium accumulates intracellularly with



increased influx of  $Ca^{++}$  and diffusion of potassium out of the cell. The increase of cytosolic  $Ca^{++}$  leads to phospholipids degradation of the cell membrane as well as mitochondrial membrane. The ultra structural study (Fig.5&6) also showed apparent thickening of the basement membrane of the renal corpuscle which could be due to vasoconstriction of the blood capillaries caused by L-NAME concomitant with congestion that affect the mechanism of ultrafiltration, leading to an increased immune reaction on the basement membrane. Local fusion of foot processes of the visceral epithelial cells and loss of regular endothelial lining of the capillaries were recorded in preeclampsia (Karumanchi et al, 2005). Such changes in the basement membrane are similar to those occurring in proteinuria (Karumanchi et al, 2005 & Kulling et al, 2004). This might explain the nucleolar changes observed in this group in PCTs and DCTs (Figs. 7, 8 & 9) and also in group V (Figs.15 & 16) that may be added to the factors induce nephrotoxicity. The podocyte cell layer, which lines the urinary space or Bowman's capsule and greatly affected in this work, is believed by many to be the primary filtration barrier to the passage of large molecular weight proteins. Unfortunately, the exact role of the endothelial cell layer to the regulation of glomerular permselectivity remains the least well defined (Karumanchi et al, 2005). Other investigators have suggested that all three layers of the glomerular wall endothelium, basement membrane, and slit diaphragm—may jointly constitute the barrier against proteinuria. (Deen, 2004) argued that proteinuria can occur with endothelial disruption alone, which may explain the significant proteinuria noted with endotheliosis. More recently, yet another antiangiogenic protein, was reported to play a pathogenic role in preeclampsia (Venkatesha et al, 2006). Vascular maladaptation in manifest preeclampsia may be explained on the basis of angiotensin II-mediated mechanisms through angiotensin receptor type I (AT1) activation (McCarthy et al, 1993). Cooke and Davidge (2003) mentioned that mice were noted to have endotheliosis and hyaline casts deposits in their kidneys during preeclampsia (Cooke and Davidge, 2003). Similar results were noticed in our investigation in group III and group V (Figs7, 8&15). Moreover, distorted apical microvilli in DCTs were also noted in the same previous group (Figs. 9&16).

The renal vasculopathy and glomerulosclerosis induced by L-NAME in this study could be due to endothelial dysfunction leading to vascular wall thickening and the available surface area for filtration was decreased (Figs 5&6). The damage of the endothelial lining of the capillaries might lead to an increased flux of macromolecular substances into

mesangium which by its turn overload the mesangial cells. In that case, meningeal cells become stimulated to produce matrix (Fig.6). Similar results were reported by Venkatesha et al. 2006 who added that arteriopathy lead to hypertension and kidney injury that manifested in preeclampsia. In conjunction with our result, the author (Fergus et al, 2011) revealed that the peroxisome proliferator-activated receptor- $\gamma$ -specific antagonist, T0070907 treated rats with developed key features of preeclampsia, including elevated mean arterial blood pressure, proteinuria, endothelial dysfunction could result in reduced pup weight). It's worthy to note that preeclampsia is a disease of vascular inflammation that lead to vascular remodeling and abnormalities of blood flow that affect the kidney cortex. The inflammatory reactions caused by increased leukocyte activation, which has been implicated in the endothelial dysfunction and organ damage observed in preeclampsia may be added to the factors induced nephrotoxicity.

Such immune reactions may participate in the vascular injury encountered in L-NAME treated rats in our study (Figs.5&6) that still intact in group V (Fig.14) and might lead to nephropathy and their migration into the kidney could be considered as crucial step in the progression of preeclampsia. Our results were in harmony with other investigators who reported that nephrotoxicity may produce various reactive oxygen species, proinflammatory cytokines, tumour necrosis factor and interleukin 1 (TNF and IL-1) and growth factor which increase inflammation within preeclamptic kidney leading to vascular injury (Zhu et al, 2007).

Concerning the effect of urocortin -1 and ABT-627 against preeclampsia from the ultrastructural point of view. The changes were detected as mitochondrial dysfunction and the development of the apical microvilli of the PCTs & DCTs that were greatly affected in ABT-627 treated group (Figs15&16) but remain unaffected in urocortin -1 treated animals (Figs12&13). Also, the presence of lysosomes denoting absorption of abnormal particles (Fig.15). The hyaline casts in the lumina of some PCTs was investigated in ABT-627 treated group (Fig.15) but disappeared in urocortin-1 treated group (Fig.12). In addition to the congested blood capillaries and occasionally fusion of foot processes of podocytes that still intact in ET-1 treated animals (Fig14) and disappeared in group IV (Figs.10&11). In spite of the strong correlation of L-NAME induced preeclampsia in pregnant rats and the incidence of hypertension concomitant with glomerulus and tubular damage, the present results assured on the ultrastructural ground that urocortin -1 could be advantageous than ABT-627 in counteracting the toxic effect of L-NAME.



Starting from the previous observations that the role for urocortin-1 in intraplacental blood flow regulation was postulated (Trupin et al, 1996), human urocortin-1 caused concentration-dependent relaxation of the fetal placental vasculature (Molnar et al, 1994). Other authors suggested that the fetal vessels of the human placenta were not innervated, control of blood flow in this vascular bed is partly dependant on locally produced and circulating vasoactive factors (Kitamura et al, 1993). Since syncytiotrophoblast cells express urocortin-1 during pregnancy (Vaughan et al, 1995), placental urocortin-1 may affect the fetal-placental circulation by paracrine or endocrine mechanisms. It may be released locally to affect the vascular smooth muscle and endothelium via action at corticotrophin-releasing factor (CRF) receptors, or it may be secreted into the feto-placental circulation and travel to its site of action through the placental vascular system. Supporting the physiological relevance of this function, pregnant women with impaired uterine artery blood flow during mid-gestation exhibit significantly reduced circulating urocortin-1 levels in proportion to the degree of increased arterial resistance (Cooke and Davidge, 2003).

In conclusion, the application of electron microscopy in the present study has the merit of bringing into vision numerous details on the urocortin-1 protective role (as compared to ABT-627) which could be considered a good remedy in kidney problems that counteracts the pathological impairments caused by L-NAME as a new target of therapeutic approach to preeclampsia.

### Acknowledgements

The investigators are very grateful to King Abdulaziz City for Science and Technology (KACST) for grant extended for this project, No LGP-14-15. We are also grateful to the Vice Rector for Higher Studies and Research, King Saud University and his advisors for their kind cooperation and understanding.

### Corresponding author

Manar E. Selim

Zoology Department, Faculty of Science, King Saud University

[manar.selim@hotmail.com](mailto:manar.selim@hotmail.com)

### REFERENCES

1. **Brosens, I.A.; Robertson, W.B. and Dixon, H.G. (1979).** The role of the spiral arteries in the pathogenesis of preeclampsia. In: R Wynn, Editor. *Obstetrics and Gynecology Annual*. 177–191.
2. **Chapman, A.B.; Abraham, W.T; Zamudio, S. et al. (1998).** Temporal relationships between hormonal and hemodynamic changes in early human pregnancy. *Kidney Int.*; 54:2056-63.
3. **Cooke, C.L.; Davidge, S.T. (2003).** Preeclampsia-induced alterations of vascular function in mouse mesenteric and uterine arteries. *Biol Reprod.*, 68 (3): 1072-1077.
4. **Curtis, N.E.; Gude, N.M.; King R.G.; Marriott, P.J.; Rook, T.J.; Brennecke, S.P. (1995).** Nitric oxide in normal human pregnancy and preeclampsia. *Hypertens Preg.*, 14: 339–349.
5. **Danielson, L.A.; Conrad, K.P. (1995).** Acute blockade of nitric oxide synthase inhibits renal vasodilation and hyperfiltration during pregnancy in chronically instrumented conscious rats. *J Clin Invest.*; 96:482-90.
6. **Davidge, S.T.; Stranko, C.P.; Roberts, J.M. (1996).** Urine but not plasma nitric oxide metabolites are decreased in women with preeclampsia. *Am J Obstet Gynecol.*, 174: 1008–1013.
7. **Deen, W.M. (2004).** What determines glomerular capillary permeability? *J Clin Invest* 114: 1412–1414.
8. **Duley, L. 2009.** The global impact of pre-eclampsia and eclampsia. *J Clin Endocrinol.*; 33:130-7.
9. **Fekete, E.M.; Zorrilla EP. (2007).** Physiology, pharmacology, and therapeutic relevance of urocortins in mammals: Ancient CRF paralogs. *Frontiers in Neuroendocrinology*, 28: 1–27.
10. **Fergus, P. McCarthy, S.; Fred, A. ; John, K.; Edward, J.; Johns, C. and Sarah, K. (2011).** Evidence Implicating Peroxisome Proliferator-Activated Receptor- $\gamma$  in the Pathogenesis of Preeclampsia. *Hypertension*; 111:175-179.
11. **Florio, P.; Franchini, A.; Reis, F.M.; Pezzani, I.; Ottaviani, E.; Petraglia, F. (2000).** Human placenta, chorion, amnion and decidua express different variants of corticotropin-releasing factor receptor messenger RNA. *Placenta*, 21: 32–37.
12. **Florio, P. Severi, F.M.; Ciarmel, P.; Fior, G. Calonaci, G.; Merola, A. (2002).** Placental stress factors and maternal-fetal adaptive response: the corticotropin-releasing factor family. *Endocrine*, 19:91–102.
13. **Gratten, R.J.; Gandle, R.E.; Genbacev, O.; McCarthy, J.F.; Fisher, S.J.; McLaughlin, M.K. (2001).** Conditioned medium from hypoxic cytotrophoblasts alters arterial function. *Am J Obstet Gynecol.*, 184 (5): 984-990.
14. **Greenberg, S.G.; Baker, R.S.; Yang, D.; Clark, K.E. (1997).** Effects of continuous infusion of endothelin-1 in pregnant sheep. *Hypertension*, 30: 1585–1590.
15. **Hayam, I. G and Manar, E. S. (2011).** Comparative study of the potential therapeutic roles of urocortin-1 and selective endothelin type A receptor blockade in preeclamptic pregnant rats (Pathophysiological Study). *J Am Science*; 7 (11): 160-170.
16. **He, H.; Venema, V.J.; Gu, X.; et al. (1999).** Vascular endothelial growth factor signals endothelial cell production of nitric oxide and prostacyclin through flk-1/KDR activation of c-Src. *J Biol Chem.*; 274:25130-5.
17. **Hladunewich, M.A.; Derby, G.C.; Lafayette, R.A.; et al. (2006).** Effect of L-arginine therapy on the glomerular injury of preeclampsia: a randomized controlled trial. *Obstet Gynecol.*; 107:886-95.
18. **Holden, D.P.; Fickling, S.A.; Whitley, G.S.; Nussey**

- S.S. (1998). Plasma concentrations of asymmetric dimethylarginine, a natural inhibitor of nitric oxide synthase, in normal pregnancy and preeclampsia. *Am J Obstet Gynecol.*; 178:551-6.
19. Hsu, S.Y.; Hsueh, A.J. (2001). Human stresscopin and stresscopin-related peptide are selective ligands for the type 2 corticotropin-releasing hormone receptor. *Nat Med.*; 7: 605–611.
  20. Jeyabalan, A.; Novak, J.; Danielson, L.A.; et al. (2003). Essential role for vascular gelatinase activity in relaxin-induced renal vasodilation, hyperfiltration, and reduced myogenic reactivity of small arteries. *Circ Res.*; 93: 1249-57.
  21. Karumanchi, S.A.; Epstein, F.H.; Stillman IE (2005). Is dysfunction of podocyte foot processes necessary for the induction of proteinuria? *Am J Kidney Dis.*; 45: 436-458.
  22. Khan, S.; Ng, L.L. (2004). Urocortin in cardiovascular disease: pathophysiology and therapeutic potential. Drug Discovery today: *Therapeutic Strategies*, 1 (2): 63-168.
  23. Kitamura, K.; Kawamoto, M.; Ichiki, Y.; Nakamura, S.; Matsuo, H.; Eto, T. (1993). Adrenomedullin; a novel hypotensive peptide isolated from human pheochromocytoma. *Biochem Biophys Res Commun.*, 192: 553-560.
  24. Kulling, P.; Bakman, E. and Shakgius, A. (2004). Renal impairment after acute naproxen and sulindac overdoses. *J Toxicol Clin.*, 35 (3):122-125.
  25. McCarthy, A.L.; Woolfson, R.G.; Raju, S.K.; Poston, L. (1993). Abnormal endothelial cell function of resistance arteries from women with preeclampsia. *Am J Obstet Gynecol.*, 168: 1323–1330.
  26. McMahon, L.P.; Redman, C.W.; Firth JD. (1993). Expression of the three endothelin genes and plasma levels of endothelin in pre-eclamptic and normal gestations. *Clin Sci (Colch)*, 85: 417– 424.
  27. Mills, J.L.; Klebanoff, M.A.; Graubard, B.I.; Carey, J.C. and Berendes, H.W. (1991). Barrier contraceptive methods and preeclampsia. *J Am Med Assoc.*, 265: 70–73.
  28. Molnar, M.; Suto, T.; Toth, T.; Hertelendy, F. (1994). Prolonged blockade of nitric oxide synthesis in gravid rats produces sustained hypertension, proteinuria, thrombocytopenia and intrauterine growth retardation. *Am J Obstet Gynecol.*, 170: 1458–1466.
  29. Pettersson, A.; Hedner, T.; Milsom, I. (1998). Increased circulating concentrations of asymmetric dimethyl arginine (ADMA), an endogenous inhibitor of nitric oxide synthesis, in preeclampsia. *Acta Obstet Gynecol Scand.*; 77:808-13.
  30. R, Sukhumi, V.P.; Legate, M.; Karumanchi, S.A. (2006). Soluble Enderlin contributes to the pathogenesis of preeclampsia. *Nat Med.*; 12: 642–649.
  31. Rademaker, M.T. (2002). Beneficial hemodynamic, endocrine, and renal effects of urocortin in experimental heart failure: comparison with normal sheep. *J Am Coll Cardiol.*; 40, 1495–1505.
  32. Staff, A.C.; Berge, L.; Haugen, G.; et al. (2004). Dietary supplementation with L-arginine or placebo in women with preeclampsia. *Acta Obstet Gynecol Scand.*; 83:103-7.
  33. Suda, T.; Kageyama, K.; Sakihara, S.; Nigawara, T. (2004). Physiological roles of urocortins, human homologues of fish urotensin I, and their receptors. *Peptides*, 25: 1689–1701.
  34. Torricelli M, Ignacchiti E, Giovannelli A, Merola A, Scarpetti E, Calonaci G, Picciolini E, Florio P, Reis FM, Linton EA, Petraglia F. (2006). Maternal plasma corticotrophin-releasing factor and urocortin levels in post-term pregnancies. *Eur J Endocrinol.*, 154 (2):281-285.
  35. Trupin LS, Simon LP and Eskenazi B. (1996). Change in paternity: a risk factor for preeclampsia in multiparas. *Epidemiology*, 7: 240–244.
  36. Vaughan J, Donaldson C, Bittencourt J, Perrin MH, Lewis K, Sutton S, Chan R, Turnbull AV, Lovejoy D, Rivier C, Rivier J, Sawchenko PE, Vale W. (1995). Urocortin, a mammalian neuropeptide related to fish urotensin I and to corticotropin-releasing factor. *Nature*, 378: 287–292.
  37. Venkatesha S, Toporsian M, Lam C, Hanai JI, Mammoto T, Kim YM, Bdolah Y, Lim KH, Yuan HT, Libermann TA, Stillman IE, Roberts D, D'Amore PA, Epstein FH, Sellke FW, RomeroWang CH, LI ZY, Xiao GX. (2000). Role of nitric oxide in pathogenesis of pregnancy-induced hypertension. *Human Yi Ke Da Xue Xue Bae.*; 25 (4): 354-356.
  38. Young BA, Jonson RJ, Couser WG and Alpers CE. (2005). Cyclosporine A induced arteriopathy in a rat model of nephropathy. *Am J Med.*; 107 (5): 489-506.
  39. Zhu X, Wu S, Dahut WL, Parikh CR. (2007). Risks of proteinuria and hypertension with bevacizumab an antibody against vascular endothelial, growth factor: Systematic review and meta-analysis. *Am J Kidney Dis.*; 49: 186–193.

11/11/2011