

Controversial Role of Two Different Local Haemostatic Agents on Bone Healing

Ali Sawan¹ Yousry Elhawary² Mohamed Zaghlool Amer*³ and Mohamed Abdel Rahman⁴

¹ Professor Of Oral & Maxillofacial Surgery-, ² Associate professor Of Oral Biology, ³ Lecturer of Oral & Maxillofacial Surgery- Faculty of Dentistry-Mansoura University, ⁴ B.D.S 2002- Ministry of Health, Mansoura - Egypt

* norhanmohammed910@yahoo.com

Abstract: Controversial role of different local haemostatic agents on bone healing represented a major challenge for oral & maxillofacial surgeons. So, this study was directed to evaluate the effect of water soluble alkylene copolymer hemostat (ostene) versus bone wax on bone healing. **Material & Methods:** Forty five adult male rabbits weight 1kg were divided into three equal groups. A surgical bone defect was created into the anterior mandibular area. In 1st group the surgical defects were not subjected to any of local haemostatic agents. In 2nd group water soluble alkylene copolymer was applied within surgical defect and bone wax was applied within the 3rd group. Postoperatively, 3 animals were sacrificed from each group at 1, 2, 3, 6 and 12 weeks for histological assessment through H&E and Trichrome stain **Results:** Water soluble alkylene copolymer hemostat treated defects showed faster healing rate in 1st, 2nd weeks than defects left untreated. Ostene was disappeared from surgical defect at 1st week without presence of inflammatory cells in the defect. In 3rd group, the defects showed large empty vacuoles, representing bone wax remnants with inflammatory cells infiltration that interfere bone healing. **Conclusion:** Water soluble alkylene copolymer is biodegradable material that does not interfere with bone healing in contrast with bone wax which causes foreign body reaction, leading to interference of bone healing. [Journal of American Science. 2010;6(12):155-163]. (ISSN: 1545-1003).

Key words: Local Haemostatic Agents- Bone wax- Ostene

1. Introduction

Development of topical haemostatic agents has greatly improved surgeon's ability to achieve and maintain homeostasis, reduce patient blood loss, and decrease injury to the surrounding tissue that may occur with conventional haemostatic techniques. An ideal haemostatic agent has yet to be developed; however, with increased understanding and continued research on the coagulation mechanism, a number of new, commercially available products have been introduced to meet the criteria for the ideal agent.¹

Over the years, bone wax products with various ingredients were developed in several countries. Bone wax has no haemostatic quality, but its effect is to tamponade marrow spaces². Several reports have shown that bone wax residues are not resorbed and produce a foreign body giant cell reaction and inhibit bone reformation^{3,4}. Furthermore, *Von Arx et al.*, in 2006⁵ detected that due to its adverse effects on tissue healing, it should no longer be used for homeostasis control in surgery.

Other haemostatic agents such as gelatin foam, oxidized cellulose and microfibrillar collagen are absorbable, less prone to tissue reaction, do not interfere with bone healing and have platelet stimulating effects. Unlike bone wax, however, because of their physical properties, they are not ideal to seal the bleeding cancellous surfaces⁶.

Many efforts were made to obtain material with physical properties of bone wax to seal bleeding cancellous surface and also not interfere with bone healing⁷. A soft bone haemostatic wax (ostene) comprised of water-soluble alkylene oxide copolymers approved as local haemostatic material with this properties. This material comprises a sterile mixture of water-soluble alkylene oxide copolymers, derived from ethylene oxide and propylene oxide. These compounds are not metabolized, but eliminated from the body unchanged⁸.

Form this point of view, this study was carried out to evaluate the effect of water-soluble alkylene oxide copolymers (ostene) versus conventional bone wax on bone healing process.

2. Materials and Methods:

Normal adult forty five rabbits Weight 1 kg each were used in this study. They were divided into three equal groups each group contained fifteen animals. In 1st group, a cortical bony defect was done in the anterior mandibular area of rabbit. The edges of the defects in this group of animals were not coated with any of local haemostatic agents.

In 2nd group, a cortical bony defect was done in the anterior mandibular area of rabbit.

The edges of the defects in this group of animals were coated with a commercially available water soluble alkylene oxide copolymers (fig. 1) (Ostene, absorbable haemostatic material, cermed, inc company. U. S. A). Conventional bone wax (bone wax, non absorbable sealant, synergy sutures, a member of matrix health care) was applied within the created surgical defect in anterior mandibular area of rabbits in the 3rd group.

For each group, it was equally subdivided into five subgroups for histological assessment after 1, 2, 3, 6, and 12 weeks respectively.

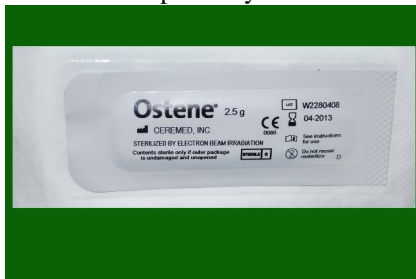

Fig. 1: Showing the sterile package contain ostene.

Anesthesia and surgical procedures:-

All the rabbits included in this study were anaesthetized by using diazepam (0.5mg/kg) (valpam, amoun Co, Cairo, Egypt) and ketamine hydrochloride (20mg/kg) injection (ketamine hydrochloride; ketalar, amoun Co, Cairo, Egypt). Mepecaine hydrochloride with 1: 20000 levonordefrin (Mepecaine hydrochloride with 1: 20000 levonordefrin; Alexandria Co, Egypt) as local anesthetic agent was injected in the proposed area of surgery to improve the homeostasis and to provide post operative analgesia. The sub mental area of the mandible was disinfected using sterile pellet soaked with povidone iodine (Betadin) (Betadin; Nile Co, Cairo, Egypt).

Extra oral submental incision was made, and then mucoperiosteal elevator was used for flap elevation. No.3 rose head surgical bur was used to induce bony cavity of the same size (involving the cortex and spongiosa) under efficient coolant using normal saline. To ensure standardization of the bony defect, the same size of the bur was used making its head contained in the bone defect, at the same speed of the micro motor device for all animals.

In the 1st group, the edges of the cortical bony defect were not coated by any material. In the 2nd group, Ostene was manipulated between the finger till reach the body temperature to be soft and easy for application then was applied to the edges of the cortical bony defect. In the 3rd group, bone wax

was applied to the edges of the cortical bony defect and the excess was removed.

The two edges of the incision were approximated and sutured by using 3/0 black silk. The incision line was painted with garamycin (Memphic Co, Cairo, Egypt) cream as local antibiotic.

Histological Evaluation:

Three rabbits within each subgroup were scarified at the different time intervals 1, 2, 3, 6, and 12 weeks respectively and the mandible was dissected out using a heavy scissor then fixed in 10% buffered formalin, decalcified and processed for paraffin sectioning. Sections were stained with hematoxylin for routine examination and trichrome stain for collagen.

3. Results

Histological observation using Hematoxylin and Eosin stain & Masson's Trichrome stains:-

In control group; the bony defect specimens contained granulation tissue, at the end of the first week (fig. 2). During second and third weeks, there were abundant less organized bony trabeculae with maturation of granulation tissue into connective tissue (fig. 3, 4), in addition; collagen bundles was seen running through the defect (fig. 5, 6). From three weeks to twelve weeks there were gradual increase in numbers, thickness coalescence (fig. 7, 8) and maturation of bony trabeculae (fig. 9).

In group II (ostene group) at the end of first week, the specimens of the bony defects revealed that more organized granulation tissue were formed with collagen bundles diffused through them, in comparison with the control group. Also there were new bony trabeculae formed (fig. 10, 11).

From two to six weeks, bony trabeculae were increased in number, thickness and organization when compared with control group. There was maturation of granulation tissue to connective tissue when compared with control group (fig. 12, 13, 14, 15, 16).

At the end of twelve weeks, the bone defects were completely filled with bony tissue which could not be distinguished from the surrounding normal bone (fig. 17, 18).

In group III (Bone wax), the histological specimens after one week revealed that the defect remained unchanged and there were some fibers at the base of defects, and the other part remained empty (fig.19). After two weeks, there were no bony trabeculae formation, but there were some inflammatory cells. By the time and after three

weeks, there were vacuoles between the fibers formed and more inflammatory cells (fig. 20). After six weeks, more bone destruction and inflammatory cells appeared (fig. 21, 22). After 12 weeks, the

histological specimens showed micro abscess formation, increased inflammatory cells and more bone destruction (fig. 23).

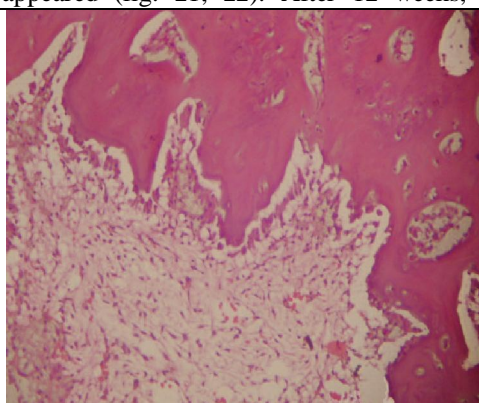


Fig. 2: Photomicrograph of bony defect in control group after one week from surgery showing, granulation tissue formation with newly formed blood vessels (H&E X100).

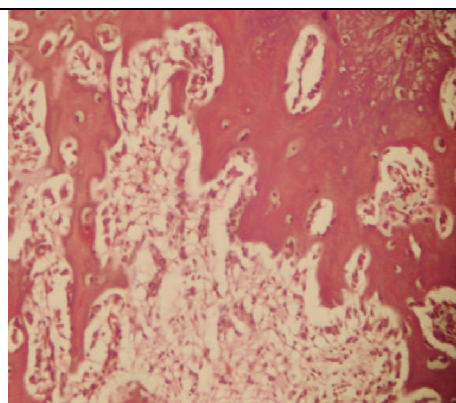


Fig. 3: Photomicrograph of bony defect in control group after two weeks showing, some bony trabeculae formation with granulation tissue appeared (H&E X100).

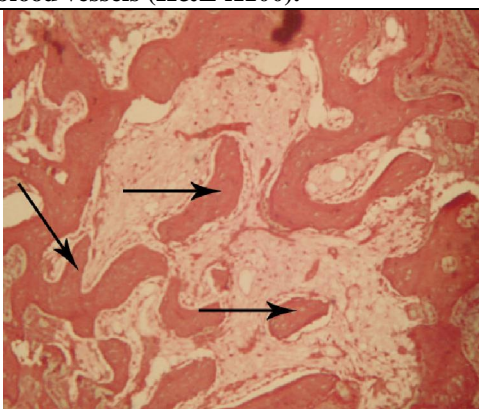


Fig. 4: Photomicrograph of bony defect in control group after three weeks showing, increased numbers of bony trabeculae (H&E X100).

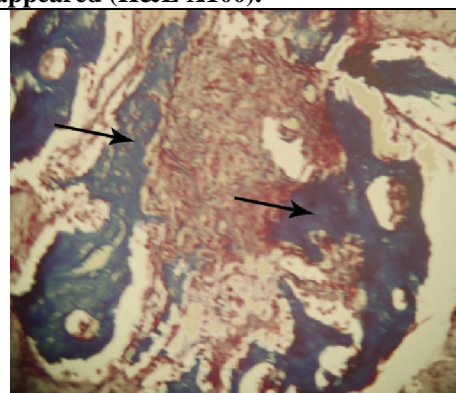


Fig. 5: Photomicrograph of bony defect in control group after two weeks showing, the collagen fibers of granulation tissue and newly formed bony trabeculae were seen (trichrom x 100).

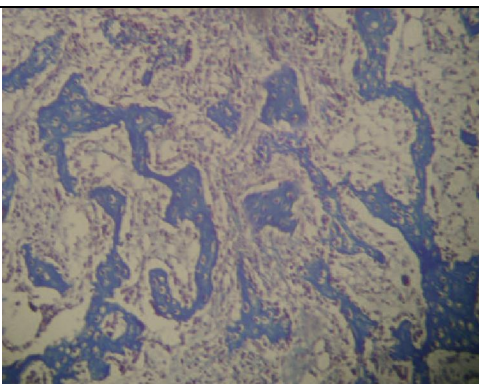


Fig. 6: Photomicrograph of bony defect in control group after three weeks showing, more bony trabeculae were formed (trichrom x 100).

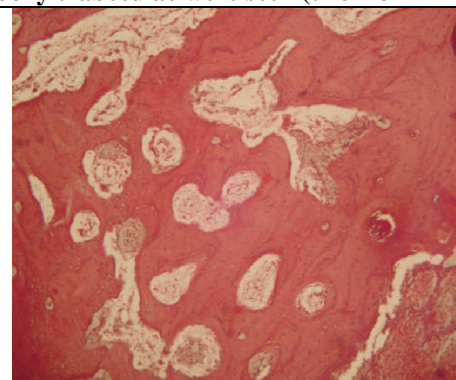
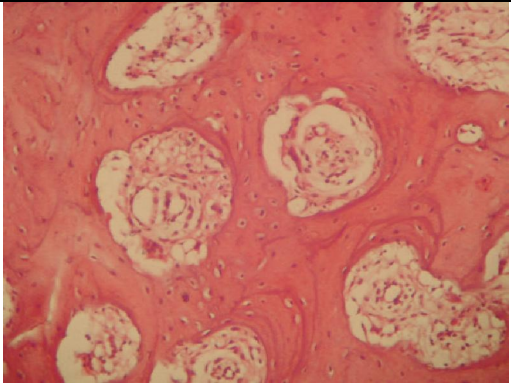
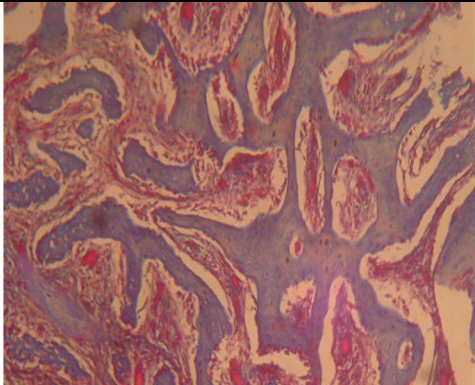
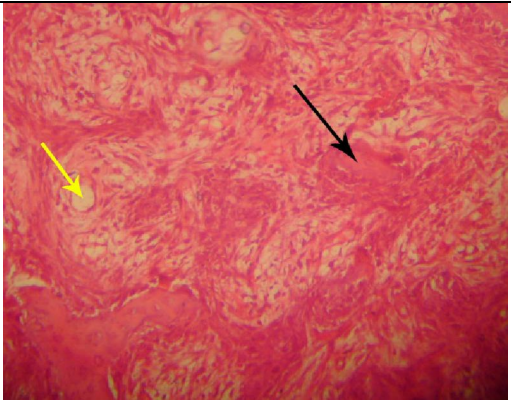
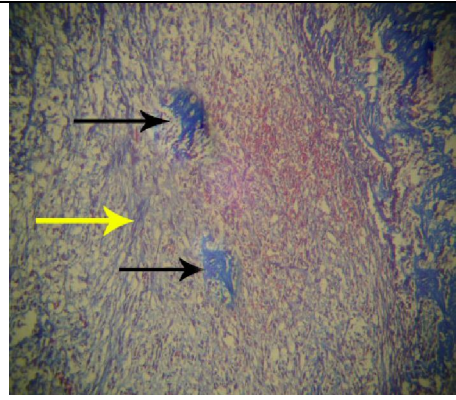
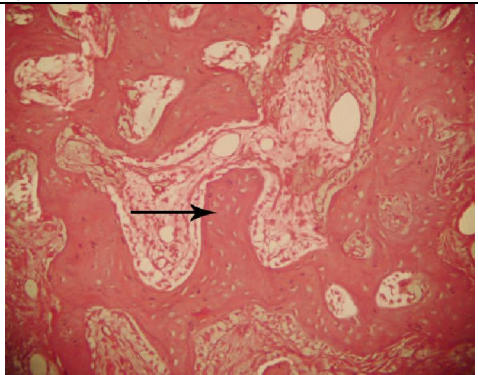
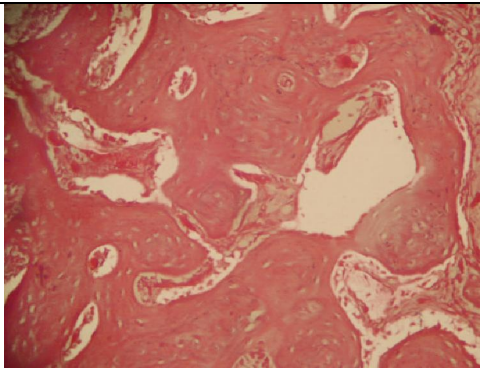


Fig. 7: Photomicrograph of bony defect in control group after six weeks showing, increased numbers and organization of bony trabeculae

| | |
|---|---|
|  <p>Fig. 8: Photomicrograph of bony defect in control group after twelve weeks showing well organized bony trabeculae with reversal lines (H&E X100).</p> | <p>(H&E X100).</p>  <p>Fig. 9: Photomicrograph of bony defect in group I (control) after six weeks showing increased numbers of bony trabeculae with some degree of maturity (trichrom x 100).</p> |
|  <p>Fig. 10: Photomicrograph of bony defect in group II (Ostene) after one week showing, granulation tissue formation with newly formed blood vessels and newly formed bony trabeculae (H&E X100).</p> |  <p>Fig. 11: Photomicrograph of bony defect in group II (Ostene) after one week showing, formation of collagen fibers with beginning of new bony trabeculae formation (trichrome x 100).</p> |
|  <p>Fig. 12: Photomicrograph of bony defect in group II (Ostene) after three weeks showing increased numbers and maturity of bony trabeculae (H&E X100).</p> |  <p>Fig. 13: Photomicrograph of bony defect in group II (ostene) after six weeks showing, more organization and maturity of bony trabeculae (H&E X100).</p> |

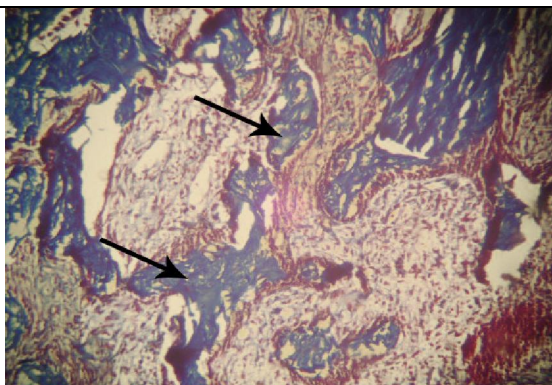


Fig. 14: Photomicrograph of bony defect in group II (Ostene) after two weeks showing, more collagen and bony trabeculae formation (trichrom x 100).

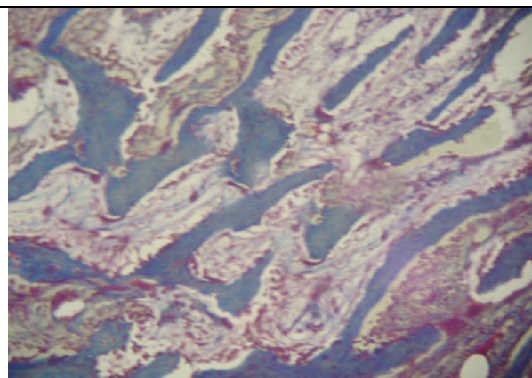


Fig. 15: Photomicrograph of bony defect in group II (Ostene) at three weeks showing increased numbers and maturity of bony trabeculae (trichrome x 100).

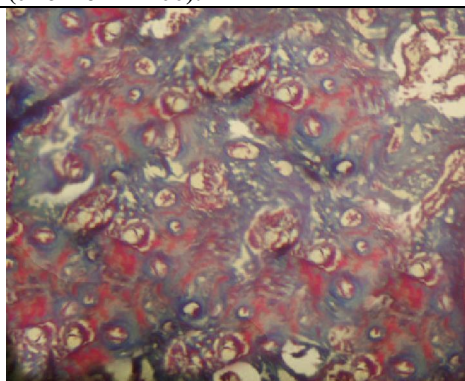


Fig. 16: Photomicrograph of bony defect in group II (ostene) after six weeks showing increased numbers of bony trabeculae with high degree of maturity (trichrome x 100).

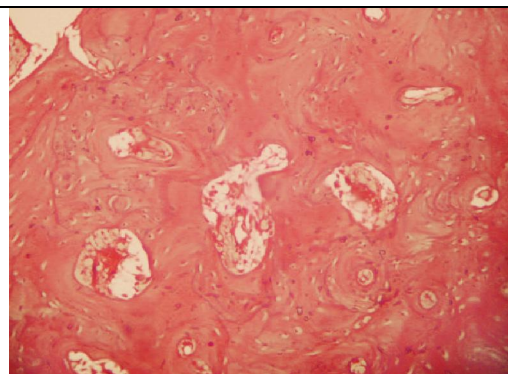


Fig. 17: Photomicrograph of bony defect in group II (ostene) after twelve weeks showing well matured bony trabeculae (H&E X100)

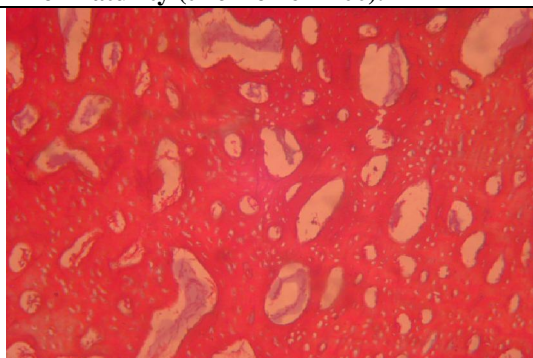


Fig. 18: Photomicrograph of bony defect in group II (Ostene) after 12 weeks showing, well organized bony trabeculae (trichrome x 100).

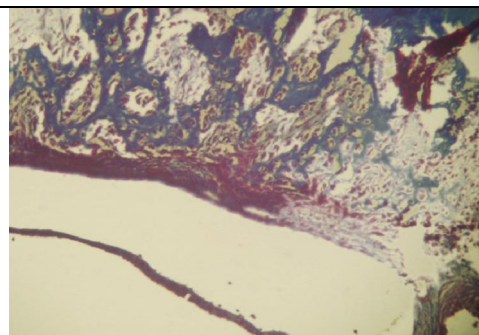


Fig.19: Photomicrograph of bony defect in group III (Bone wax) after one week showing, minimal fibers formed at the border of the cavity (trichrome x 100).

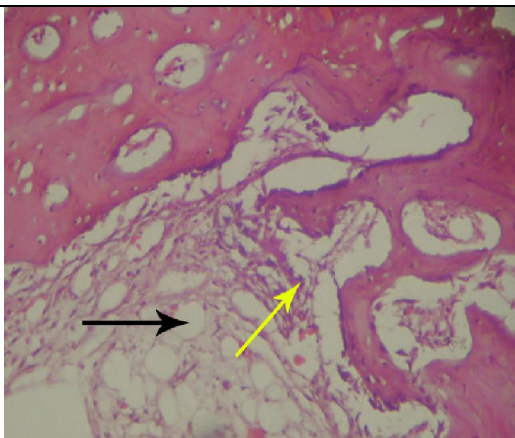


Fig. 20: Photomicrograph of bony defect in group III (Bone wax) after three weeks showing, no bone trabeculae formation, increased numbers of inflammatory cells and there were vacuoles between the fibers formed (H&E X100).

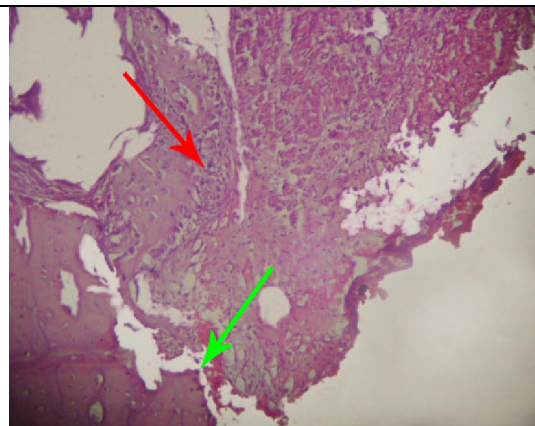


Fig. 21: Photomicrograph of bony defect in group III (Bone wax) after six weeks showing, more inflammatory cells and more destruction of bone (H&E X100).

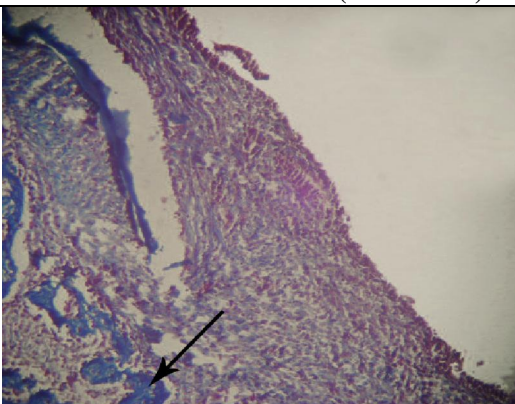


Fig. 22: Photomicrograph of bony defect in group III (Bone wax) after six weeks showing, no bony trabeculae formation with destruction of bone surrounding the defects (trichrom x 100).

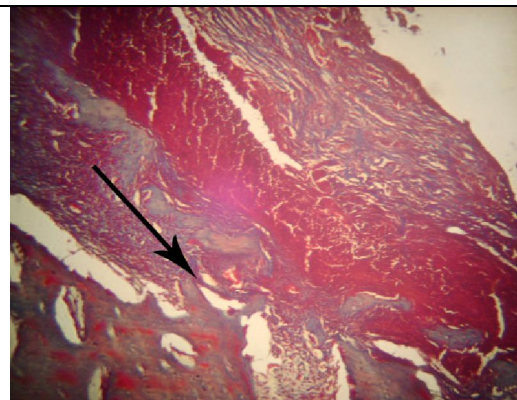


Fig. 23: Photomicrograph of bony defect in group III (Bone wax) after 12 weeks showing, micro abscesses were formed with destruction of bone surrounding the defects (trichrome x 100).

4. Discussion

In the last decade, the biotechnology has resulted in an explosive growth of topical haemostatic agents which are available to the modern surgeon⁹. One of the earliest topical haemostatic agents was cotton, in the form of gauze sponges. They are not absorbed by the body, and upon removal, the clot may be dislodged, leading to further bleeding¹⁰.

Passive topical haemostatic agents can absorb up to several times their own weight in fluid. The expansion of a passive topical haemostatic agent can result in complications such as pressing nerves in surrounding tissue against bone or hard tissue; an extreme case of this has resulted in spinal cord compression leading to paraplegia¹¹⁻¹³. Therefore, it

is recommended that minimum amount of haemostatic agent necessary to achieve homeostasis be used and as much of the agent as possible be removed after homeostasis is achieved when a passive topical haemostatic agent is used on or near bony or neural spaces. Also, passive topical haemostatic agents do not adhere strongly to wet tissue and have little impact on actively bleeding wounds¹⁴.

The physical presence of passive topical haemostatic agents can lead to confusion on subsequent diagnostic imaging because it may be difficult to distinguish between residual local topical homeostatic product and a tumor or abscess. Any residual product that may remain at the site also can

possibly potentiate a foreign-body reaction, chronic inflammation, or infection, which could promote granuloma formation and prevent optimal healing. Granulomas have been reported at a number of different sites after the use of passive topical haemostatic agents¹⁴.

Absorbable topical haemostatic agents have been developed and provide useful adjunctive therapy when conventional methods of homeostasis are ineffective or impractical. Wang *et al.*, in 2001¹⁵ first described the use of a 'Pluronic copolymer blend' as a biocompatible and absorbable haemostatic alternative agent to bone wax.

Clinically, no signs of infection or inflammation were detected at the surgical site during the time of operation in all groups. This indicated that surgical technique was carried out under aseptic condition and there was no affection of bone vitality. In 2nd group, the water soluble alkylene copolymer material has no inflammatory effect on bone or surrounding tissue throughout all time intervals of follow up. These results were in accordance with the histological result of Wellisz *et al.*, in 2008¹⁶ that made a study on rabbit's tibias and the created defects were treated with the polymer, and observed that all of the cortical defects in the animals healed without evidence of infection. This might be due to tolerability and tissue compatibility of the water soluble alkylene copolymer material (ostene).

In 3rd group, there were no signs of infection or inflammation at the surgical site at the time of operation, after first week, but after the second week there were signs of infection and inflammation which include swelling at the surgical site appeared as cortical expansion, and this swelling increase with time to reach maximum level after 12 weeks. This result indicated that there was chronic infection which increases with time due to foreign body reaction. These results were in agreement with Von Arx *et al.*, in 2006⁵ who conducted a study in the calvarium of six rabbits. Standardized bony defects were trephined, and different haemostatic agents were applied and compared with control defects. Bone wax was one of these materials. He observed that bone wax residues were not resorbed and produce a foreign body giant cell reaction.

Furthermore, Eser *et al.*, in 2007² reported that bone wax may cause a foreign body reaction and fibrosis and may increase the incidence of infection. Historically, several studies have described that, bone wax was noted to potentially cause chronic inflammation^{17,18}. Geary and Frantz, in 1950¹⁹ stated that, "in the series of control animals in which ordinary bone wax was used, no significant change in the implant was noted in the first 24 hours. At the 7th day, all showed an intense inflammatory reaction,

three having cysts containing sterile fluid and numerous particles of wax and a fourth presenting a single, large encapsulated mass of wax".

In 3rd group the histological sections after one week showed large empty space at the bottom of the defects, representing bone wax remnants (dissolved during the embedding procedure). These results are in agreement with Von Arx *et al.*, in 2006⁵ who revealed large empty vacuoles; represent bone wax, which was applied in bony cavity created in rabbit calvarium model. Furthermore, Sudmann *et al.*, in 2006²⁰ demonstrated microscopically that bone wax remnants seen in 17 of 18 sterna cadavers who prior to death had undergone surgery with median sternotomy and bone wax was used as haemostatic.

Histological sections of the control group and group II showed absence of inflammatory cells, no evidence of foreign body reaction was observed. These results were in accordance with Lee *et al.*, in 2009²¹ who reported that water soluble alkylene local haemostatic material did not cause local or systemic inflammation. This indicates the inert property of soluble alkylene copolymer material and its biocompatibility.

Histological examination of 2nd group after one week showed complete disappearance of the material at the application site, this indicate the biodegradable nature of material. These results are in agreement with Wang *et al.*, in 2001¹⁵ that used the same material, and had proved its effectiveness in allowing homeostasis at the bleeding sites of bone and can be absorbed within 24 to 48 hours.

During a comparison of bone healing between 1st versus 2nd group, bony trabeculae were formed in 2nd group and no bony trabeculae were evident in 1st group after first week. After second and third weeks, bony trabeculae in 2nd group were more in numbers, size, and maturation than 1st group. This revealed that healing started faster in 2nd group, at first, second, and third weeks. However, there was no remarkable difference in number, distribution, maturation, and coalescence of the bony trabeculae in both groups after six and twelve weeks. This indicated that bone healing levels occurred during later periods were nearly the same.

These results may be attributed to the nature of water soluble alkylene copolymer material which dissolved rapidly and eliminated from the body within days after surgery.

The previous results were in agreement with the observation of Wellisz *et al.*, in 2008¹⁶ that made his study on the tibia of rabbits and revealed that the use of the water-soluble polymer did not affect bone healing compared with controls. All of the cortical defects in the animals without radiographic evidence of infection had histological evidence of bone healing. Lee *et al.*, in

2009²¹ showed that Ostene was effective in achieving bone homeostasis and absorbable in the body of rabbits. It did not inhibit new bone formation at the cut surface of the bone and did not cause local or systemic inflammation.

Furthermore, Magyar *et al.*, in 2008²² made a circular non critical-sized defect in the calvariae of rats. Alkylene oxide copolymer material was applied. He revealed that healing after 3 weeks was faster in defects with alkylene oxide copolymer material than defects without any material, and healing rate in the two groups were the same after six and twelve weeks from surgery.

During a comparison of bone healing between 3rd group versus 1st group, there were retardation and inhibition of bone healing. This demonstrated by absence of collagen fibers formation or bony trabeculae. This indicated that, bone wax inhibit osteogenesis. This result in agreement with number of studies, which reported that bone wax act as a mechanical barrier to bone regeneration^{23,24}.

In 3rd group the histological findings showed inflammatory reaction, abscess formation, and destruction of bone at the border of cavity. Such findings might be attributed to the bone wax which remained in the defect, not absorbed, and acting as nidus for infection. The body reacted with these remnants as foreign body, it might lead to stimulation of chronic inflammatory cells and foreign-body reaction occurred. It might reduce bacterial clearance in cancellous bone and increase the liability of infection by decreasing the amount of bacteria needed to produce *Staphylococcus aureus* osteomyelitis.

Eser *et al.*, in 2007² demonstrated the presence of inflammatory granulation tissue as a reaction due to the presence of bone wax remnants, which was used as a local hemostat. Bone wax was seen within granulation tissue. Histopathological examination revealed infiltration of inflammatory cells and a foreign body granuloma in the connective tissue. The inflammatory cells were composed of lymphocytes, macrophages, and foreign body-type multinucleated giant cells.

To the best of our knowledge and as a result of the findings of this study, we believe that prevention of bone wax application as a local haemostatic agent is mandatory with replacement of it by such recent local haemostatic agent.

5. Conclusion:

Water soluble alkylene copolymer is biodegradable material that does not interfere with bone healing in contrast with bone wax which causes foreign body reaction, leading to interference of bone healing.

Corresponding author

Mohamed Zaghlool Amer

Oral & Maxillofacial surgery

Faculty of Dentistry- Mansoura University, Mansour, Egypt.

norhanmohammed910@yahoo.com

6. References:

1. Jay B. Erne and Fred Anthony Mann: Surgical Hemostasis. Small Animal/Exotics. 2003; 25(10).
2. Eser O, Cosar M, Aslan A, Sahin O: Bone Wax as a Cause of Foreign Body Reaction after Lumbar Disc Surgery: A Case Report. *Adv Ther.* 2007 May-Jun;24(3):594-7.
3. Solheim E, Pinholt EM, Bang G, Sudmann E: Effect of local hemostatics on bone induction in rats: a comparative study of bone wax, fibrin-collagen paste, and bioerodible polyorthoester with and without gentamicin. *J Biomed Mater Res.* 1992 Jun;26(6):791-800..
4. Allison RT. Foreign body reactions and an associated histological artefact due to bone wax. *Br J Biomed Sci.* 1994 Mar;51(1):14-7.
5. Von Arx T, Jensen SS, Hänni S, Schenk RK.: Haemostatic agents used in periradicular surgery: an experimental study of their efficacy and tissue reactions. *Int Endod J.* 2006 Oct;39(10):800-8.
6. Lavigne M, Boddu Siva Rama KR, Doyon J, Vendittoli PA.: Bone-wax granuloma after femoral neck osteoplasty. *Can J Surg.* 2008 Jun;51(3):E58-60.
7. Peng T: Biomaterials for Hemorrhage Control. *Trends Biomater. Artif. Organs.* 2010; 24(1):27-68
8. Grindel JM, Jaworski T, Emanuele RM, Culbreth P.: Pharmacokinetics of a novel surface-active agent, purified poloxamer 188, in rat, rabbit, dog and man. *Biopharm Drug Dispos.* 2002 Apr;23(3):87-103.
9. Achneck HE, Sileshi B, Jamiolkowski RM, Albala DM, Shapiro ML, Lawson JH. A Comprehensive Review of Topical Hemostatic Agents Efficacy and Recommendations for Use. *Ann Surg.* 2010 Feb;251(2):217-28.
10. -Bochicchio G, Dunne J, Bochicchio K, Scalea T. The combination of platelet-enriched autologous plasma with bovine collagen and thrombin decreases the need for multiple blood transfusions in trauma patients with retroperitoneal bleeding. *J Trauma.* 2004; 56(1):76-79.
11. Sabel M, Stummer W.: The use of local agents: Surgicel and Surgifoam. *Eur Spine J.* 2004 Oct;13 Suppl 1:S97-101. Epub 2004 May 15
12. Banerjee T, Goldschmidt K. "Surgiceloma" manifested as cauda equina syndrome. *South Med J.* 1998; 91(5):481-483.

13. Brodbelt AR, Miles JB, Foy PM, Broome JC. Intraspinal oxidized cellulose (Surgicel) causing delayed paraplegia after thoracotomy—a report of three cases. *Ann R Coll Surg Engl.* 2002; 84(2):97-99.
14. Tomizawa Y.: Clinical benefits and risk analysis of topical hemostats: a review. *J Artif Organs.* 2005;8(3):137-42.
15. Wang MY, Armstrong JK, Fisher TC, Meiselman HJ, McComb GJ, Levy ML: A new, pluronic-based, bone hemostatic agent that does not impair osteogenesis. *Neurosurgery.* 2001 Oct;49(4):962-7; discussion 968.
16. Wellisz T, An YH, Wen X, Kang Q, Hill CM, Armstrong JK: Infection rates and healing using bone wax and a soluble polymer material. *Clin Orthop Relat Res.* 2008 Feb;466(2):481-6. Epub 2008 Jan 10.
17. Howard TC, Kelley RR: The effect of bone wax on the healing of experimental rat tibial lesions. *Clin Orthop Relat Res.* 1969; 63: 226–232.
18. Brightmore TG, Hayes P, Humble J, Morgan AD. Haemostasis and healing following median sternotomy. *Langenbecks Arch Chir.* 1975;Suppl:39-41.
19. Geary JR, Frantz VK.: A new absorbable hemostatic bone wax; preliminary report. *J Neurosurg.* 1950 Sep;7(5):383-4.
20. Sudmann B, Bang G, Sudmann E.: Histologically verified bone wax (beeswax) granuloma after median sternotomy in 17 of 18 autopsy cases. *Pathology.* 2006 Apr;38(2):138-41.
21. Lee TC, Chang NK, Su FW, Yang YL, Su TM, Lin YJ, Lin WC, Huang HY.: Systemic and local reactions of a water-soluble copolymer bone on a bony defect of rabbit model. *Surg Neurol.* 2009 Dec;72 Suppl 2:S75-9; discussion S79. Epub 2009 Aug 7.
22. Magyar CE, Aghaloo TL, Atti E, Tetradis S.: Ostene, a new alkylene oxide copolymer bone haemostatic material, does not inhibit bone healing. *Neurosurgery.* 2008 Oct;63(4 Suppl 2):373-8; discussion 378.
23. Rockwood C, Perkins JC, Roberts L, Dixon D: Reaction of bone wax on bone and muscle. *J Bone Joint Surg.* 1968; 50:837–838.
24. -Sorrenti SJ, Cumming WJ, Miller D.: Reaction of the human tibia to bone wax. *Clin Orthop Relat Res.* 1984 Jan-Feb;(182):293-6.

6/22/2010